



pISSN 2586-3290 · eISSN 2586-3533  
Arch Hand Microsurg 2024;29(2):90-95  
<https://doi.org/10.12790/ahm.24.0014>

Received: March 30, 2024

Revised: April 19, 2024

Accepted: April 19, 2024

### Corresponding author:

Sangho Oh

Department of Plastic and Reconstructive Surgery, Saeson Hospital, 858 Gyeryong-ro, Jung-gu, Daejeon 34908, Korea

Tel: +82-42-535-1900

Fax: +82-42-535-1902

E-mail: [fwmesser@hanmail.net](mailto:fwmesser@hanmail.net)

ORCID:

<https://orcid.org/0000-0002-8739-908X>

# The Zitelli bilobed flap for soft tissue coverage after muroid cyst resection: a retrospective cohort study

Sangho Oh<sup>1</sup>, Jaein Chung<sup>1</sup>, Daegu Son<sup>2</sup>

<sup>1</sup>Department of Plastic and Reconstructive Surgery, Saeson Hospital, Daejeon, Korea

<sup>2</sup>Department of Plastic and Reconstructive Surgery, Keimyung University Dongsan Hospital, Daegu, Korea

**Purpose:** Digital muroid cysts are frequently found at the distal interphalangeal (DIP) joint in patients with degenerative osteoarthritis. In complicated cases, surgical treatment with muroid cyst resection is considered, and soft tissue is covered with one of various local flap techniques. Among these, bilobed flaps are reliable and aesthetically favorable, with primary healing of the donor site. In this study, we investigated a case series of bilobed flaps for digital muroid cysts.

**Methods:** We retrospectively reviewed our electronic medical records and found 26 digital muroid cysts treated with bilobed flaps at our facility between July 2022 and February 2024. We extracted data from the records of these patients on sex; age; time to surgery; clinical findings including nail ridging, the presence of osteophytes, cyst size and location, and additional procedures (arthrodesis); and follow-up data including the occurrence of complications, such as delayed wound healing, infection, stiffness, and recurrence.

**Results:** Among the 26 patients in our sample, 19 were female and seven were male. The average age was 62.2 years, and the average time to surgery was 10.8 months. Preoperatively, the average cyst measured 6.9×8.3 mm. Nail ridging was found in 19 patients (73.1%) and osteophytes in 22 patients (84.6%). The most commonly affected digit was the middle finger, which accounted for 10 cases (38.5%). All the flaps totally survived, without major complications.

**Conclusion:** Based on our series, a bilobed flap for soft tissue coverage after muroid cyst excision can achieve high-quality surgical results.

**Keywords:** Flap, Ganglion cysts, Osteoarthritis, Myxoid cyst

## Introduction

Digital muroid cysts are frequently found at the distal interphalangeal (DIP) joint in patients with degenerative osteoarthritis [1-3]. These cysts were first reported in 1883 as synovial lesions of the skin [3]. Since then, muroid cysts have been named by multiple nomenclatures such as synovial cysts, myxoid cysts, and ganglions due to their unknown pathophysiology and cause [2,3]. Prevention of muroid cysts was important; however, when muroid cysts are large, severe, or painful, or they are disrupted and accompanied by skin ulceration, surgical treatment is required. In particular, skin ulceration with a disrupted muroid cyst or thinned skin due to a long-standing cyst needs to resect the entire skin envelope and perform flap coverage. Even though appropriate flap coverage was performed, the recurrence of muroid cyst occurred by incomplete excision of the cyst stalk and progression of degenerative arthritic changes. Therefore, appropriate operative and perioperative management was essential for the resolution of muroid cysts

© 2024 by Korean Society for Surgery of the Hand, Korean Society for Microsurgery, and Korean Society for Surgery of the Peripheral Nerve.

© This is an open-access article distributed under the terms of the Creative Commons Attribution Non-Commercial License (<http://creativecommons.org/licenses/by-nc/4.0/>), which permits unrestricted non-commercial use, distribution, and reproduction in any medium, provided the original work is properly cited.

[1,3,4].

Multiple local flap choices can be used for the defects above the DIP joint, including a dorsal Hueston flap, a dorsal advancement flap, and a rotation flap [3,5]. Bilobed flaps were first proposed by Esser in 1918 and were first used in 1953 for nasal labial reconstruction [1]. Their first application to defects of digital soft tissue was by Young and Campbell [2]. Bilobed flaps are now considered a reliable choice for digital soft tissue defects, with primary healing of the donor site [2]. In this article, we describe our retrospective evaluation of surgical outcomes following bilobed flap after digital mucoid cyst resection.

## Methods

**Ethics statement:** This study was conducted by the Declaration of Helsinki and was approved by the Institutional Review Board of the Korea National Institute for Bioethics Policy (KoNIBP). Patients provided informed consent for the publication of the clinical photographs included in this article.

Between July 2022 and February 2024, 26 bilobed flap surgeries for DIP joint soft tissue defect after mucoid cyst excision were performed at our institute and included in this study. At each patient's first visit to our clinic, we recorded their demographic data (sex, age, time to surgery), and clinical findings (including cyst size and location, the presence of nail ridging, and signs of infection) were recorded. A plain X-ray was conducted to determine whether osteophytes had developed and identify any arthritic changes in the DIP joint. The diagnosis was made based on the combined clinical and radiographic findings. Surgical treatment was considered when the cyst is painful, aesthetically problematic, disruptive and ulcerous, or recurrent. Postoperative follow-up is routinely and regularly conducted at our institute. At each outpatient clinic follow-up, we assess wound status, wound healing time, and other complications.

### 1. Surgical techniques

The procedure was performed on all patients by a single plastic surgeon (S Oh). The patients were under brachial plexus block in the supine position. The cyst excision was performed first using a circular shape. The defect size was measured, and the geometric modified bilobed flap was designed by Zitelli and reported by Jiménez et al. [4]. Two lobes are created for soft tissue coverage. The first lobe has a similar diameter to the circular defect. The second lobe has a slightly smaller diameter than the

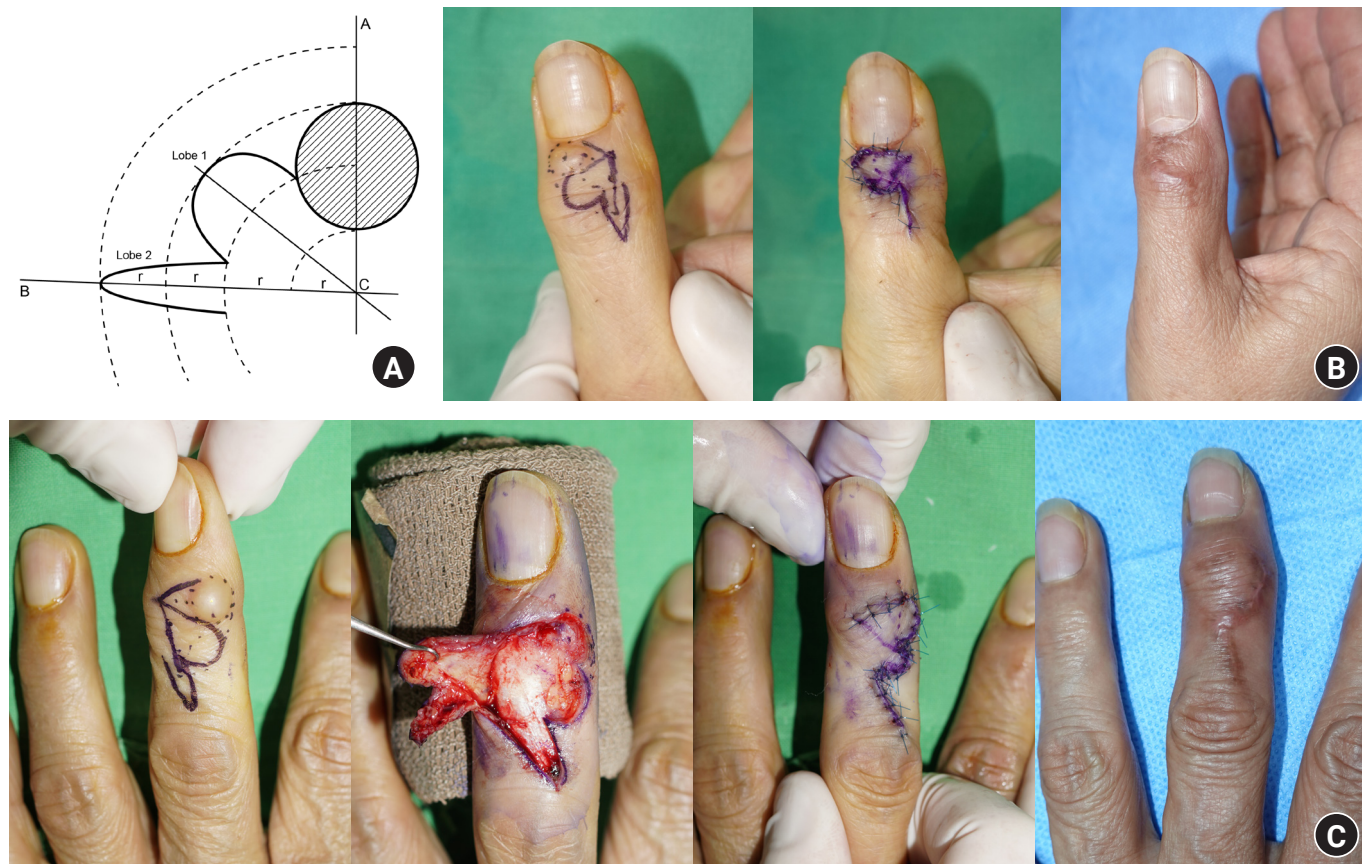
first and is used to cover the defect of the first lobe. The second lobe has a narrow shape for easier to suture primarily. In addition, two lobes were positioned with considering the postoperative scar contracture. With Zitelli's design, a postoperative straight scar was from the second lobe, the second lobe should not be positioned vertically with DIP and proximal interphalangeal (PIP) joint crease to avoid postoperative scar contracture. The angle between the axis of the soft tissue defect and the second lobe is about 90°. This allows stable flap inseting and easier skin closure while avoiding secondary healing at the donor site (Fig. 1).

Additional procedures were considered during surgery in specific situations. If there was a definite osteophyte in the DIP joint and a connection between the cyst stalk and the joint, an osteophyte resection with joint debridement was performed (Fig. 2). Joint debridement includes a synovectomy and resection of inflammatory and unhealthy tissues around the DIP joint. If there were severe arthritic changes to the DIP joint, DIP joint arthrodesis was considered (Fig. 3). All patients underwent joint debridement, and patients with osteophyte on the DIP joint were performed osteophyte resection additionally. According to our opinion, mucinous deposition was caused by degenerative changes in the joint, these degenerative changes were related to the presence of an osteophyte and DIP joint synovitis. Therefore, we always effort to perform osteophyte resection if necessary and joint debridement.

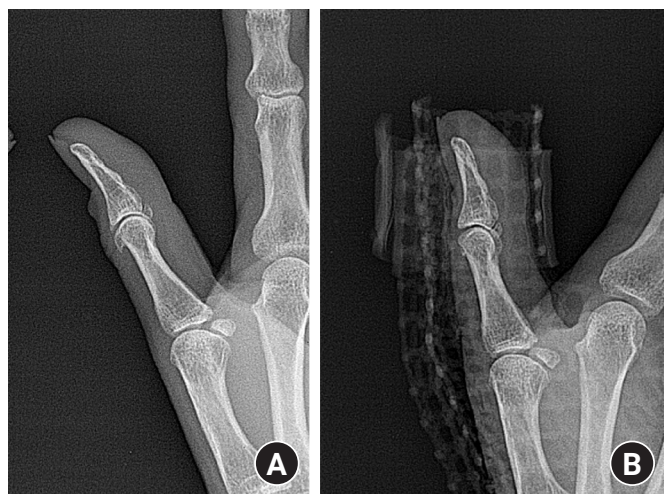## Results

Table 1 shows the patient demographics and follow-up data. There were 19 female and seven male patients in our cohort. The average age was 62.2 years (range, 45–78 years). This roughly corresponds to the demographics reported in previous studies [1,4,7-9]. Eight mucoid cysts were located at the interphalangeal joint of the thumb, 10 were located at the DIP joint of the middle finger, six were located at the DIP joint of the ring finger, and two were located at the DIP joint of the little finger. The average time to surgery was 10.8 months (range, 1–60 months). The average cyst size was 6.9 × 8.3 mm (range, 0.4–1.0 × 0.5–1.3 mm). On their preoperative X-ray, 22 patients (84.6%) had a definite osteophyte of the DIP joint. Nail ridging was found in 19 patients (73.1%). It occurred only when the cyst was located at the nail fold; if it was located on the radial or ulnar side of the DIP joint (away from the nail root), there was no nail ridging.

All of the flaps survived without major complications. In one patient, there was delayed wound healing due to partial flap ne-



**Fig. 1.** (A) The design of a geometric bilobed flap for soft tissue defects. Axis A passes through the center of the defect, and axis B passes through the center of the second lobe. The A–B angle is usually  $80^{\circ}$  to  $90^{\circ}$  in digital bilobed flaps. (B) A bilobed flap in a 67-year-old woman after digital mucoïd cyst resection. The image shows the preoperative flap design (left), an immediate postoperative photograph (center), and clinical photographs taken 6 months postoperatively (right). (C) A bilobed flap in a 55-year-old woman after digital mucoïd cyst resection. The image shows the preoperative flap design, intraoperative, immediate postoperative photographs, and 6-month postoperative clinical photographs.

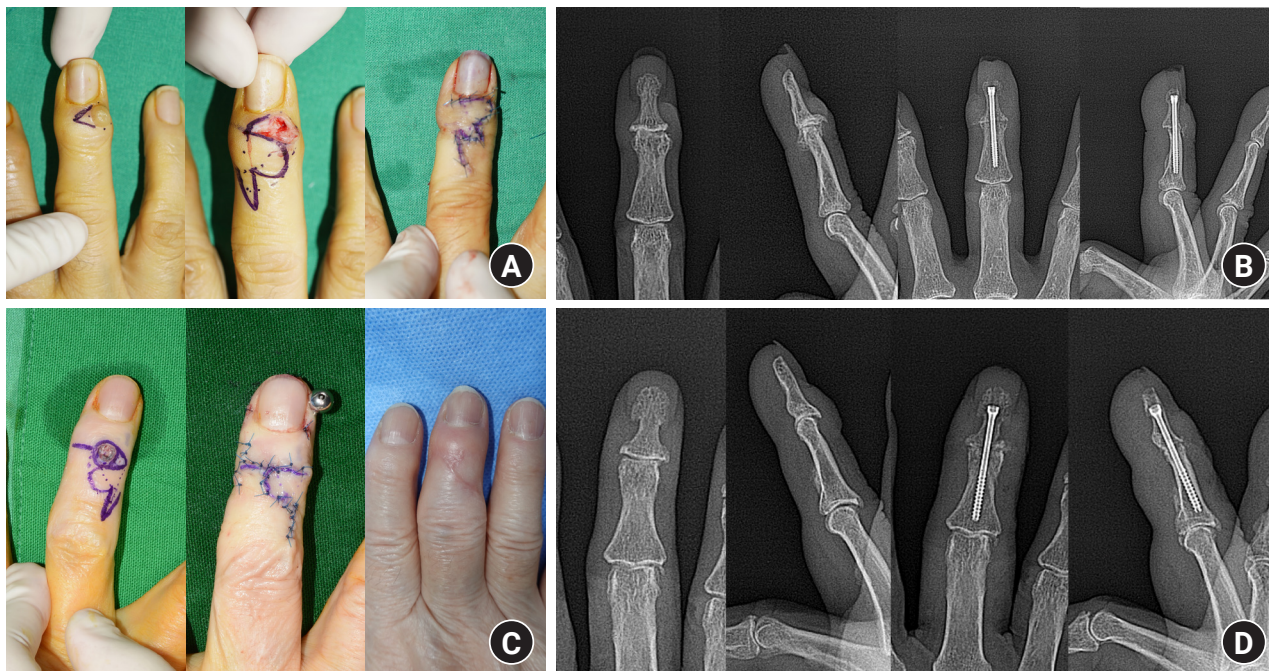


**Fig. 2.** (A) In this patient, a preoperative X-ray examination showed a prominent distal phalangeal osteophyte. (B) After osteophyte resection, flattening of the distal phalanx was observed.

crosis. In this patient, the bilobed flap for mucoïd cyst resection and DIP joint arthrodesis for severe degenerative osteoarthritis were performed. It may have been caused by flap damage during the osteotomy of the distal phalanx base and middle phalanx head using oscillating saw. During the follow-up period in our cohort, there were no recurrences of the cyst.

## Discussion

Digital mucoïd cysts are benign ganglionic or synovial lesions of the interphalangeal joint [5,6]. Treatment methods include aspiration of the cyst or surgical excision [1,2,4]. Although the recurrence rate following aspiration is approximately 60%, nonsurgical treatment is preferable if the cyst is asymptomatic [1]. However, if the cyst was symptomatic or recurrent, surgical treatment was considered [4]. Standardized indications for surgical treat-



**Fig. 3.** A bilobed flap with distal interphalangeal (DIP) joint arthrodesis in a 71-year-old woman after digital mucoid cyst resection. (A) Preoperative and immediate postoperative clinical photographs. (B) Severe DIP joint degenerative osteoarthritis was seen, and DIP joint arthrodesis with intramedullary screw fixation was performed. A bilobed flap with DIP joint arthrodesis in a 78-year-old woman after digital mucoid cyst resection. (C) Preoperative, immediate postoperative, and 6-month postoperative follow-up clinical photos. (D) Severe DIP joint degenerative osteoarthritis was seen, and DIP joint arthrodesis with intramedullary screw fixation.

**Table 1.** Clinical, demographic, and follow-up data of the mucoid cyst patients in this study

Variable	Data
Demographic data	
No. of patients	26
Sex, male:female	7:19
Age (yr)	62.2 (45-78)
Time to surgery (mo)	10.8 (1-60)
Clinical finding	
Nail ridging	19 (73.1)
Osteophytes	22 (84.6)
Cyst size (mm)	6.9 (0.4-1) × 8.3 (0.5-1.3)
Location	
Thumb	8 (30.8)
Index finger	0 (0)
Middle finger	10 (38.5)
Ring finger	6 (23.1)
Little finger	2 (7.7)
Additional arthrodesis	6 (23.1)
Follow-up data	
Delayed wound healing	1 (3.8)
Infection	1 (3.8)
Stiffness	3 (11.5)
Recurrence	0 (0)

Values are presented as number only, number (%), or median (range).

ment have not yet been fully established, but Rizzo and Beckenbaugh [1] have suggested that the failure of previous nonsurgical treatment or the presence of nail ridging was considered a surgical indication. Nail ridging indicated a more mature cyst with an established stalk [4,6]. The indications for surgical treatment used in our institute are somewhat broader and include painful cysts, aesthetic issues, and recurrence despite conservative management such as aspiration or steroid injection.

The most frequently affected fingers in our patients were the thumb and middle finger, which differed from previous reports, in which the index finger was the most affected. In addition, nail ridging was seen in about 73% ( $n = 19$ ), which was a higher rate than has previously been reported. This is likely because our sample included only patients who received surgery [8-10]. The average time to surgery was 10.8 months. Almost all patients do not seek treatment for mucoid cysts for a long time or continue the repetitive conservative treatment for a long time before they visit our clinic. DIP joint osteophytes were seen in the preoperative X-rays of 84.6% ( $n = 22$ ) of our patients. Rizzo and Beckenbaugh [1] reported a slightly higher rate of 91%. Although the pathophysiology of mucoid cysts was not fully established, the mucinous formation was related to degenerative changes in previous studies [1-3]. Our authors also agreed that DIP joint mu-

cinous formation was related to arthritic changes with osteophyte resection or severe synovitis in the DIP joint. Therefore, we performed osteophyte resection if possible or joint debridement in all cases because mucoid cysts are known to be related to degenerative changes in the DIP joint, it was related to the presence of the osteophyte or DIP joint synovitis [4].

During the follow-up period, we monitored patients for postoperative complications, including recurrence of the mucoid cyst, joint stiffness, infection, and delayed wound healing. We defined joint stiffness defined as a decrease in the range of motion of the affected joint greater than 50%. Stiffness occurred in 11% of our patients, while Rizzo and Beckenbaugh [1] reported a postoperative stiffness rate of 8%. Postoperative stiffness may be related to surgical scarring and arthritic changes after osteophyte resection and bilobed flap. With the bilobed flap coverage after mucoid cyst resection, a scar crossing the DIP joint occurred inevitably in almost all patients. As our surgical technique, the point that the second lobe design should not be positioned in a vertical direction with DIP and PIP joint and tension-free and redundant flap coverage with bilobed flap can minimize postoperative stiffness. In addition, patients with DIP joint stiffness in our series did not complain about the limitations in range of motion; they used their digits without any discomfort during daily life.

A previous report found a recurrence rate after cyst excision and osteophyte resection of 0% to 3.5% [4]; there was no recurrence in our patients. Delayed wound healing and infection occurred in 3.8% (n = 1) of our cases, which was a lower rate than seen in previous reports [1,4].

After the introduction of first bilobed flap by Esser in 1918, Zimany [10] proposed a modified (self-closing shape) design in 1953. In 1989, Zitelli proposed a further modification, known as the geometric bilobed design, which design used in this study (Fig. 1) [4]. Zitelli's design was initially proposed for use in nasal surgery, for which the angle between the defect axis and the second lobe axis is 90° to 100° [4]. However, in the fingers, there is less relaxation of the skin and soft tissue than in the nasal area, so we proposed decreasing this angle to 80° to 90° for the digital mucoid cyst surgeries performed in our cohort studied. Other local flap techniques for mucoid cysts include dorsal Heuston flaps, dorsal advancement flaps, and the rotation flaps developed by Kleinert et al. [11]. The advantages of bilobed flaps for these cysts include more aesthetically pleasing results than can be obtained with the aforementioned flap types, primary healing of the donor site, reproducibility, and easy-to-flap elevation. The bilobed flap can achieve total coverage using soft tissue near the defect, reducing the dissection area, with no need to cross

the PIP joint. This modified bilobed flap design for soft tissue coverage of the defect after mucoid cyst excision produces high-quality surgical results.

## Conclusion

A large number of patients with osteoarthritis in the DIP joint develop mucoid cysts, and complicated mucoid cysts require surgical resection. Soft tissue coverage with a local flap is required after the excision of a mucoid cyst of the DIP joint. Based on our case series, the modified Zitelli bilobed flap is considered to be a favorable option for coverage of soft tissue defects after mucoid cyst excision, which yields favorable aesthetic and functional outcomes.

## ORCID

Sangho Oh, <https://orcid.org/0000-0002-8739-908X>

Jaemin Chung, <https://orcid.org/0000-0002-1571-8491>

Daegu Son, <https://orcid.org/0000-0002-4653-1048>

## Conflicts of interest

The authors have nothing to disclose.

## Funding

None.

## References

1. Rizzo M, Beckenbaugh RD. Treatment of mucous cysts of the fingers: review of 134 cases with minimum 2-year follow-up evaluation. *J Hand Surg Am.* 2003;28:519-24.
2. Young KA, Campbell AC. The bilobed flap in treatment of mucous cysts of the distal interphalangeal joint. *J Hand Surg Br.* 1999;24:238-40.
3. Blume PA, Moore JC, Novicki DC. Digital mucoid cyst excision by using the bilobed flap technique and arthroplastic resection. *J Foot Ankle Surg.* 2005;44:44-8.
4. Jiménez I, Delgado PJ, Kaempf de Oliveira R. The Zitelli bilobed flap on skin coverage after mucous cyst excision: a retrospective cohort of 33 cases. *J Hand Surg Am.* 2017;42:506-10.
5. Kim EJ, Huh JW, Park HJ. Digital mucous cyst: a clinical-surgical study. *Ann Dermatol.* 2017;29:69-73.
6. Li K, Barankin B. Digital mucous cysts. *J Cutan Med Surg.*

- 2010;14:199-206.
7. Fritz GR, Stern PJ, Dickey M. Complications following mucous cyst excision. *J Hand Surg Br.* 1997;22:222-5.
  8. Kasdan ML, Stallings SP, Leis VM, Wolens D. Outcome of surgically treated mucous cysts of the hand. *J Hand Surg Am.* 1994;19:504-7.
  9. Dodge LD, Brown RL, Niebauer JJ, McCarroll HR Jr. The treatment of mucous cysts: long-term follow-up in sixty-two cases. *J Hand Surg Am.* 1984;9:901-4.
  10. Zimany A. The bi-lobed flap. *Plast Reconstr Surg* (1946). 1953;11:424-34.
  11. Kleinert HE, Kutz JE, Fishman JH, McCraw LH. Etiology and treatment of the so-called mucous cyst of the finger. *J Bone Joint Surg Am.* 1972;54:1455-8.