



# Reappraisal of anatomical diversity of lateral circumflex femoral artery with its substantial clinical applicability: cadaveric study

Anju Chaudhary<sup>1</sup>, Apurba Patra<sup>1</sup>, Pooja Garg<sup>2</sup>

<sup>1</sup>Department of Anatomy, All India Institute of Medical Sciences, Bathinda, <sup>2</sup>Department of Anatomy, All India Institute of Medical Sciences, Jodhpur, India

**Abstract:** Studies reveal variations in the origin, number, and branching patterns of the lateral circumflex femoral artery (LCFA). The present study aimed to document such variations and their potential clinical applicability. Thirty-two femoral triangles of 16 embalmed adult human cadavers were dissected to investigate the variation in the origin, number, and branching patterns of LCFA. The main branches of the LCFA were tracked independently for numerical variations in branching pattern. The distance between the origin of LCFA and mid inguinal point (MIP) was also measured in each case. LCFA was most commonly arising from profunda femoris (PF), followed by femoral artery (FA) and common trunk of the femoral artery (CFA). Duplication LCFA was observed in 15 (46.87%) limbs, in 5 (31.25%) cases duplication was only on right side, in 4 (25%) cases duplication was only on left side and in 3 (18.75%), duplication was bilateral. Cases with duplication of LCFA, showed numerical variations with descending pattern being the most common. The average distance of LCFA1 and LCFA2 from mid-inguinal point was  $5.77 \pm 1.35$  cm and  $6.14 \pm 2.05$  cm respectively. Detailed information regarding the occurrence of duplication will be great importance for surgeons, interventional radiologists, and other medical professionals performing procedures in the femoral region. Knowledge of variation of branching pattern of LCFA is utmost important as surgeons use the descending branch of the LCFA in bypass grafting and vascular reconstruction surgeries.

**Key words:** Structural variations, Surgical flap, Vascular surgical procedure, Vascular grafting

Received February 17, 2024; Revised April 23, 2024; Accepted May 16, 2024

## Introduction

Variation of arterial system of lower limb have always been of greatest importance due to their involvement in various vascular reconstructive surgeries and catheterization procedures vascular variations are usually subclinical but may put the life of the patients at risk while performing

various clinical procedures [1]. Profunda femoris (PF) is the largest deep branch of femoral artery (FA) which arises from postero-lateral aspect of FA about 3.5-4 cm distal to inguinal ligament. It is the main artery which supplies all three compartments of thigh [1-3]. It gives medial circumflex femoral artery (MCFA), lateral circumflex femoral artery (LCFA), four perforating arteries and muscular branches [2-4].

Precise knowledge about origin of the LCFA is important for surgeons when applying anesthesia to the femoral nerve and in orthopedic surgeries during femoral and hip procedures while harvesting an anterolateral thigh (ALT) flap in reconstructive surgery, in aorto-popliteal bypass and in extra/intracranial bypass surgeries, coronary artery bypass grafting also [5-7]. Anomalous patterns of arterial system are

### Corresponding author:

Apurba Patra

Department of Anatomy, All India Institute of Medical Sciences, Bathinda  
151001, India

E-mail: apurba.cnmco3@gmail.com

Copyright © 2024. Anatomy & Cell Biology

This is an Open Access article distributed under the terms of the Creative Commons Attribution Non-Commercial License (<http://creativecommons.org/licenses/by-nc/4.0/>) which permits unrestricted non-commercial use, distribution, and reproduction in any medium, provided the original work is properly cited.

due to divergence in the form, level of branching, incidence of abnormal compound arterial segments and aberrant vessels that connect with main vessels [3]. The abnormal origins make the artery more susceptible to iatrogenic injury during vascular interventional procedures as catheterization, stenting, embolectomy, angiography, angioplasty [8].

The ALT flap is a fasciocutaneous flap, is grounded on septocutaneous or musculo-cutaneous perforators of descending branch of LCFA. The LCFA along with its septocutaneous branches and musculo-cutaneous perforators are the main blood supply of ALT flaps, a soft-tissue flap used in reconstructive surgeries [1]. Knowledge of variation of branching pattern of LCFA is of utmost important as surgeons use the descending branch of the LCFA in bypass grafting and vascular reconstruction surgeries. It also has use in posterior inferior cerebellar artery revascularization, and oropharyngeal reconstructions [9].

Any variations in the origin of LCFA can potentially change the usual course of the artery and its topographic relationship with the femoral nerve inside the femoral triangle, thus important for regional anesthesiologists performing the femoral nerve block with minimal complications. With this background, the present study was undertaken to investigate the variation in the origin, number, and numerical variations in the branching pattern of LCFA. The distance between the origin of LCFA and mid inguinal point (MIP) was also measured in each case.

## Materials and Methods

A total of 32 lower limbs, obtained from 16 formalin embalmed cadavers (comprising 10 males and 6 females) within an age range of approximately 45 to 70 years, were dissected over a period of three years. These cadavers, originally utilized for routine undergraduate medical educational purposes, were further investigated to document variations in the origin, number of LCFA and mean distance of their origin from mid inguinal point in each case. All cadavers shared a common North Indian origin and exhibited no visible deformities or indications of significant prior surgical interventions in the femoral triangle and thigh region.

The dissection procedure adhered to the systematic guidelines outlined in Cunningham's practical manual for the dissection of the lower limb [10]. Subsequently, the skin, superficial fascia, and fibro-fatty tissue were gently retracted to expose the femoral triangle.

Origin of the LCFA was noted first, followed by their variations in origin and distances from mid-inguinal point. In case of duplication of LCFA, upper one was noted as LCF1 and lower one as LCF2. All the distances were measured with the help of digital vernier calipers (Mitutoyo, Japan with minimum count of 0.01 mm). Three subsequent readings were taken by the same observer and the mean value was taken as final for further analysis.

The data obtained was tabulated and expressed in the form of mean $\pm$ SD. Statistical analysis was done to determine any correlation between muscle or tendon length with laterality and side.

## Results

LCFA was most commonly arising from profunda femoris artery (PFA) (84%), followed by femoral (8%) and common trunk of the FA (6%). Duplication LCFA was observed in 15 (46.87%) limbs, in 5 (31.25%) cases duplication was only on right side, in 4 (25%) cases duplication was only on left side and in 3 (18.75%), duplication was bilateral.

1. In five limbs, double LCFA arises as a common trunk from PF (Fig. 1).
2. In five limbs, double LCFA arises from PF at different level (Fig. 2).
3. In two limbs, LCF1 and PF arise as a common trunk

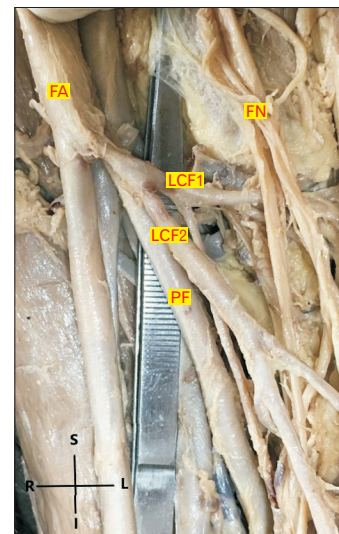


Fig. 1. Showing duplication of lateral circumflex femoral artery (LCFA) arising from profunda femoris (PF) artery as a common trunk. FA, femoral artery; FN, femoral nerve; LCF1, upper LCFA; LCF2, lower LCFA; R, right; S, superior; L, left; I, inferior.

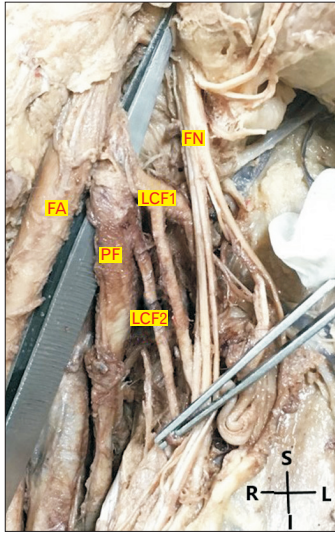


Fig. 2. Duplication of lateral circumflex femoral artery (LCFA) arising from profunda femoris (PF) artery at different level. FA, femoral artery; FN, femoral nerve; LCF1, upper LCFA; LCF2, lower LCFA; R, right; S, superior; L, left; I, inferior.




Fig. 4. Showing origin of LCF1 from profunda femoris (PF) artery and LCF2 arise from FA. LCFA, lateral circumflex femoral artery; FA, femoral artery; FN, femoral nerve; LCF1, upper LCFA; LCF2, lower LCFA; R, right; S, superior; L, left; I, inferior.

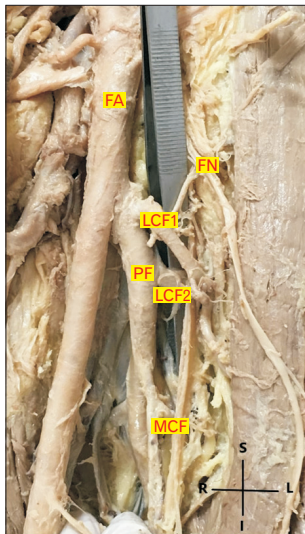


Fig. 3. LCF1 and profunda femoris (PF) artery arises as a common trunk and LCF2 arises from PF. LCFA, lateral circumflex femoral artery; FA, femoral artery; FN, femoral nerve; LCF1, upper LCFA; LCF2, lower LCFA; R, right; S, superior; L, left; I, inferior.

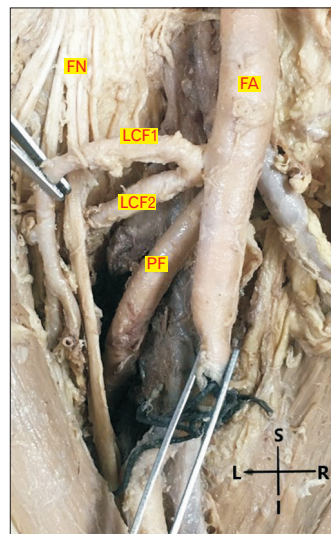


Fig. 5. Showing origin of two LCFA as a common trunk from FA. LCFA, lateral circumflex femoral artery; FA, femoral artery; PF, profunda femoris; FN, femoral nerve; LCF1, upper LCFA; LCF2, lower LCFA; R, right; S, superior; L, left; I, inferior.

from FA and LCF2 arises normally from PF (Fig. 3).

4. In one cadaver, both limbs had double LCFA, out of which LCF1 arise from PF and LCF2 arise from FA (Fig. 4).

5. In one limb, two LCFA arise as a common trunk from FA (Fig. 5).

The average distance of LCF1 and LCF2 from mid-inguinal point was  $5.77 \pm 1.35$  cm and  $6.14 \pm 2.05$  cm respectively.

Although these distances showed no significant right left variations, the average distances of the origin of LCFA from mid inguinal point showed variations depending on the source of origin (Table 1).

The main branches of the LCFA were tracked independently for numerical variations in branching pattern. Cases with single LCFA, had same type of branching pattern on

**Table 1.** Variations in the origin of double lateral circumflex femoral artery

Site of origin of LCFA	Right side	Left side	Bilateral	Mean distance between LCFA and MIP (cm)
Arises as common trunk from PF	3	2	0	6.6
Arises from PF at different level	2	2	1	6.25
From FA common trunk with PF	1	1	0	4.3
LCF1 from PF and LCF2 from FA	1	1	0	6.8
As common trunk from FA	1	0	0	9.7

LCFA, lateral circumflex femoral artery; MIP, mid inguinal point; PF, profunda femoris; FA, femoral artery; LCF1, upper LCFA; LCF2, lower LCFA.

**Table 2.** Numerical branching pattern of lateral circumflex femoral artery

Branching pattern of LCFA	Number of cases	Branching pattern			
		Ascending	Descending	Transverse	
Single	17	1	1	1	
Duplication	3	LCFA1	-	1	2
		LCFA2	-	2	1
	5	LCFA1	-	2	-
		LCFA2	-	-	-
	3	LCFA1	1	2	-
		LCFA2	-	1	1
	3	LCFA1	-	1	2
		LCFA2	1	1	1
	1	LCFA1	-	1	2
		LCFA2	-	-	-

LCFA, lateral circumflex femoral artery; LCF1, upper LCFA; LCF2, lower LCFA.

both sides of lower limbs; ascending (1), transverse (1) and descending (1). Whereas, cases with duplication of LCFA, showed numerical variations with descending pattern being the most common (Table 2). The anatomical shape of the LCFA did not show any difference between gender and side, however outer diameter was more on right than on left ( $P>0.05$ ).

## Discussion

The acquaintance of the site of origin of PFA and its branches is significant during performing clinical procedures in hip joint replacement and the femoral region. It is of great importance for avoiding iatrogenic arteriovenous fistula or severe secondary hemorrhage while performing FA puncture [11]. The anatomical variations change the relationships between the various structures and lack of knowledge of variations of these vessels make the homeostasis difficult to manage [7].

In our study, main PF arises from postero-lateral aspect of FA and average distance from mid inguinal point was 4.69 cm. Whereas Devi et al. [12] reported origin of PF from postero-lateral surface (53.33%), lateral (33.33%), posterior (10%), anterolateral (3.33%) of FA and from external iliac artery in 10% of cases. The average distance of origin from mid

inguinal point was 23 mm.

The LCFA, a branch of the PF and FA, was found originating from the PF in 84% of the legs dissected. In the present study, the origin was more or less similar to the pooled prevalence of 77.6% documented by Tomaszewski et al. [13] following a systematic review of 26 articles.

The normal distance of the origin of the PF from the midpoint of the inguinal ligament is documented by Standring [3] as 35–40 mm. Similar findings were made by Manjappa and Prasanna [14] who documented the mean distance of 35.6 mm from the origin of the PF at the posterolateral aspect of the CFA. In the present study, this distance was 23 mm. Advantages are found in the high origin of the PF from the CFA as these vessels can be used for catheterization and further investigations of any arterial system of the body [15]. However, the distance between the origin of the LCFA from the PF is clinically significant in surgical or angiographic interventions, for health professionals dealing with the PF and its circumflex femoral branches [16, 17].

In patients with total occlusion of FA as well as PF, bypass to the LCFA was found to be successful [18]. Therefore, knowledge of course and branching pattern of LCFA, and its duplication as reported in our study are utmost imperative in management of patients with multilevel occlusive diseases of iliac and femoral arteries.

In our study, the most common site of origin for the LCFA was found to be the PF, this is in line with published literature [18-24]. In our study 84% of these vessels branched from the PF, closely related to the findings of Fukuda et al. [20], Uzel et al. [7], Boonkham and Plakornkul [25] and Rajani et al. [26], who reported these findings to be 78.6%, 77.3%, 77%, and 75.8%, respectively. From various studies done on population of different ethnicities, it is evident that the primary origin of the LCFA is PF, with ranges between 56.7% and 92.3%. Anatomical knowledge of the site of origin of the LCFA is crucial as this vessel greatly contributes to the blood supply of the femoral neck, muscles, and skin over the thigh. Any variations in the origin of LCFA can potentially change the usual course of the artery and its relationship with the femoral nerve inside the femoral triangle, thus important for regional anesthesiologists performing the femoral nerve block with minimal complications [27]. The increased blood supply to this region may decrease the incidence of flap necrosis [28]. The uses of the LCFA can also extend to the reconstruction of large defects in the face, secondary to gunshot wounds [29].

Duplication of LCFA is crucial while operating in the inguinal region. Uzel et al. [7], investigated 110 inguinal regions of 56 cadavers of Turkish population, the LCFA was found to be branched from the deep FA in 85 (77.3%) cases and from the FA in 21 (19.1%) cases. They have also reported common trunk of the deep femoral artery and the LCFA in one (0.9%) case, and a common trunk of the PFA, LCFA, and the MCFA (trifurcation) in another (0.9%). The distance between the mid-inguinal point and the origin of the LCFA were measured. The mean distance between PF and LCFA was  $4.8 \pm 1.2$  cm, while the mean distance of LCFA from FA was  $3.4 \pm 0.9$  cm.

In the present study, we have reported duplication of LCFA in 46.87% of the lower limbs and most remarkably the calibers of LCFA were wider when it arises at a higher level as a separate branch from the FA, which can be mistaken for the PF during surgical and curative interventions. The usual pattern reported in several samples is that both circumflex arteries arise equally from the PFA or FA [30]. However, these findings should be clinically correlated with angiographic findings as there might be some inconsistencies with the findings of cadaveric studies due to difficulties in defining some branches on arteriograms.

Various authors [31, 32] have studied the occurrence of duplication of LCFA and their origin, however, till date no

literature have measured the distance of their origin from MIP while arising from different sources. In the present study, we have measured the mean distance of origin of LCFA and MIP and reported significant differences in these distances, suggest that level and site of origin plays crucial role in the topographic relation of LCFA with neurovascular structures within the femoral triangle. Recognition of these anatomic variations can help in reducing unexpected complications during the femoral nerve block and the tensor fascia lata flap [31]. Hence, flap surgeons should consider these possible variations when harvesting the arterial pedicle for the tensor fascia lata flap. In a patient duplication of LCFA, the risk of accidental nerve injury would increase while approaching the arterial pedicle because of the intimate anatomical relationship between the ascending branch of the LCFA and the femoral nerve [31, 33].

Observations of the present study shows multiple variations in the morphology of the LCFA, these variations probably result from embryological abnormalities during the selection of capillary channels in the developing arterial network of the lower limb [34].

It is imperative to have accurate knowledge of these variant origins during surgery in the thigh and around the hip, in vascular reconstructive procedures or in understanding the pathogenesis of disease affecting proximal portion of the femur and acetabulum [5]. It is valuable when the LCFA system must be transferred as a single composite free tissue for restoration of functional and structural integrity in post-traumatic lower limb reconstruction [35].

In conclusion, detailed information regarding the occurrence of duplication of LCFA and their topographic relation with the neurovascular structures in the femoral triangle is of great importance for surgeons, interventional radiologists, and other medical professionals performing procedures in this region. Recognition of these anatomic variations can help in reducing unexpected complications during the femoral nerve block and the tensor fascia lata flap.

### **Limitations**

The study was done on formalin embalmed cadavers, hence the measurements taken may not be the same as in living due to formalin induced tissue shrinkage.

### **ORCID**

Anju Chaudhary: <https://orcid.org/0000-0001-7414-2990>

Apurba Patra: <https://orcid.org/0000-0002-1107-4481>

Pooja Garg: <https://orcid.org/0000-0002-5585-9141>

## Author Contributions

Conceptualization: AC, PG. Data acquisition: AC, PG. Data analysis or interpretation: AP. Drafting of the manuscript: AP, AC, PG. Critical revision of the manuscript: AP, AC, PG. Approval of the final version of the manuscript: all authors.

## Conflicts of Interest

No potential conflict of interest relevant to this article was reported.

## Funding

None.

## Acknowledgements

The authors sincerely thank those who donated their bodies to science so that anatomical research and teaching could be performed. Results from such research can potentially increase scientific knowledge and can improve patient care.

## References

1. Valdatta L, Tuinder S, Buoro M, Thione A, Faga A, Putz R. Lateral circumflex femoral arterial system and perforators of the anterolateral thigh flap: an anatomic study. *Ann Plast Surg* 2002;49:145-50.
2. McMinn RMH. *Last's anatomy*. 9th ed. Churchill Livingstone; 1994. p. 155-6.
3. Standring S. Pelvic girdle, gluteal region and hip joint, profunda femoris artery. In: Standring S, editor. *Gray's Anatomy, the Anatomical Basis of Clinical Practice*. 40th ed. Elsevier Churchill Livingstone; 2008. p. 1379-80.
4. Mamatha H, D'souza AS, Jessica S, Suhani S. A cadaveric study on the variations in the origin, course and branching pattern of the profunda femoris artery. *Int J Cur Res Rev* 2012;4:137-45.
5. Lin CH, Wei FC, Lin YT, Yeh JT, Rodriguez Ede J, Chen CT. Lateral circumflex femoral artery system: warehouse for functional composite free-tissue reconstruction of the lower leg. *J Trauma* 2006;60:1032-6.
6. Sinkeet SR, Ogeng'o JA, Elbusaidy H, Olabu BO, Irungu MW. Variant origin of the lateral circumflex femoral artery in a black Kenyan population. *Folia Morphol (Warsz)* 2012;71:15-8.
7. Uzel M, Tanyeli E, Yildirim M. An anatomical study of the origins of the lateral circumflex femoral artery in the Turkish population. *Folia Morphol (Warsz)* 2008;67:226-30.
8. Łabętowicz P, Olewnik Ł, Podgórski M, Majos M, Stefańczyk L, Topol M, Polguy M. A morphological study of the medial and lateral femoral circumflex arteries: a proposed new classification. *Folia Morphol (Warsz)* 2019;78:738-45.
9. Strickland BA, Bakhsheshian J, Rennert RC, Fredrickson VL, Lam J, Amar A, Mack W, Carey J, Russin JJ. Descending branch of the lateral circumflex femoral artery graft for posterior inferior cerebellar artery revascularization. *Oper Neurosurg (Hagerstown)* 2018;15:285-91.
10. Romanes GJ. *Cunningham's manual of practical anatomy upper and lower limbs (vol 1)*. 15th ed. Oxford University Press; 1986.
11. Dimri P, Deshwal AK. Bilateral high origin of Profunda femoris artery- a case report and embryological review. *Int J Sci Res* 2014;3:375-6.
12. Devi AM, Kumar S, Bandopadhyay D. Study of anatomical variations of profunda femoris artery in the Indian population. *Indian J Anat* 2019;8:5-8.
13. Tomaszewski KA, Vikse J, Henry BM, Roy J, Pękala PA, Svensen M, Guay D, Saganiak K, Walocha JA. The variable origin of the lateral circumflex femoral artery: a meta-analysis and proposal for a new classification system. *Folia Morphol (Warsz)* 2017;76:157-67.
14. Manjappa T, Prasanna LC. Anatomical variations of the profunda femoris artery and its branches-a cadaveric study in South Indian population. *Indian J Surg* 2014;76:288-92.
15. Dixit D, Kubavat DM, Rathod SP, Patel MM, Singel TC. A study of variations in the origin of profunda femoris artery and its circumflex branches. *Int J Biol Med Res* 2011;2:1084-9.
16. Prakash, Kumari J, Kumar Bhardwaj A, Jose BA, Kumar Yadav S, Singh G. Variations in the origins of the profunda femoris, medial and lateral femoral circumflex arteries: a cadaver study in the Indian population. *Rom J Morphol Embryol* 2010;51:167-70.
17. Keen JA. A study of the arterial variations in the limbs, with special reference to symmetry of vascular patterns. *Am J Anat* 1961;108:245-61.
18. Gradman WS. Bypass to the lateral circumflex femoral artery. *Ann Vasc Surg* 1992;6:344-6.
19. Siddharth P, Smith NL, Mason RA, Giron F. Variational anatomy of the deep femoral artery. *Anat Rec* 1985;212:206-9.
20. Fukuda H, Ashida M, Ishii R, Abe S, Ibukuro K. Anatomical variants of the lateral femoral circumflex artery: an angiographic study. *Surg Radiol Anat* 2005;27:260-4.
21. Sahana SN. Circulatory system, profunda femoris artery. In: Sahana SN, editor. *Human Anatomy*. 3rd ed. The Central Book Agency; 1982. p.245-61.
22. Adachi B. [Three branches of the femoral artery]. In: Adachi B, editor. [The arterial system of the Japanese]. Kaiserlich-Japanischen Universtät zu Kyoto; 1928. p. 147-53. German.
23. Massoud TF, Fletcher EW. Anatomical variants of the pro-

- funda femoris artery: an angiographic study. *Surg Radiol Anat* 1997;19:99-103.
24. Tansatit T, Wanidchaphloi S, Sanguansit P. The anatomy of the lateral circumflex femoral artery in anterolateral thigh flap. *J Med Assoc Thai* 2008;91:1404-9.
  25. Boonkham Y, Plakornkul V. Variational anatomy of the profunda femoris artery in Thais. *Siriraj Med J* 1987;39:441-5.
  26. Rajani SJ, Ravat MK, Rajani JK, Bhedi AN. Cadaveric study of lateral circumflex femoral artery. *Int J Anat Radiol Surg* 2016 Apr 12 [Epub]. <https://doi.org/10.7860/IJARS/2016/20325.2134>
  27. Wong TL, Kikuta S, Iwanaga J, Tubbs RS. A multiply split femoral nerve and psoas quartus muscle. *Anat Cell Biol* 2019;52: 208-10.
  28. Tzouma G, Kopanakis NA, Tsakotos G, Skandalakis PN, Filipou D. Anatomic variations of the deep femoral artery and its branches: clinical implications on anterolateral thigh harvesting. *Cureus* 2020;12:e7867.
  29. Balachandra N, Prakash BS, Padmalatha K, Ramesh BR. Variation in the origin of the lateral circumflex femoral artery: a case report. *Anat Karnataka* 2011;5:76-80.
  30. Suder E, Nizankowski C. Variations in the origin of the deep femoral arteries in human fetuses. *Folia Morphol (Warsz)* 1985; 44:262-9.
  31. Kim H, Nam YS, Kim YS. The ascending branch of the lateral circumflex femoral artery penetrating the posterior division of the femoral nerve. *Anat Cell Biol* 2021;54:124-7.
  32. Zlotorowicz M, Czubak-Wrzosek M, Wrzosek P, Czubak J. The origin of the medial femoral circumflex artery, lateral femoral circumflex artery and obturator artery. *Surg Radiol Anat* 2018; 40:515-20.
  33. Saadeh FA, Haikal FA, Abdel-Hamid FA. Blood supply of the tensor fasciae latae muscle. *Clin Anat* 1998;11:236-8.
  34. Vazquez MT, Murillo J, Maranillo E, Parkin I, Sanudo J. Patterns of the circumflex femoral arteries revisited. *Clin Anat* 2007;20:180-5.
  35. Choi SW, Park JY, Hur MS, Park HD, Kang HJ, Hu KS, Kim HJ. An anatomic assessment on perforators of the lateral circumflex femoral artery for anterolateral thigh flap. *J Craniofac Surg* 2007;18:866-71.