



HIV-negative plasmablastic lymphoma: report of 8 cases and a comprehensive review of 394 published cases

Ya-Jun Li^{1,2#}, Ji-Wei Li^{3,4,5#}, Kai-Lin Chen^{2,6#}, Jin Li^{1,2}, Mei-Zuo Zhong⁷, Xian-Ling Liu⁸, Ping-Yong Yi^{1,2}, Hui Zhou^{1,2}

Department of Lymphoma and Hematology, ¹Hunan Cancer Hospital, ²The Affiliated Cancer Hospital of Xiangya School of Medicine, Central South University, Changsha, ³Department of Pathology, Fudan University Shanghai Cancer Center, ⁴Department of Oncology, Shanghai Medical College, Fudan University, ⁵Institute of Pathology, Fudan University, Shanghai, ⁶Department of Radiotherapy, Key Laboratory of Translational Radiation Oncology, Hunan Cancer Hospital, ⁷Department of Oncology, Xiangya Hospital, Central South University, ⁸Department of Oncology, Cancer Center of the Second Xiangya Hospital, Central South University, Changsha, China

p-ISSN 2287-979X / e-ISSN 2288-0011
<https://doi.org/10.5045/br.2020.55.1.49>
Blood Res 2020;55:49-56.

Received on November 5, 2019
Revised on February 6, 2020
Accepted on March 7, 2020

#These authors contributed equally to this work.

*This study was supported by the grants from Natural Science Foundation of Hunan Province National Health Commission (No. 20201659; No. c2015-52) and the grants from the Hunan Provincial Science and Technology Department (No. 2016JJ3083, No. 2017SK2130).

Correspondence to

Hui Zhou, M.D.
Department of Lymphoma and Hematology, Hunan Cancer Hospital, 283 Tongzipo Road, Yuelu District, Changsha 410013, China
E-mail: zhouhui@hnca.org.cn

© 2020 Korean Society of Hematology

Background

Human immunodeficiency virus (HIV)-negative plasmablastic lymphoma (PBL) is a rare entity of diffuse large B-cell lymphoma (DLBCL). The clinicopathological features of and optimal treatment for HIV-negative PBL remain largely unknown.

Methods

To gain insight into this distinct lymphoma, we summarized the clinicopathologic characteristics of 8 unpublished HIV-negative PBLs and performed a comprehensive review of 394 published cases.

Results

Of the 8 unpublished PBLs, the median patient age was 53.0 years. Four patients presented with stage IV disease. All 8 patients showed a plasma cell-like immunophenotype. Of the six patients who received anthracycline-based chemotherapy, including two who received bortezomib, three patients achieved a continuous complete response, two patients died due to disease progression, and one patient was lost to follow-up. The other two patients achieved continuous complete response after receiving chemotherapy combined with radiotherapy and surgery. Of the 402 patients, the majority were male, with a mean age of 58.0 years. EBV infection was detected in 55.7% of the patients. The median survival times of the patients who received CHOP or CHOP-like regimens and intensive regimens were not reached and 23.0 months, respectively, and the intensive regimen did not improve the survival outcome ($P=0.981$). Multivariate analysis showed that EBV remained the only independent factor affecting overall survival (OS).

Conclusion

HIV-negative PBL is a distinct entity with a predilection for elderly and immunosuppressed individuals. Intensive chemotherapy had no apparent survival benefits over the CHOP regimen in terms of OS; the prognosis of this disease is poor with current chemotherapy methods, and treatment remains a challenge.

Key Words Clinicopathological features, Plasmablastic lymphoma, HIV negative, Treatment, Prognosis

INTRODUCTION

Plasmablastic lymphoma (PBL) is a HIV-related lymphoma that constitutes less than 3% of all non-Hodgkin's lymphoma

[1, 2]. Plasmablastic lymphoma was once considered to occur predominantly in human immunodeficiency virus (HIV)-positive individuals. However, an increasing number of PBLs in immunocompetent patients have been reported in case series around the world. To date, little is known about

HIV-negative PBL, including its epidemiology, clinicopathological features, treatment, and outcome. To further investigate this rare entity, we report our 8 patients with HIV-negative PBL and present an extensive literature review of 394 published cases of HIV-negative PBL.

MATERIALS AND METHODS

Patient selection

This was a retrospective study. Eight patients with PBL between January 2007 and October 2016 were identified through the pathology databases of Xiangya Hospital of Central South University, the Second Xiangya Hospital of Central South University and Hunan Cancer Hospital. All patients were negative for HIV. The histological diagnosis of PBL was based on hematoxylin and eosin (HE) staining and immunohistochemical results according to the 2008 WHO classification of tumors of hematopoietic and lymphoid tissues [1]. The histology slides and reports of all cases were independently reviewed by a second hematopathologist at Hunan Cancer Hospital to confirm the diagnosis.

Review of literature

We conducted a literature search of the PubMed, Embase, and Cochrane Library electronic databases of English journals and CNKI, Wanfang and VIP databases of Chinese journals using the following search terms: 'plasmablastic lymphoma and human immunodeficiency virus-negative/HIV-negative' and 'PBL'. Each article was acquired in full, and the references of each article were examined in an effort to eliminate previously included cases. After excluding reviews without additional cases, unpublished abstracts, cases of HIV infection and cases associated with human herpesvirus 8 (HHV-8) or large B-cell lymphoma arising in HHV-8-associated multicentric Castleman disease (MCD), 394 individual PBL cases were retrieved. All patients expressed at least one of plasma cell marker (CD138, MUM1, VS38c) and were negative or partially positive for CD20.

Ethics approval and consent to participate

Written informed consent to store the patients' blood samples and other medical information in our hospital database was obtained from all of the patients, and we also obtained separate consent to use these data in research. This study was approved by the Institutional Review Board of the National Cancer Institute and the ethics committees of

Table 1. Clinical data of the 8 HIV-negative PBL patients.

	Case 1	Case 2	Case 3	Case 4	Case 5	Cases 6	Case 7	Case 8
Age (yr)	66	42	55	54	52	27	69	43
Sex	Male	Male	Male	Male	Female	Male	Male	Male
ECOG PS	1	1	1	1	1	1	1	1
Primary site (s)	Lymph nodes	Nasopharynx	Oral cavity	Oral cavity	Ileocecum	Bone	Nasal cavity	Skin
Lymph nodes involvement	Yes	Yes	Yes	Yes	Yes	Yes	No	Yes
Other organs involved	Pelvis, humerus, femur, axial skeleton	No	No	Lung	No	No	No	No
B-symptoms	Yes	Yes	Yes	Yes	Yes	Yes	No	No
BM involvement	No	No	No	No	No	No	No	No
Ann Arbor stage	IV	II	II	IV	II	IV	I	IV
Comorbidities	Posthepatic cirrhosis	Diabetes mellitus	No	No	Diabetes mellitus	Hepatitis B	Diabetes mellitus, hypertension	Hepatitis B
Lytic lesions	Yes	No	No	No	No	No	No	No
M protein	IgA	-	-	-	-	-	-	-
CSF cytology	-	-	-	-	-	-	-	-
Surgery	No	No	No	No	Yes	No	No	No
Chemotherapy	Bor+CHOP	GEMOX	Bor+CHOP	CHOP	No	CHOPE	CHOP	CHOP
IFRT	NO	Yes	No	No	No	No	No	No
Response	PR	CR	CR	No	CR	PD	CR	CR
Outcome	DOD	Alive	Alive	DOD	Alive	N/A	Alive	Alive
Follow-up (mo)	6	24	10	3	23	Lost to follow-up	79	45

Abbreviations: BM involvement, bone marrow involvement; Bor, bortezomib; CHOP, cyclophosphamide+doxorubicin+vincristine+prednisolone; CHOPE, cyclophosphamide+doxorubicin+vincristine+prednisolone+etoposide; CR, complete remission; CSF cytology, cerebrospinal fluid cytology; DOD, death of disease; ECOG PS, Eastern Cooperative Oncology Group performance status; GEMOX, gemcitabine+oxaliplatin; IFRT, involved-field radiotherapy; IgA, immunoglobulin A; M protein, monoclonal protein; N/A, not applicable; PBL, plasmablastic lymphoma; PD, progressive disease; PR, partial remission.

Xiangya Hospital of Central South University, the Second Xiangya Hospital of Central South University and Hunan Cancer Hospital. The study was performed in accordance with the Declaration of Helsinki and the institutional guidelines of the local ethics committee.

Data and survival analysis

Overall survival (OS) was defined as the time from the date of diagnosis to the date of death or the last follow-up visit. Survival analysis was performed using the Kaplan-Meier method, and curves were compared using the log-rank test. Significant factors from univariate analysis ($P < 0.05$) were further examined by multivariate analysis with Cox regression. P -values were two-sided, and the level of significance was set at $P < 0.05$. Statistical analyses were performed by using SPSS 19.0 software (SPSS Inc., Chicago, IL, USA).

RESULTS

Case reports

The clinical data of all 8 patients are summarized in Table 1. All patients were negative for human immunodeficiency virus, and the median age at diagnosis was 53.0 years (27.0–69.0 yr). B symptoms were present in 6 patients. The primary sites included the lymph nodes, nasopharynx, oral cavity, ileocecum, bone and skin. Four patients presented stage IV disease (case 1, case 4, case 6, and case 8), three presented stage II disease and, one presented stage I disease. One patient (case 1) showed clinical characteristics of plasma cell myeloma, such as monoclonal IgA spikes and lytic bone lesions observed by computed tomography (CT) scans, but serum calcium, blood urea nitrogen (BUN) and creatinine were in normal ranges.

All the 8 patients showed morphologic features of diffuse large B-cells, with or without plasmacytic differentiation, and showed a plasma cell-like immunophenotype. In our study, all the patients were positive for MUM1 and negative for CD20 and CD45. CD138 and CD38 were positive in 4 cases and negative in one case. CD79a, Pax5, and EMA were variably positive. The average proliferation index was 90% (range from 80% to 100%). EBER-1 in situ hybridization was performed in all cases, and only one patient had positive results. HHV 8 was negative in all cases (Table 2).

Of the eight patients, six patients received anthracycline-based chemotherapy, including two patients who received bortezomib (case 1, case 3). Three patients achieved complete response (CR) and were still alive without disease, while the other two patients (cases 1, case 4) progressed and died after 3 and 6 months, respectively, due to disease progression. The remaining patient was lost to follow-up four months after diagnosis. One patient (case 2) achieved CR after receiving chemotherapy with GEMOX (gemcitabine, oxaliplatin) and involved-field radiotherapy and was still alive at the time of follow-up. One patient (case 5) underwent right hemicolectomy and did not receive adjuvant chemotherapy. She is alive and asymptomatic and has had no disease progression for 23 months postoperatively.

Clinicopathological features in 394 published cases and our 8 cases

Data from our 8 cases and the 394 reported HIV-negative PBL cases are summarized in Table 3. HIV-negative PBL occurred in a wide spectrum of patients, aged from 1 to 88 years, with a median age at diagnosis of 58.0 years. As Table 3 shows, patients older than 60 years accounted for 42.7% of all the patients. HIV-negative PBL was more common in males, with a male to female ratio of 2.79. Although most patients (53.5%) presented with advanced stage disease,

Table 2. The immunohistochemical characteristics of the 8 cases of HIV negative PBL cases.

	Case 1	Case 2	Case 3	Case 4	Case 5	Case 6	Case 7	Case 8
CD45	-	-	-	-	-	-	-	-
CD20	-	-	-	-	-	+	-	-
CD79a	+	++	-	-	-	+	+	+/-
PAX5	-	++	-	-	+	+	-	-
CD3	-	+/-	-	-	+	-	-	-
CD38	-	+	+	+	+	+	+	+
CD138	++	-	+	+	+	+	+	+/-
MUM1	+	+	+	+	+	+	+	+
EMA	+	-	+	-	-	-	-	-
CD56	-	-	-	-	-	-	-	-
KAPPA/LAMBDA	N/A	+	N/A	-	-	+	N/A	+
CYCLIN D1	+	-	-	-	-	-	-	-
EBER1	-	++	-	-	-	-	-	-
CD10/BCL2/BCL6	-	+	-	-	-	+	-	-
Ki-67	90%	90%	95%	80%	100%	80%	85%	80%
HHV 8	-	-	-	-	-	-	-	-

Abbreviations: N/A, not applicable; PBL, plasmablastic lymphoma.

Table 3. The characteristics of the 402 PBL patients.

Characteristics	Total	%	IC			PT		
			Total (N)	EBV+ (N)	EBV- (N)	Total (N)	EBV+ (N)	EBV- (N)
No. of cases	402	100	311	104	90	56	44	8
Sex (M/F)	296/106	73.6/26.4	228/85	72/20	56/22	44/12	26/3	4/2
Age (yr, >60/≤60)	126/169	42.7/57.3	101/123	50/42	35/43	13/23	12/17	1/5
Median (range, yr)	58.0 (1–88)		60.0	62.0	59.0 (24–83)	54.0 (1–79)	NA	NA
Ann Arbor stage (I–II/III–IV)	153/176	46.5/53.5	124/136	44/39	19/36	16/19	5/9	0/3
B symptoms (yes/no)	50/69	42.0/58.0	33/53	11/19	12/16	3/8	1/5	2/2
LDH level (elevated/normal)	45/38	54.2/45.8	31/33	12/17	11/9	7/3	4/3	3/0
Primary involved site	295							
Oral cavity	37	12.5	29	10	9	4	4	0
LN	67	22.7	52	23	20	6	5	0
Gastrointestinal tract	54	18.3	43	12	18	7	3	2
Other extranodal sites	137	46.4	100	45	29	21	17	4
BM involvement (yes/no)	49/261	15.8/84.2	33/165	7/75	12/48	8/21	6/17	1/1
Immunosuppression status	365							
No immunosuppression	229	62.7	238	82	76	0	0	0
With immunosuppression	136	37.3	73	24	14	39	30	8
Post transplantation	56/136		0	0	0	39	30	8
Immune-related disease	53		51	22	11	1	1	0
Current or previous malignancy	25		25	2	5	0	0	0
CD38+	110/126	87.3	81/95	30/36	24/32	6/6	4/4	1/1
CD138+	310/342	90.6	256/280	68/76	61/70	44/51	24/27	5/6
MUM1+	206/224	92.0	172/188	50/51	46/55	24/27	13/15	2/2
VS38c+	21/22	95.5	10/11	6/6	2/3	5/5	4/4	1/1
CD20+	38/361	10.5	20/294	5/89	2/70	6/51	2/27	0/6
CD30	27/115	21.7	25/95	19/43	4/38	1/11	1/5	0/4
CD79a+	68/152	44.7	56/130	22/48	16/43	9/13	5/9	2/2
CD45+	68/139	48.9	56/120	19/33	19/46	12/18	11/16	1/1
CD56+	41/168	24.4	33/141	14/51	9/53	10/31	9/23	0/6
EMA+	39/69	56.5	26/48	6/15	13/20	2/6	1/4	0/1
Ki-67+ (median, range)	80% (1–100%)		NA	NA	NA	NA	NA	NA
EBER+	173/309	56.0	123/243	103/103	0/89	44/52	NA	NA
MYC rearrangement	51/97	52.6	38/68	20/34	13/25	9/20	8/17	1/3
Treatment	253		202	75	51	18	12	2
Surgery	44	17.4						
Chemotherapy	233	92.1	191	71	50	15	9	2
Radiation therapy	49	19.4	35	11	5	10	5	2
Stem cell transplant	17		14	3	4	0	0	0
Chemotherapy regimens	233							
CHOP or CHOP-like	124/233	53.2	101	50	23	8	6	1
Intensive chemotherapy	44/233	18.9	39	8	12	2	0	0
Bor-based chemotherapy	16/233	6.9	13	3	7	1	1	0
Other regimen	51/233	21.9	40	9	8	4	1	1
Survival (mo, N=256)								
Median	19.0		23.0	NR	18.0	19.0	19.0	NA
Mean	46.7		53.0	78.2	23.3	33.3	36.5	3.0
Range	0–120		1–120	1–120	1–52	0–70	0–70	1–4

Abbreviations: BM, bone marrow; Bor, bortezomib; IC, immunocompetent; LDH, lactate dehydrogenase; LN, lymph node; NA, not available; NR, not reached; PBL, plasmablastic lymphoma; PT, posttransplant.

bone marrow involvement was present in only 15.8% of the patients. The most involved sites were the lymph nodes, gastrointestinal tract and oral cavity. EBV infection was common in HIV-negative PBL, involving 56.0% of the patients. Immunosuppression, including post-transplantation status, immune-related disease and current or previous malignancy,

was noted in many patients (37.3%). The immunohistochemical characteristics of the 402 patients are summarized in [Table 3](#).

Treatment and prognostic factors

The treatments for 253 patients are summarized in [Table](#)

3, and chemotherapy was administered to 233 patients (92.1%). More than half of the patients (124/233) received a CHOP or CHOP-like chemotherapy regimen. Approximately 17.4% of the patients underwent surgery, and 19.4% of the patients received radiotherapy. Forty-four patients received an intensive regimen, including hyper-CVAD (hyperfractionated cyclophosphamide, vincristine, doxorubicin, and dexamethasone), DA-EPOCH (dose-adjusted etoposide, doxorubicin, vincristine, cyclophosphamide, prednisone), and CODOX-M/IVAC (CODOX-M: cyclophosphamide, vincristine, doxorubicin, high-dose methotrexate; IVAC: ifosfamide, etoposide and high-dose cytarabine). Bortezomib combined with chemotherapy was given to 16 patients in the first-line or salvage treatment setting. Fifteen patients underwent autologous stem cell transplantation (SCT) after achieving CR1 or partial response (PR) 1, and two patients received SCT as salvage therapy after disease progression.

Of the 253 treated patients, 46.2% achieved CR, 26.9% achieved PR, 0.8% achieved stable disease, and 25.7% achieved primary progressive disease. The one-year and

two-year OS rates were 55.9% and 44.8%, respectively (Fig. 1A). The median survival time of patients receiving intensive regimens was 23.0 months, however, the median survival time of those who received CHOP or CHOP-like regimen has not yet been reached. The intensive regimen did not improve the survival outcome (Fig. 1B). Bortezomib combined with chemotherapy was given to 14 PBL patients (including two from unpublished cases) without HIV infection as first-line treatment [3-12]; 10/14 achieved CR or PR, and the median survival time was 11.0 months. A bortezomib-based regimen was also used in two refractory/recurrent patients; however, although dramatic clinical response was achieved, these two patients died shortly after because of disease progression [3, 13, 14]. For stage I patients, the application of radiotherapy did not improve OS, and the one-year OS rate was 80.0% vs. 83.8% for patients with and without radiotherapy ($P=0.926$).

In this study, univariate analysis revealed that the significant factors affecting OS included disease stage ($P < 0.001$), B symptoms ($P=0.001$), LDH level ($P=0.025$), EBER

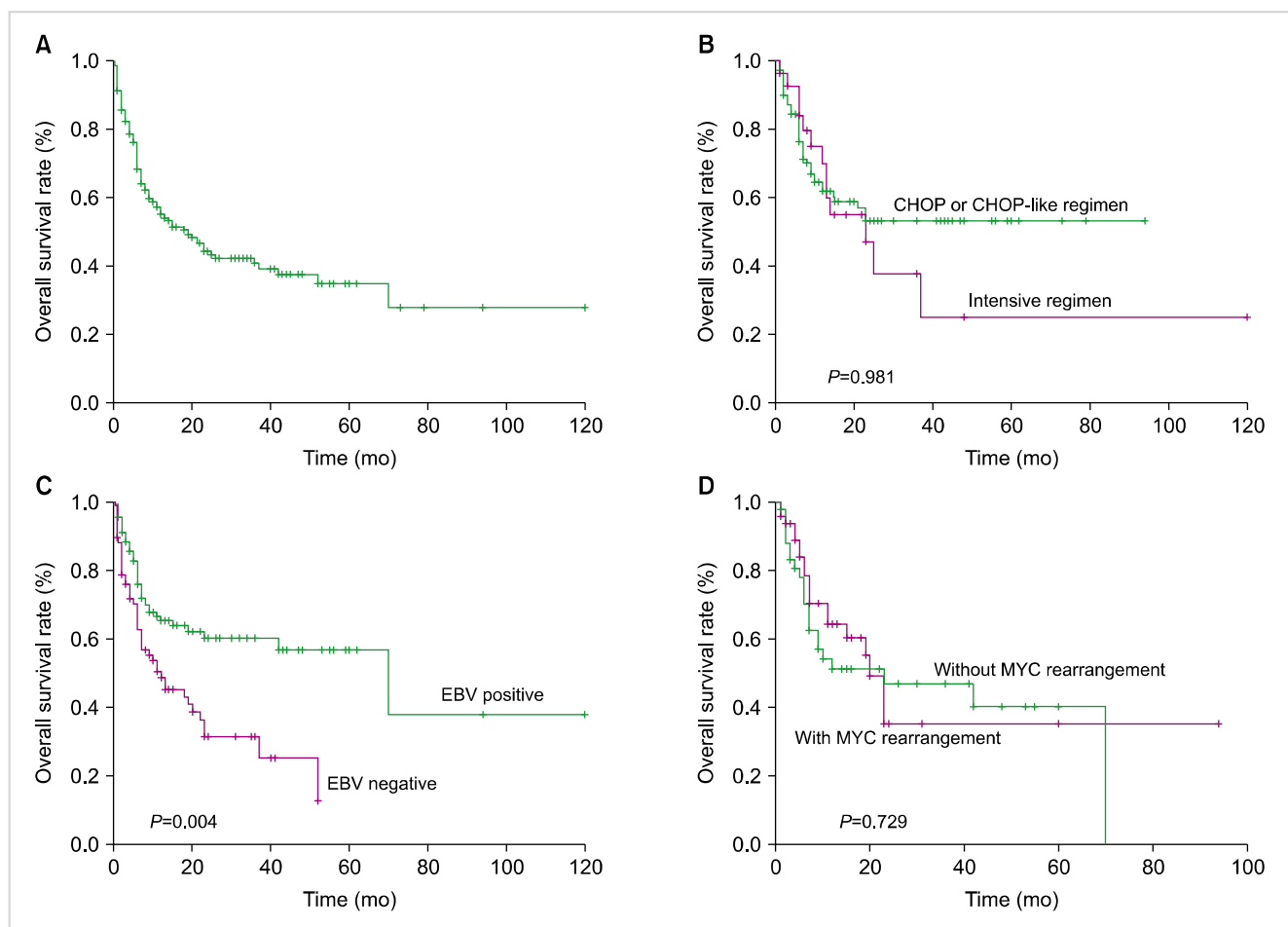


Fig. 1. (A) The 1-year and 2-year overall survival rates were 55.9% and 44.8%, respectively (N=253). (B) The median survival time of patients receiving intensive regimens was 23.0 months, while the median survival time of those who received CHOP or CHOP-like regimen has not yet been reached. Intensive regimen did not improve the survival outcome ($P=0.981$). (C) Significant impact of EBV on overall survival (OS). Patients with EBV positivity showed a significantly better OS (1-year OS, 65.0% vs. 51.5%; $P=0.004$). (D) Significant impact of MYC rearrangement on OS. MYC rearrangement did not affect the survival outcome (1-year OS, 64.3% vs. 52.4%; $P=0.729$).

($P=0.004$) (Fig. 1C), chemotherapy ($P=0.010$) and CR status ($P<0.001$). However, MYC rearrangement failed to predict the survival outcome of PBL (Fig. 1D; $P=0.729$). Multivariate analysis showed that EBER ($P=0.016$) remained the only significant independent factor affecting OS.

Non-transplanted patients

The median age of these patients was 60 years. Among the 316 patients, 28 patients had a history of malignancy, and 53 patients were complicated with autoimmune disease. The lymph nodes were the most frequently affected site, followed by the gastrointestinal tract and oral cavity. The EBV+PBL group and EBV-PBL group of non-transplanted patients harbored similar clinical (Table 3) and pathologic (Table 3) characteristics.

The mean and median survival times of non-transplanted patients were 53.0 and 23.0 months, respectively. EBER expression was associated with a better outcome (1-year OS, 66.0% vs. 55.4%; $P=0.005$). CD45 expression and MYC rearrangement did not affect the survival outcome. The median survival time of the EBV-positive IC-PBL subgroup has not yet been reached, and the median survival time of EBV-negative IC-PBL subgroup was 18.0 months.

PBL in transplant recipients

The median age of HIV-negative post-transplanted patients was younger than that of non-transplanted patients (54 yr vs. 60 yr). The most commonly involved sites were the gastrointestinal tract and lymph nodes. Autoimmune disease occurred in only one patient.

The survival time of transplant recipients was similar to that of non-transplanted patients, with a median survival time of 19.0 months. MYC rearrangement was relatively less detected in transplanted patients than in non-transplanted patients and failed to predict the survival outcome.

DISCUSSION

PBL is a rare tumor subtype that has a predilection for HIV-positive individuals, accounting for approximately 2.6% of HIV-related lymphoma [15]. In this report, we investigated the clinicopathologic characteristics, treatment, outcome and prognostic factors of 402 patients with HIV-negative PBL (including 8 unpublished cases).

The pathogenesis of HIV-negative PBL remains unclear. EBV infection, MYC gene rearrangements and other genetic alterations are possible pathogenic factors. In situ hybridization for EBV-encoded RNA (EBER) was positive in over half of the HIV-negative PBL patients in our study and was associated with favorable survival outcomes. The overexpression of PD-L1 in EBV+PBL indicated that these tumors may evade immune responses through the PD-1/PD-L1 pathway, which could provide inhibitory signals that downregulate T-cell function [16]. We hypothesize that EBV infections may be important in the tumorigenesis of HIV-negative PBL. Some types of cytogenetic variations, including

IG/MYC rearrangements and abnormal expression of p16, MDR-1, and PRDM1, have been detected in HIV-negative PBL [16-18]. IG/MYC rearrangements are the main cytogenetic alteration in plasmablastic lymphomas and were once proposed as an adverse predictor of PBL [19, 20]. In our study, IG/MYC aberrations were detected in approximately half of the patients and failed to predict the survival outcome of PBL, which is consistent with other reports [15, 20]. MYC rearrangement may be associated with EBV status and PRDM1 and play a significant role in the pathogenesis of PBL [16, 18].

HIV-negative PBL occurred in patients aged 1 to 88 years old, showing a predilection for the elderly population and male patients [21, 22]. It seems that HIV-negative PBLs are more heterogeneous in primary locations than in HIV-positive cases, of which the predominant site of involvement is the oral cavity [23, 24]. HIV-negative PBL can occur in various organs, including the gastrointestinal tract, sinonasal cavity, bone marrow, skin, and lung [22, 25]. In our study, the most commonly involved site was the lymph nodes, followed by the gastrointestinal tract and oral cavity. Our data showed that PBL was present in over half of the patients without HIV, which is similar to HIV-associated PBL [24]. Compared with HIV-negative PBL patients, patients with HIV-associated PBL have a significantly higher expression of EBER (75%) and ki67 (median, 90%) [24]. However, the expression of CD20 (7.2%) was relatively lower and the expression of CD56 (2.2%) was slightly higher in HIV-positive PBL than in HIV-negative patients in our research [24], and this result is inconsistent with a previous study that showed that HIV-positive individuals have a significantly higher expression of CD20 and CD56 [26].

The optimal treatment of PBL has not yet been established. The prognosis of this rare lymphoma is poor with currently available chemotherapy. CHOP (cyclophosphamide, hydroxydaunorubicin, vincristine, and prednisone) or CHOP-like chemotherapy is a common regimen used for HIV-negative PBL, with an overall response rate of approximately 60-70% [27, 28]. More aggressive chemotherapy regimens, including hyper-CVAD, CODOX-M/IVAC and DA-EPOCH, are recommended by the National Comprehensive Cancer Network (NCCN), as these regimens may lead to better outcomes [29]. However, consistent with previous studies [15, 30], our data showed that there was no apparent survival benefit of intensive chemotherapy over CHOP or CHOP-like regimens.

Some novel agents have shown some activity in HIV-negative PBL patients and may play an important role in first-line treatment in the future. Bortezomib is a proteasome inhibitor that may have a potent effect in treating HIV-negative PBL when combined with or without chemotherapy, and it may overcome typical chemoresistance and improve survival outcomes [6, 8, 31]. Bortezomib combined with chemotherapy has achieved good outcomes and was well tolerated in some cases. Recently, a retrospective study including 8 cases of PBL (5 patients were HIV-positive, 2 were HIV-negative, 1 with a history of liver transplantation) demonstrated that

bortezomib in combination with etoposide, prednisone, vincristine, cyclophosphamide, and doxorubicin (V-EPOCH) was a safe and effective regimen for PBL, with a complete response rate of 100% and 2-year OS rate of 50% [32]. In our study, the overall response rate of patients treated with bortezomib-containing regimens was 71.4%, and the median overall survival time was 11 months. It seems that bortezomib may be more effective in patients with HIV infection. The relatively small sample size, individual variations, and diversity of chemotherapy may also affect the results. The role of bortezomib in the treatment of HIV-negative PBL needs further investigation. The immunomodulator lenalidomide was also reported to be effective in a patient with HIV-negative PBL [33]. Approximately 30% of PBLs express the activation marker CD30, providing the rationale for the use of an anti-CD30 antibody. Brentuximab vedotin has shown activity against HIV-negative PBL in a patient with relapsed PBL with CD30 expression [34]. The GEMOX (gemcitabine, oxaliplatin) regimen was used in one of our cases and led to long-term remission. Gemcitabine and oxaliplatin were applied to one HIV-associated PBL patient and achieved good results when combined with other chemotherapy drugs [35]. The GEMOX regimen was also reported to be effective in an HIV-negative PBL patient who achieved PR, underwent auto-hematopoietic stem cell transplantation (HSCT) and was still alive after 26 months of follow-up [11]. The GEMOX regimen may be an effective and tolerant chemotherapy regimen for PBL. Although the above regimens have achieved success in some cases, prospective clinical trials with large samples are sparse on account of the rarity of the disease, and the treatment of HIV-negative PBL is still a challenge.

Compared with chemotherapy or radiotherapy, auto-HSCT may produce better outcomes for patients with high-risk disease. Our study demonstrated that HIV-negative PBL patients who received auto-HSCT after achieving CR or PR gained survival benefits. Auto-HSCT might be feasible and beneficial for the consolidation of first-line responses in patients with PBL, especially for those with high-risk disease [25, 36]. Allo-HSCT was reported to successfully induce durable remission for a patient with refractory HIV-negative PBL in a case report [37]. The treatment value of auto-HSCT and allo-HSCT in HIV-negative PBL warrants further prospective clinical trials.

Overall, the prognosis of patients with HIV-negative PBL remains dismal with current treatment, with a median survival time of 6 to 19 months [21, 22, 24, 38, 39]. Our results are similar to those of these studies, with a median survival time of approximately 8 months. Notably, the primary sites did not affect the survival outcome.

Several risk factors for HIV-negative PBL have been identified in previous studies, including clinical stage, immunosuppression status, EBV status, patient CR status, and international prognostic index (IPI) [22, 38, 39]. In our study, a univariate analysis showed that disease stage, B symptoms, LDH level, EBER status, chemotherapy and CR status were significant factors affecting the OS rates. However, only

EBER status remained a significant independent factor in the multivariate analysis.

In conclusion, PBL is a rare malignancy with a poor prognosis, and intensive chemotherapy did not provide better survival outcomes for HIV-negative PBL than the CHOP regimen. EBER status may be an independent prognostic factor of survival, and new drugs need to be investigated for PBL.

ACKNOWLEDGMENTS

KLC, JL collected the data, YJL and JWJ performed the statistical analysis and drafted the manuscript. MZZ, XLL, HZ and PYY designed the study and helped to revise the manuscript. All authors read and approved the final manuscript.

The authors would like to thank investigators, patients, and their families.

Authors' Disclosures of Potential Conflicts of Interest

No potential conflicts of interest relevant to this article were reported.

REFERENCES

1. Campo E, Swerdlow SH, Harris NL, Pileri S, Stein H, Jaffe ES. The 2008 WHO classification of lymphoid neoplasms and beyond: evolving concepts and practical applications. *Blood* 2011;117:5019-32.
2. Gu X, Zheng R, Xia C, et al. Interactions between life expectancy and the incidence and mortality rates of cancer in China: a population-based cluster analysis. *Cancer Commun (Lond)* 2018;38:44.
3. Saba NS, Dang D, Saba J, et al. Bortezomib in plasmablastic lymphoma: a case report and review of the literature. *Onkologie* 2013;36:287-91.
4. Cao C, Liu T, Zhu H, Wang L, Kai S, Xiang B. Bortezomib-contained chemotherapy and thalidomide combined with CHOP (Cyclophosphamide, Doxorubicin, Vincristine, and Prednisone) play promising roles in plasmablastic lymphoma: a case report and literature review. *Clin Lymphoma Myeloma Leuk* 2014;14:e145-50.
5. Yan M, Dong Z, Zhao F, et al. CD20-positive plasmablastic lymphoma with excellent response to bortezomib combined with rituximab. *Eur J Haematol* 2014;93:77-80.
6. Castillo JJ, Reagan JL, Sikov WM, Winer ES. Bortezomib in combination with infusional dose-adjusted EPOCH for the treatment of plasmablastic lymphoma. *Br J Haematol* 2015; 169:352-5.
7. Zanelli M, Ragazzi M, Valli R, et al. Unique presentation of a plasmablastic lymphoma superficially involving the entire large bowel. *Pathol Res Pract* 2015;211:1030-3.
8. Cencini E, Fabbri A, Guerrini S, Mazzei MA, Rossi V, Bocchia M. Long-term remission in a case of plasmablastic lymphoma treated

- with COMP (cyclophosphamide, liposomal doxorubicin, vincristine, prednisone) and bortezomib. *Eur J Haematol* 2016;96:650-4.
9. Fedele PL, Gregory GP, Gilbertson M, et al. Infusional dose-adjusted epoch plus bortezomib for the treatment of plasmablastic lymphoma. *Ann Hematol* 2016;95:667-8.
 10. Konishi Y, Kaneko H, Nishi K, Imada K. Plasmablastic lymphoma of the gallbladder. *Int J Hematol* 2016;104:1-3.
 11. Li F, Ding W, Zuo Z, et al. Plasmablastic lymphoma: a clinicopathologic analysis of 11 cases with review of literature. *Zhonghua Bing Li Xue Za Zhi* 2016;45:37-42.
 12. Han X, Hu LX, Ouyang MQ, Duan MH, Zhou DB. Clinical characteristics and survival analysis of eight cases HIV-negative plasmablastic lymphoma. *Zhonghua Xue Ye Xue Za Zhi* 2017;38:290-4.
 13. Lipstein M, O'Connor O, Montanari F, Paoluzzi L, Bongero D, Bhagat G. Bortezomib-induced tumor lysis syndrome in a patient with HIV-negative plasmablastic lymphoma. *Clin Lymphoma Myeloma Leuk* 2010;10:E43-6.
 14. Castillo JJ, Reagan JL. Plasmablastic lymphoma: a systematic review. *ScientificWorldJournal* 2011;11:687-96.
 15. Castillo JJ, Furman M, Beltrán BE, et al. Human immunodeficiency virus-associated plasmablastic lymphoma: poor prognosis in the era of highly active antiretroviral therapy. *Cancer* 2012;118:5270-7.
 16. Laurent C, Fabiani B, Do C, et al. Immune-checkpoint expression in Epstein-Barr virus positive and negative plasmablastic lymphoma: a clinical and pathological study in 82 patients. *Haematologica* 2016;101:976-84.
 17. Matsuki E, Miyakawa Y, Asakawa S, et al. Identification of loss of p16 expression and upregulation of MDR-1 as genetic events resulting from two novel chromosomal translocations found in a plasmablastic lymphoma of the uterus. *Clin Cancer Res* 2011;17:2101-9.
 18. Montes-Moreno S, Martinez-Magunacelaya N, Zecchini-Barrese T, et al. Plasmablastic lymphoma phenotype is determined by genetic alterations in MYC and PRDM1. *Mod Pathol* 2017;30:85-94.
 19. Bogusz AM, Seegmiller AC, Garcia R, Shang P, Ashfaq R, Chen W. Plasmablastic lymphomas with MYC/IgH rearrangement: report of three cases and review of the literature. *Am J Clin Pathol* 2009;132:597-605.
 20. Valera A, Balagué O, Colomo L, et al. IG/MYC rearrangements are the main cytogenetic alteration in plasmablastic lymphomas. *Am J Surg Pathol* 2010;34:1686-94.
 21. Liu JJ, Zhang L, Ayala E, et al. Human immunodeficiency virus (HIV)-negative plasmablastic lymphoma: a single institutional experience and literature review. *Leuk Res* 2011;35:1571-7.
 22. Liu M, Liu B, Liu B, et al. Human immunodeficiency virus-negative plasmablastic lymphoma: a comprehensive analysis of 114 cases. *Oncol Rep* 2015;33:1615-20.
 23. Castillo J, Pantanowitz L, Dezube BJ. HIV-associated plasmablastic lymphoma: lessons learned from 112 published cases. *Am J Hematol* 2008;83:804-9.
 24. Morscio J, Dierickx D, Nijs J, et al. Clinicopathologic comparison of plasmablastic lymphoma in HIV-positive, immunocompetent, and posttransplant patients: single-center series of 25 cases and meta-analysis of 277 reported cases. *Am J Surg Pathol* 2014;38:875-86.
 25. Lin L, Zhang X, Dong M, et al. Human immunodeficiency virus-negative plasmablastic lymphoma: A case report and literature review. *Medicine (Baltimore)* 2017;96:e6171.
 26. Castillo JJ, Winer ES, Stachurski D, et al. Clinical and pathological differences between human immunodeficiency virus-positive and human immunodeficiency virus-negative patients with plasmablastic lymphoma. *Leuk Lymphoma* 2010;51:2047-53.
 27. Castillo JJ, Bibas M, Miranda RN. The biology and treatment of plasmablastic lymphoma. *Blood* 2015;125:2323-30.
 28. He XH, Li B, Yang S, et al. R-CHOP regimen can significantly decrease the risk of disease relapse and progression in patients with non-germinal center B-cell subtype diffuse large B-cell lymphoma. *Chin J Cancer* 2012;31:306-14.
 29. Horwitz SM, Zelenetz AD, Gordon LI, et al. NCCN Guidelines insights: Non-Hodgkin's lymphomas, version 3.2016. *J Natl Compr Canc Netw* 2016;14:1067-79.
 30. Castillo JJ, Winer ES, Stachurski D, et al. Prognostic factors in chemotherapy-treated patients with HIV-associated plasmablastic lymphoma. *Oncologist* 2010;15:293-9.
 31. Ye H, Desai A, Gong T, et al. Spontaneous regression of mantle cell lymphoma: a report of four cases. *Cancer Commun (Lond)* 2018;38:30.
 32. Dittus C, Grover N, Ellsworth S, Tan X, Park SI. Bortezomib in combination with dose-adjusted EPOCH (etoposide, prednisone, vincristine, cyclophosphamide, and doxorubicin) induces long-term survival in patients with plasmablastic lymphoma: a retrospective analysis. *Leuk Lymphoma* 2018;59:2121-7.
 33. Schmit JM, DeLaune J, Norkin M, Grosbach A. A case of plasmablastic lymphoma achieving complete response and durable remission after lenalidomide-based therapy. *Oncol Res Treat* 2017;40:46-8.
 34. Holderness BM, Malhotra S, Levy NB, Danilov AV. Brentuximab vedotin demonstrates activity in a patient with plasmablastic lymphoma arising from a background of chronic lymphocytic leukemia. *J Clin Oncol* 2013;31:e197-9.
 35. Bibas M, Grisetti S, Alba L, Picchi G, Del Nonno F, Antinori A. Patient with HIV-associated plasmablastic lymphoma responding to bortezomib alone and in combination with dexamethasone, gemcitabine, oxaliplatin, cytarabine, and pegfilgrastim chemotherapy and lenalidomide alone. *J Clin Oncol* 2010;28:e704-8.
 36. Al-Malki MM, Castillo JJ, Sloan JM, Re A. Hematopoietic cell transplantation for plasmablastic lymphoma: a review. *Biol Blood Marrow Transplant* 2014;20:1877-84.
 37. Nishi K, Mitani S, Hatanaka K, Imada K. Successful cord blood transplantation for an HIV-negative patient with refractory plasmablastic lymphoma. *Ann Hematol* 2017;96:1057-8.
 38. Castillo JJ, Winer ES, Stachurski D, et al. HIV-negative plasmablastic lymphoma: not in the mouth. *Clin Lymphoma Myeloma Leuk* 2011;11:185-9.
 39. Tchernonog E, Faurie P, Coppo P, et al. Clinical characteristics and prognostic factors of plasmablastic lymphoma patients: analysis of 135 patients from the LYSA group. *Ann Oncol* 2017;28:843-8.