

Accessory mental foramen: A rare anatomical variation detected by cone-beam computed tomography

Marianna Guanaes Gomes Torres^{1,*}, Ludmila de Faro Valverde¹, Manuela Torres Andion Vidal¹,
Iêda Margarida Crusoé-Rebello¹

¹Department of Oral Radiology, School of Dentistry, Federal University of Bahia, Salvador, BA, Brazil

ABSTRACT

The mental foramen is a bilateral opening in the vestibular portion of the mandible through which nerve endings, such as the mental nerve, emerge. In general, the mental foramen is located between the lower premolars. This region is a common area for the placement of dental implants. It is very important to identify anatomical variations in presurgical imaging exams since damage to neurovascular bundles may have a direct influence on treatment success. In the hemimandible, the mental foramen normally appears as a single structure, but there are some rare reports on the presence and number of anatomical variations; these variations may include accessory foramina. The present report describes the presence of accessory mental foramina in the right mandible, as detected by cone-beam computed tomography before dental implant placement. (*Imaging Sci Dent 2015; 45: 61-5*)

KEY WORDS: Anatomic Variation; Cone-Beam Computed Tomography; Mandible

The mental foramen is a bilateral opening in the vestibular portion of the mandible through which nerve endings – such as the mental nerve, a branch of the inferior alveolar nerve – and the corresponding arteries and veins emerge. After passing through the mental foramen, the mental nerve splits into three branches which innervate, for example, the skin of the chin and that of the lower lip.¹⁻⁶ In general, the mental foramen is located between the lower premolars³⁻⁸ and is used as a reference in anesthetic techniques such as the incisive/mental nerve block. In dental practice, the importance of this structure is mainly related to the positioning of dental implants and to other surgical procedures in this region. Special care must be taken when accessory mental foramina are present.^{5,9}

Radiographically, the mental foramen is observed as a rounded or oval radiolucent area at the level of the lower premolar apices^{2,3} or superimposed on them. In the hemimandible, the mental foramen normally appears as a single

structure, but there are some rare reports on the anatomical variations of the mental foramen, presence of accessory foramina^{3,9-11} or the absence of mental foramen.^{7,8} In these situations, the nerves and vessels that go through the mental foramen must follow alternative courses.⁷

Accessory mental foramina can be observed in conventional radiographs and by computed tomography (CT) and cone-beam computed tomography (CBCT).^{3,9} However, since the accessory mental foramina are usually smaller than 1.0 mm, their identification by two-dimensional exams is difficult.^{5,12} CBCT has become established as a diagnostic tool that can provide detailed information about the structures of the maxillofacial complex, permitting the identification and evaluation of anatomical variations.^{3,5,7} It is possible, for example, to evaluate the mental foramen and accessory mental foramina on the axial, sagittal, and coronal sections in order to direct the surgical procedures to be performed in this region.⁷

It is important to identify anatomical variations in presurgical imaging exams since damage to neurovascular bundles might have a direct influence on treatment success. The present report describes the presence of an accessory

Received September 6, 2014; Revised October 13, 2014; Accepted October 26, 2014
*Correspondence to: Dr. Marianna Guanaes Gomes Torres
Alameda Pádua, No. 470, Pituba, Salvador, BA, CEP 41830-480, Brazil
(Tel) 55-71-33550917, Fax) 55-71-21084300, E-mail) torresmarianna@hotmail.com

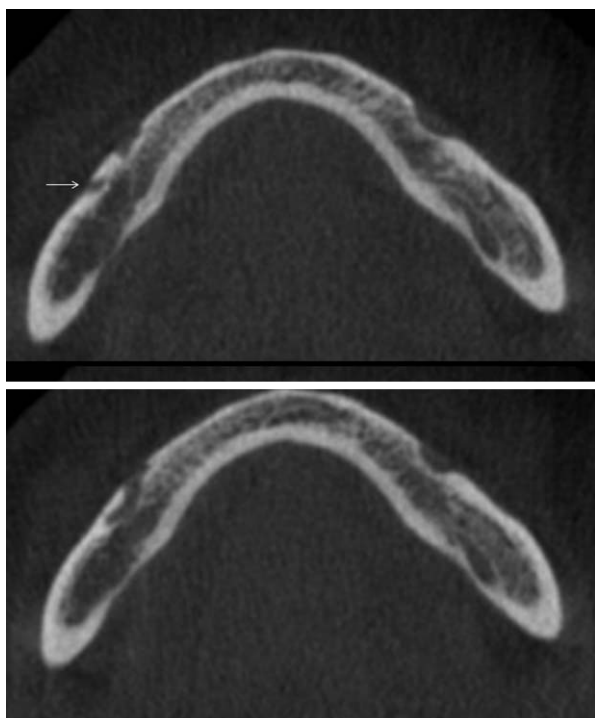


Fig. 1. Axial sections of the mandible show the presence of two mental foramina on the right side and one on the left. The foramina are located at the same level, and the accessory foramen (arrow) on the right side is located in the distal direction.

mental foramen in the right mandible, as detected by CBCT before dental implant placement.

Case Report

A 63-year-old male patient was submitted to CBCT (i-CAT, Imaging Sciences International, Hatfield, PA, USA) of the mandible for the planning of rehabilitating treatment with dental implants. Intraoral and extraoral examinations showed no significant findings, and the patient was asymptomatic.

Sequential axial sections in the craniocaudal direction (Fig. 1), sequential parasagittal sections obtained every 1 mm in the distomesial direction (Fig. 2), and coronal sections in the posteroanterior direction (Fig. 3) revealed the presence of two mental foramina on the right side of the mandible, while only one foramen could be identified on the left side. At the level of the second premolar, before its opening in the vestibular portion of the mandible, the mandibular canal on the right side showed a ramification with a distinct and independent intraosseous course in the posterior direction and an additional opening in the vestibular cortical bone of the mandible. The mental foramen and accessory mental foramen, measuring 2.83 and 1.75

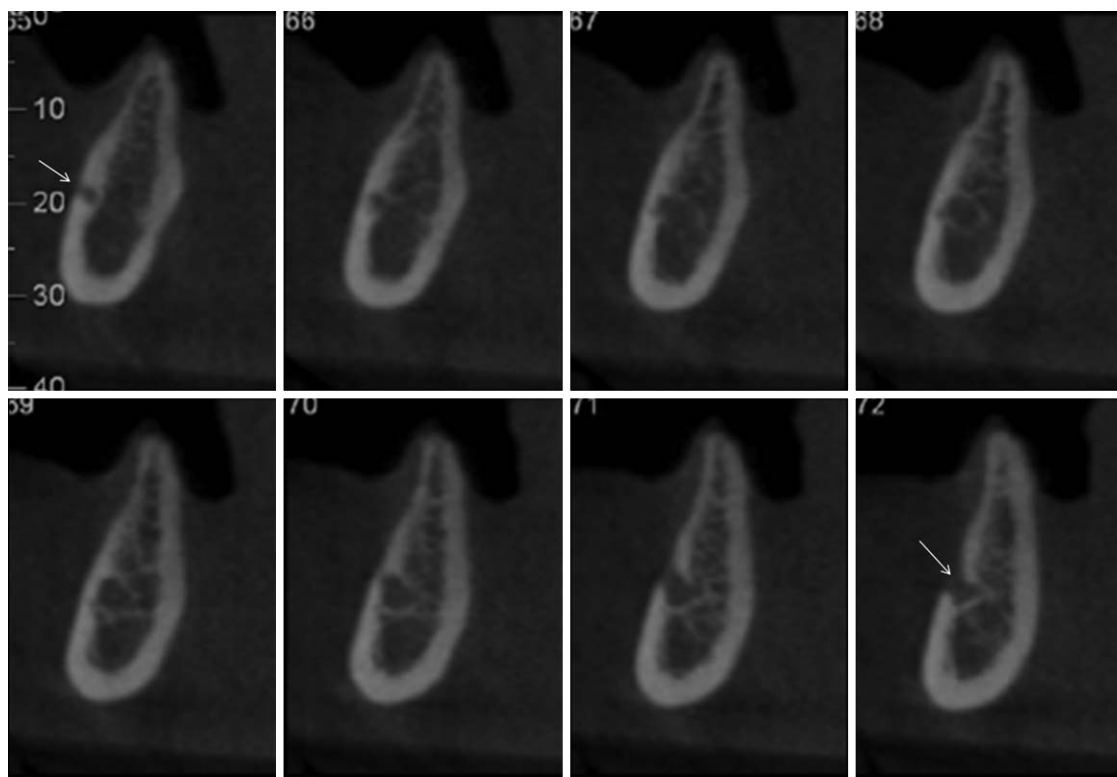


Fig. 2. Sequential parasagittal sections obtained every 1 mm in the distomesial direction on the right side of the mandible show the presence of two openings of the mandibular canal in the vestibular direction (two mental foramina) (arrows).

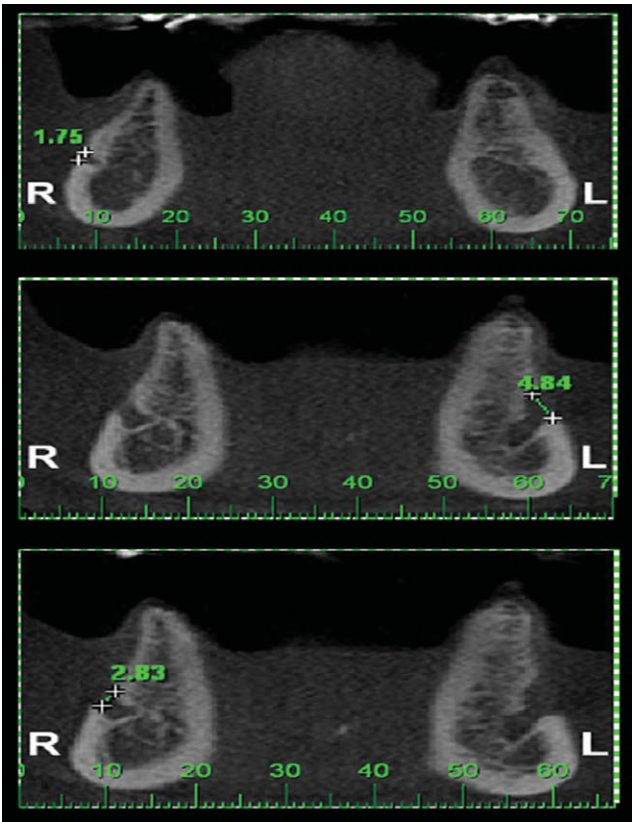


Fig. 3. Sequential coronal sections in the posteroanterior direction show two mental foramina on the right side and one on the left side, with their respective measurements in millimeters.

mm in diameter, respectively, were present at the same height, with the accessory mental foramen in a slightly posterior position. The mental foramen on the left side was a single structure located at the same height as the others, but with a diameter of 4.84 mm.

Three-dimensional reconstruction demonstrated the presence of two mental foramina on the right side and only one, of wider diameter, on the left side (Fig. 4). In the panoramic radiograph, we could not observe the presence of the accessory mental foramen (Fig. 5).

Discussion

Precise knowledge of vital anatomical structures such as the inferior alveolar nerve and the mental nerve is fundamental to obtaining favorable results after surgical procedures such as dental implant placement.⁶ This also applies to the mental foramen, through which the ramifications of the inferior alveolar nerve emerge.¹² Although rare, variations associated with the mental foramen have been reported,^{3,10,11} which might cause morbidities in the patient,

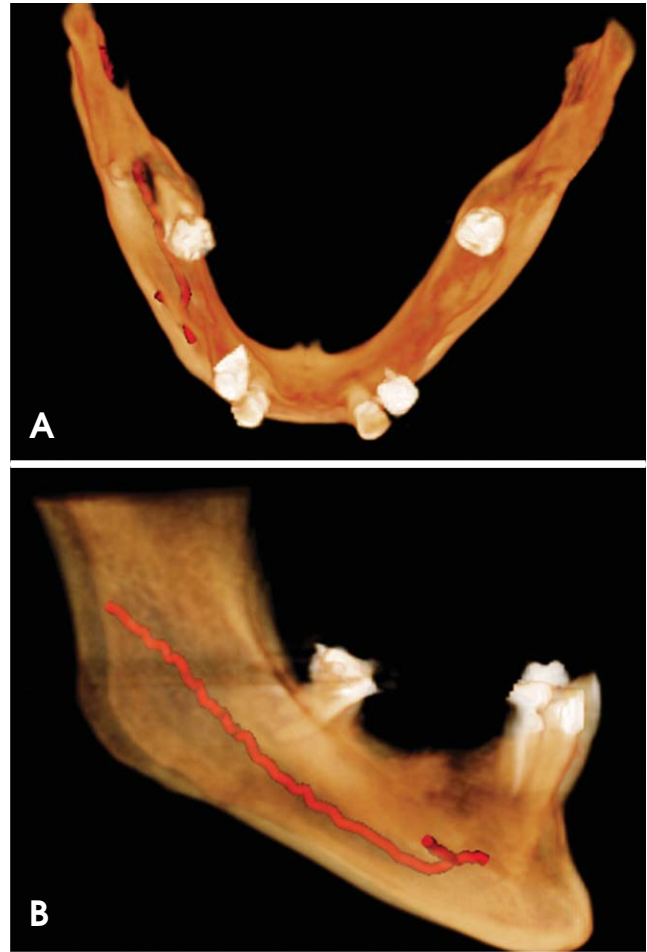


Fig. 4. Superior (A) and right lateral (B) view of three-dimensional cone-beam computed tomography reconstruction of the mandible show the presence of an accessory mental foramen on the right mandible.

such as possible injuries due to surgical procedures, if undetected.⁶

Regarding the mental foramen, variations are observed in its location, with the reference point being encountered more anteriorly, below the canine, or posteriorly, close to the second molar. Variations in the number of foramina have also been reported, with more than one mental foramen being present on one or more sides of the mandible. These additional foramina are called accessory mental foramina.⁶ This variation results from the ramification of the mental nerve before emerging into the mental foramen.^{3,10}

In the identification of anatomical variations, it is important to differentiate an accessory mental foramen from a nutrient foramen. The accessory mental foramen is an opening in the bone originating from a ramification of the mandibular canal, as observed in the present case. Conversely, the nutrient foramen does not originate in the mandi-

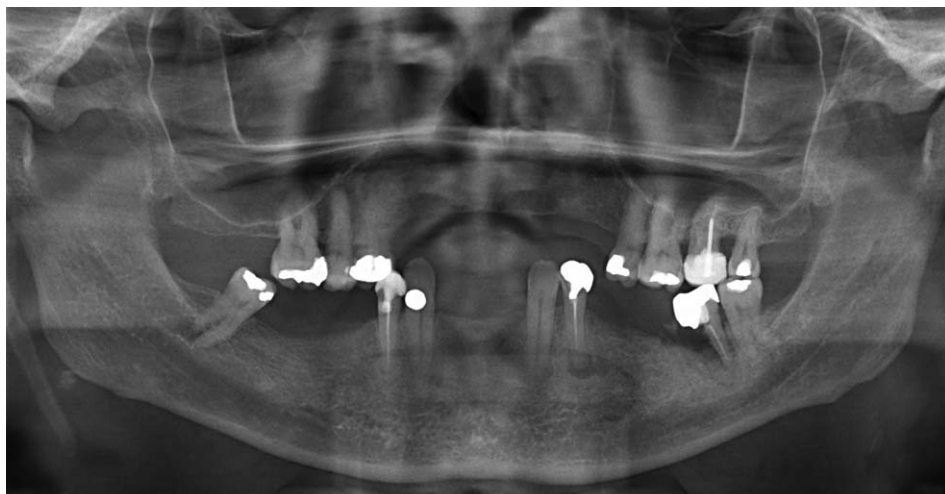


Fig. 5. The accessory mental foramen is not detected on the panoramic radiograph.

bular canal and its dimensions are comparatively small.³

In our case, the dimensions of the right mental foramen and of the accessory mental foramina were 2.83 and 1.75 mm, respectively. On the basis of other studies,^{12,13} we considered accessory mental foramina the smallest among them. An accessory mental foramen is usually less than 1.0 mm in size,^{5,12} but in the present case, the accessory mental foramen was relatively wide, posing a greater risk of surgical complications in this region. The mean diameter of the mental foramen is typically 3.0 mm, ranging from 1.8 to 5.1 mm.¹⁴ In the present case, the left mental foramen was 4.84 mm in diameter, which was considered larger than the mean, but within normal limits.

Katakami et al.,¹² in a study of 150 patients, observed the presence of 17 accessory mental foramina by CBCT, with 59% of them being located posteriorly to the mental foramen. Another study conducted on 157 patients demonstrated the presence of 15 accessory mental foramina, nine of them located posteriorly to the mental foramen.¹³ On the basis of these findings, the present study agreed with the literature since the accessory mental foramina detected here were slightly dislocated in a posterior direction with respect to the mental foramen. The location of the accessory mental foramen would directly affect the planning of rehabilitating treatment since it might interfere with the procedures performed for a dental implant. If the accessory mental foramina would be located inferiorly to the mental foramen, for example, the interference caused by their presence, will be lower or practically nonexistent since the planning would already be based on the location of the mental foramen.

When an accessory mental foramen is identified, more attention should be paid to obtaining successful treatment.

Damage to neurovascular bundles may cause hemorrhage, paresthesia, or dysesthesia, among other consequences.⁶ Thakur et al.¹¹ emphasized the importance of identifying the accessory mental foramen before the treatment of neuralgia, since in patients with this variation, incomplete neurectomy of the mental nerve results in treatment failure and symptom recurrence.

Some studies on accessory mental foramina are available in the literature, but most of them were conducted on dry mandibles.^{1,15} Sawyer et al.¹ conducted an anthropological study on different ethnic groups and observed an accessory mental foramen frequency of 1.5% to 12.5%, with no clear predilection for gender or age. In general, only one accessory mental foramen is observed in a hemimandible, although the presence of three such foramina has also been reported.^{1,15} Clinical and radiographic studies of this condition are less frequent,¹⁰ and an even smaller proportion of cases involve CT and CBCT.^{3-5,12,13,16}

Although Çağırankaya and Kansu¹⁰ observed an accessory mental foramen using conventional radiographs, these exams could not precisely identify the presence and the course of the mandibular canal, the mental foramen, and the accessory mental foramina due to the distortion of the image or the low contrast between the foramen and the mandibular trabecular bone.⁶ Naitoh et al.¹⁷ compared the identification of an accessory mental foramen in panoramic radiographs and in reconstruction images (CBCT). After examining 365 patients, the authors detected 37 accessory mental foramina with the aid of CBCT and only 18 accessory mental foramina on panoramic radiographs. Further, Kulkarni et al.¹⁸ reported a case in which the accessory mental foramen and its nervous component were discovered accidentally during surgery since the presurgical pano-

ramic radiography had not revealed any variation. Thus, a precise accessory mental foramen analysis is only possible with CT/CBCT, which provides an image of better quality and lower distortion than conventional exams do.¹¹

The presence of anatomical variations in the maxilla and the mandible is still frequently neglected. It is important to underscore that these variations can be identified in pre-surgical imaging exams, permitting more accurate planning and contributing to successful treatment. Since conventional radiographs may fail in the identification of variations, CBCT is of fundamental importance in this process. The recognition of accessory mental foramina contributes to the use of an appropriate surgical technique, preventing eventual damage to the nerves and vessels in the lower premolar and molar regions.

References

1. Sawyer DR, Kiely ML, Pyle MA. The frequency of accessory mental foramina in four ethnic groups. *Arch Oral Biol* 1998; 43: 417-20.
2. Vayvada H, Demirdover C, Yilmaz M, Barutcu A. An anatomic variation of the mental nerve and foramina: a case report. *Clin Anat* 2006; 19: 700-1.
3. Neves FS, Oliveira LS, Torres MG, Crusoé-Souza M, Oliveira C, Campos PS, et al. Accessory mental foramen: case report. *RPG Rev Pós-Grad* 2010; 17: 173-6.
4. Neves FS, Torres MG, Oliveira C, Campos PS, Crusoé-Rebello I. Lingual accessory mental foramen: a report of an extremely rare anatomical variation. *J Oral Sci* 2010; 52: 501-3.
5. Imada TS, Fernandes LM, Centurion BS, de Oliveira-Santos C, Honório HM, Rubira-Bullen IR. Accessory mental foramina: prevalence, position and diameter assessed by cone-beam computed tomography and digital panoramic radiographs. *Clin Oral Implants Res* 2014; 25: e94-9.
6. Pancer B, Garaicoa-Pazmiño C, Bashutski JD. Accessory mandibular foramen during dental implant placement: case report and review of literature. *Implant Dent* 2014; 23: 116-24.
7. da Silva Ramos Fernandes LM, Capelozza AL, Rubira-Bullen IR. Absence and hypoplasia of the mental foramen detected in CBCT images: a case report. *Surg Radiol Anat* 2011; 33: 731-4.
8. Matsumoto K, Araki M, Honda K. Bilateral absence of the mental foramen detected by cone-beam computed tomography. *Oral Radiol* 2013; 29: 198-201.
9. Balcioglu HA, Kocaelli H. Accessory mental foramen. *N Am J Med Sci* 2009; 1: 314-5.
10. Çağırankaya LB, Kansu H. An accessory mental foramen: a case report. *J Contemp Dent Pract* 2008; 9: 98-104.
11. Thakur G, Thomas S, Thayil SC, Nair PP. Accessory mental foramen: a rare anatomical finding. *BMJ Case Rep* 2011; 2011: bcr0920103326.
12. Katakami K, Mishima A, Shiozaki K, Shimoda S, Hamada Y, Kobayashi K. Characteristics of accessory mental foramina observed on limited cone-beam computed tomography images. *J Endod* 2008; 34: 1441-5.
13. Naitoh M, Hiraiwa Y, Aimiya H, Gotoh K, Arijji E. Accessory mental foramen assessment using cone-beam computed tomography. *Oral Surg Oral Med Oral Pathol Oral Radiol Endod* 2009; 107: 289-94.
14. von Arx T, Friedli M, Sendi P, Lozanoff S, Bornstein MM. Location and dimensions of the mental foramen: a radiographic analysis by using cone-beam computed tomography. *J Endod* 2013; 39: 1522-8.
15. Udhaya K, Saraladevi KV, Sridhar J. The morphometric analysis of the mental foramen in adult dry human mandibles: a study on the South Indian population. *J Clin Diagn Res* 2013; 7: 1547-51.
16. Igarashi C, Kobayashi K, Yamamoto A, Morita Y, Tanaka M. Double mental foramina of the mandible on computed tomography images: a case report. *Oral Radiol* 2004; 20: 68-71.
17. Naitoh M, Yoshida K, Nakahara K, Gotoh K, Arijji E. Demonstration of the accessory mental foramen using rotational panoramic radiography compared with cone-beam computed tomography. *Clin Oral Implants Res* 2011; 22: 1415-9.
18. Kulkarni S, Kumar S, Kamath S, Thakur S. Accidental identification of accessory mental nerve and foramen during implant surgery. *J Indian Soc Periodontol* 2011; 15: 70-3.