

# 고도 방실전도차단 환자에서 실신을 초래한 Torsade de Pointes

차광수<sup>1</sup> · 박태호<sup>1</sup> · 이철종<sup>1</sup> · 정치영<sup>1</sup> · 이성원<sup>1</sup> · 문창훈<sup>1</sup>  
 김진호<sup>1</sup> · 이겸철<sup>2</sup> · 김형권<sup>1</sup> · 김무현<sup>1</sup> · 김영대<sup>1</sup> · 김종성<sup>1</sup>

## Torsade de Pointes in Advanced Atrioventricular Block : A Cause of Syncope

Kwang Soo Cha, MD<sup>1</sup>, Tae Ho Park, MD<sup>1</sup>, Cheol Jong Lee, MD<sup>1</sup>, Chi Young Jeong, MD<sup>1</sup>,  
 Sung Won Lee, MD<sup>1</sup>, Chang Hoon Moon, MD<sup>1</sup>, Jin Ho Kim, MD<sup>1</sup>, Gyum Cheol Lee, MD<sup>2</sup>,  
 Hyeong Kweon Kim, MD<sup>1</sup>, Moo Hyun Kim, MD<sup>1</sup>, Young Dae Kim, MD<sup>1</sup>,  
 Young Dae Kim, MD<sup>1</sup> and Jong Seong Kim, MD<sup>1</sup>

<sup>1</sup>Department of Cardiology, Dong-A University Hospital, Department of Internal Medicine,  
<sup>2</sup>Pusan Adventist Hospital, Pusan, Korea

### ABSTRACT

Advanced or complete atrioventricular (AV) block is frequently regarded as a cause of informed syncopal attacks even though escape rhythm is maintained. Torsades de pointes (TdP) may be a significant complication of AV block associated with QT prolongation. Maintaining ventricular rate over 70 beats/min is known to be important to normalize QT interval and to reduce the possibility of bradycardia-related TdP recurrence after pacemaker implantation. We report one case of syncopal attacks associated with TdP in a 70 year old female patient with advanced AV block and prolonged QT interval. She was referred to evaluate palpitation and syncope. Advanced AV block and QT interval prolongation were seen with electrocardiography, but junctional escape rhythm was maintained. Syncopal attacks occurred during temporary pacemaker insertion. Multiple episodes of nonsustained polymorphic ventricular tachycardia and TdP related to syncopal attacks were demonstrated by 24-hour Holter monitoring. A permanent pacemaker was implanted and ventricular rate was set over 70 beats/min resulting in no recurrence of TdP and syncope. (**Korean Circulation J 1998;28(4):626-631**)

**KEY WORDS** : Torsade de pointes · Atrioventricular block · Permanent.

서론	(undulation), QT interval)	QRS (coupling
Torsade de pointes(TdP)가	TdP	(escape rhythm)
: 1997 12 26		
: 1998 4 27		
: , 602 - 715	3가 1	
) (051) 240 - 2976,	) (051) 242 - 1449	TdP

170/110 mmHg,

TdP 64 /

가

QT (440 ms ) 70 / (100 / )  
9-13)

torsades de pointes 50

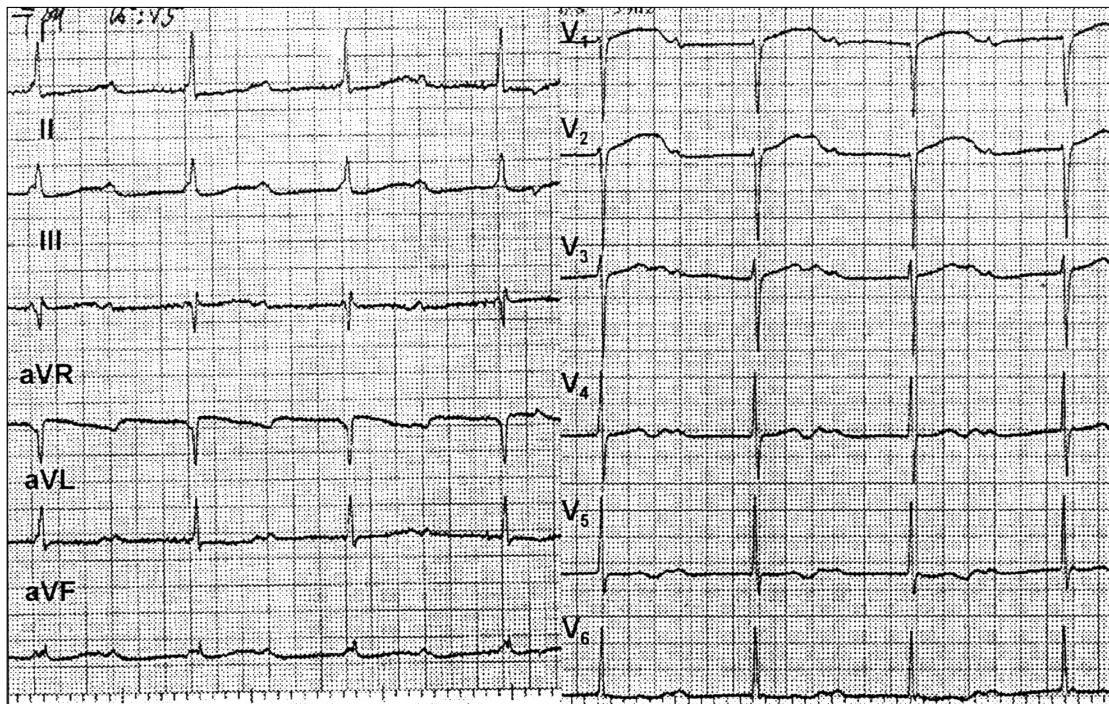
QT / . QRS , QU  
 600 msec

70 / 1 (Fig. 1). 1 6  
 가 72 / , 78 / QT 440  
 msec, 480 msec

증 례 40 / (demand mode)  
 24

67 가 1

가 2 40 45 / . QT  
 가 가 5 640 msec , T  
 (Fig. 2 - A). Couplets,  
 triplets



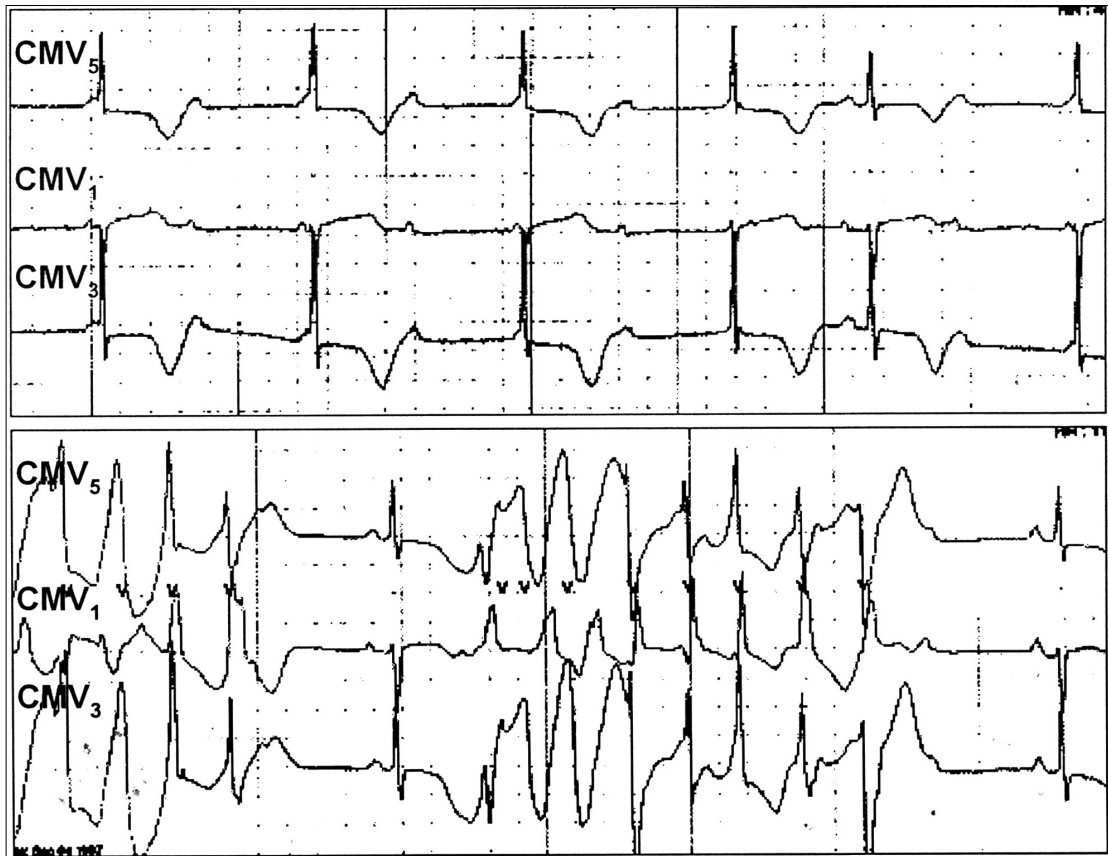
**Fig. 1.** Surface electrocardiogram obtained immediately after syncope at emergency room. Basic rhythm was sinus tachycardia (about 100beats/min) and complete atrioventricular block with stable junctional escape rhythm (about 50 beats/min) was seen. QU interval was markedly prolonged (600ms) in precordial leads.

51 . Torsade de pointes 1500 /48  
 , long -short RR torsade de pointes  
 cycle sequence (coupling interval) 5

T  
 RR cycle length가  
 QRS 가 (Figs. 고 안  
 2 - B and 3).

K 5.14 mEq/L, Mg 2.1 mg/dL( Torsade de pointes(TdP)  
 : 1.9 2.5 mg/dL), total Ca/ionized Ca 8.7  
 mg/dL/1.03 mmol/L( : 8 10 mg/dL/1.16 1966 Desserte -  
 1.32 mmol/L) , CK/CK - MB 62/6 nne  
 U/L QT

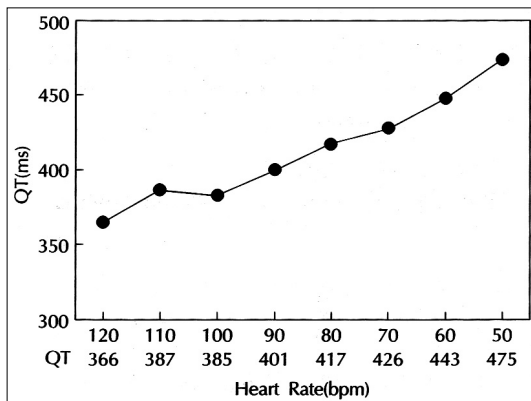
3 (DDD ) , class IA IC , QT



**Fig. 2.** Holter electrocardiographic recording showed advanced atrioventricular block and junctional escape rhythm (40 - 45beats/min). The QT interval was prolonged (640msec). The T wave exhibited an abnormal and bizarre contour (A). Note the typical electrocardiographic features of the torsade de pointes ; long-short RR cycle sequences preceded the onset of tachycardia and late premature ventricular complex occurring in the downslope of T wave initiated episode of tachycardia (B).



**Fig. 3.** Holtter electrocardiographic recording showed a typical long episode of torsade de pointes (TdP). A sinus beat was followed, after a pause after a ventricular couplet, by a TdP. The tachycardia was terminated spontaneously with progressive prolongation of cycle length and larger and more distinctively formed QRS complexes. Motion artifact was noted at the end of the tachycardia as the patient lost consciousness.



**Fig. 4.** Relation between QT interval and heart rate in this patient. The QT interval increased linearly when the heart rate was decreased. When the heart rate was decreased to 60 beats/min, the QT interval was markedly increased. QT prolongation was more prominent at 50 beats/min.

14-26) TdP  
가 가  
TdP가 동반되기 쉬운 방실전도차단의 심전도 특징  
torsade de pointes(TdP)  
Holter  
TdP  
가가  
TdP 가  
Strasberg Kurita  
TdP가

QT QTc QRS 가 가 68 / TdP가 가

(QT : 753 ± 57.5 ms vs. 635 ± 78.4 ms, QTc : 585 ± 44.8 ms vs. 476 ± 58.3 ms).<sup>9)27)</sup> T TdP가 가

TdP가 TdP가 가 80 90 /

(Fig. 2 - A) TdP가 가

(broad, large - amplitude), 가

(bizarre)<sup>9)</sup> QT 70 /

가 가 60 / TdP가

( "pseudo " 2 : 1 atrioventricular(AV) block T 가 70 /

wave alternation) 가 . " Pseudo " 2 : 1 QT 440 ms 가

AV block 가 P 가<sup>9)10)13)</sup>

가 T 가

2 : 1 가<sup>28)</sup>

QT 요 약

T TdP

가 가 . Torsade

de pointes(TdP) QT

70 /

TdP가 동반된 방실전도차단에서 심박조율기 치료의 특징

TdP QT 가 QT TdP 가

<sup>10)</sup> 39 (right ventricular effective re - 70 가 가

ractory period) TdP가 QT

TdP가 가 (378 ± 14 ms vs. 343 ± 35 ms).<sup>29)</sup> TdP

가 가 TdP 가 70 /

가 가 TdP

. Nurnberg 중심 단어 : . Torsadede pointes.

260 2

13.6%

REFERENCES

- 1) Krikler DM, Curry PVL. *Torsade de pointes, an atypical ventricular tachycardia. Br Heart J* 1976;38:117-20.
- 2) Kossman CE. *Torsade de pointes: An addition to the nos-ography of ventricular tachycardia. Am J Cardiol* 1978; 42:1054-6.
- 3) Singh BN, Gaarder TD, Kanegae T. *Liquid protein diets*

- and torsade de pointes. *JAMA* 1978;240:115-9.
- 4) Schwartz SP, Orloff J, Fox C. Transient ventricular fibrillation: I. The prebrillatory period during established auriculoventricular dissociation with a note on the phonocardiogram obtained at such times. *Am Heart J* 1949;37:21-35.
  - 5) Schwartz SP, Hallinger LN, Imperiali A. Transient ventricular fibrillation: IV. The effect of procainamide on patients with transient ventricular fibrillation during established auriculoventricular dissociation. *Circulation* 1952; 6:193-200.
  - 6) Schwartz SP, Margolies MP, Firenze A. Transient ventricular fibrillation: V. The effect of the oral administration quinidine sulfate on patients with transient ventricular fibrillation during established auriculoventricular dissociation. *Am Heart J* 1953;45:404-15.
  - 7) Schwartz SP, Hallinger LN. Transient ventricular fibrillation: VI. Observations on peripheral arterial pulse pressures in the course of transient ventricular fibrillation during established auriculoventricular dissociation. *Am Heart J* 1954;48:390-404.
  - 8) Steinbrecher UP, Fitchett DH. Torsade de pointes: A cause of syncope with atrioventricular block. *Arch Intern Med* 1980;140:1223-6.
  - 9) Kurita T, Ohe T, Marui N, Aihara N, Takaki H, Kamakura S, Matsuhisa M, Shimomura K. Bradycardia-induced abnormal QT prolongation in patients with complete atrioventricular block with torsade de pointes. *Am J Cardiol* 1992;69:628-33.
  - 10) Disegni E, Klein HO, David D, Libhaber C, Kaplinsky E. Overdriving pacing in quinidine syncope and other long QT-interval syndromes. *Arch Intern Med* 1980;140: 1030-40.
  - 11) Eldar M, Griffin JC, Abbott JA, Benditt D, Bhandari A, Herre JM, Benson DW, Scheinman MM. Permanent cardiac pacing in patients with the long QT syndrome. *J Am Coll Cardiol* 1987;10:600-7.
  - 12) Eldar M, Griffin JC, Van Hare GF, Witherell C, Benditt D, Scheinman MM. Combined use of beta-adrenergic blocking agents and long-term cardiac pacing for patients with the long QT syndrome. *J Am Coll Cardiol* 1992;20: 830-7.
  - 13) Cho JG. Indications of artificial pacemaker. In: *Subcommittee of cardiology. editor. Cardiology Symposium;1997 Apr. p11-24.*
  - 14) Dessertenne F. La tachycardie ventriculaire a deux foyers opposes variables. *Arch Mal Coeur* 1966;59:263-72.
  - 15) Schwartz PJ, Periti M, Malliani A. The long QT syndrome. *Am Heart J* 1975;89:378.
  - 16) Moss AJ, Schwartz PJ. Sudden death and the idiopathic long QT syndrome. *Am J Med* 1979;66:6-7.
  - 17) Schwartz PJ. Idiopathic long QT syndrome: Progress and questions. *Am Heart J* 1985;109:399-411.
  - 18) Moss AJ, Schwartz PJ, Crampton RS. The long QT syndrome: A prospective international study. *Circulation* 1985; 71:17-21.
  - 19) Zipes DP. Specific arrhythmias: Diagnosis and treatment, in *Heart Disease. Braunwald E, 5th Ed. p685, Philadelphia, WB Saunders Co, 1997.*
  - 20) Lee CW, Doo YC, Song JK, Kim JJ, Park SW, Park SJ, Lee JK. A case of astemizole induced Torsade de Pointes. *Kor J Int Med* 1992;43(5):701-5.
  - 21) Roh HK, Chang BC, Park YH, Kang MS, Hong SN, Kim SS. Torsade de Pointes associated with hypomagnesemia after open heart surgery: A report of 2 cases. *Kor J Thorac Cardiovasc Surg* 1992;25(2):188-93.
  - 22) Lee CW, Kim JJ, Song JK, Park SW, Park SJ, Lee SJK. Magnesium sulfate in the treatment of Torsade de Pointes. *Kor Cire J* 1994;24(4):617-23.
  - 23) Doo YC, Hahn TH, Kim DK, Cho BD, Koh SH, Han KR, Oh DJ, Ryu KH, Rim CY, Koh YB, Lee Y. Torsade de Pointes ventricular tachycardia associated with Piprinhydrate (Diphenylpyraline, Plokon®). *Kor Cire J* 1996; 26(1):143-8.
  - 24) Kim SK, Jeon JW, Kim CH, Lee SW, Choi TM, Kwon YJ. Two cases of Torsade de Pointes after astemizole overdose. *Kor Cire J* 1997;26(2):593-7.
  - 25) Choi SH, Cho MJ, Park MJ, Hong JP, Lee SH, Shim WB. A case of Phenothiazine-induced Torsade de Pointes. *Kor J Int Med* 1997;52(1):137-42.
  - 26) Yun SM, Won JY, Kim YD, Jo YH, Heu SH, Lee DH, Lee SM, Jung TH. A case of idiopathic long-QT syndrome. *Kor Cire J* 1997;27(6):658-65.
  - 27) Strasberg B, Kusniec J, Erdman S, Lewin RF, Arditti A, Sclarovsky S, Agmon J. Polymorphous ventricular tachycardia and atrioventricular block. *PACE* 1986;9:522-6.
  - 28) Rosenbaum MB, Acunzo RS. Pseudo 2: 1 atrioventricular block and T wave alternans in the long QT syndrome. *J Am Coll Cardiol* 1991;18:1363-6.
  - 29) Fontaine G. A new look at torsades de pointes. *Ann N Y Acad Sci* 1992;644:157-77.
  - 30) Nurnberg M, Pottler A, Frohner K, Podczeck A, Stellwag C, Steinbach K. Sudden death in pacemaker patients. *J Electrophysiol* 1989;3:477-80.
  - 31) Deboets DC. Les torsades de pointes: Contribution a l'Etude de ce trouble du rythme a propos de 20 cas. *These Paris* 1976.