

Various Appearances of Rib Companion Shadow Mimicking a Pathologic Condition

Yo Won Choi, M.D., Shi Joon Yoo, M.D.*, Jung-Gi Im, M.D.**

Department of Radiology, Armed Forces Chungpyung Hospital.

— Abstract —

We have observed that the companion shadow of the upper rib may be misinterpreted as a small pneumothorax or pleural plaque associated with asbestosis. To observe the radiographic characteristics of the normal companion shadow, we analyzed, on the posteroanterior(PA) chest radiographs, the companion shadow of 50 normal cases. Factors such as occurrence on each rib, the sharpness of the margin, the relative position to the rib, the shape and the thickness were observed. Also, we analyzed the displaced pleura of 4 pneumothorax cases to differentiate their findings from the findings of normal companion shadows. On 50 normal chest radiographs, 192 companion shadows were observed on the first to fourth ribs. In 173 of those shadows, the visceral margin of the companion shadow on the second rib simulated pneumothorax more closely than those on any other ribs due to its apical location and thinness. In six of 50 normal cases, the companion shadow on the first or second rib showed an inwardly convex lower margin, mimicking pleural plaque. The companion shadow was suggested on the plain chest radiograph by the following characteristics (multiplicity(47/50), thicker than normal pleura(3/4), persistent on serial films with the same shape and specific location(4/4).

Index Words: Lung, radiography
Pneumothorax
Thorax, anatomy

INTRODUCTION

When the pneumothorax is very small in amount and apical in position, the diagnosis is suggested on a plain chest radiograph by a thin, smooth, curved and linear density representing the displaced visceral pleura. Above this line, no pulmonary markings are visible.

We have observed that the density of the thin companion shadow on the upper rib is so lucent and its visceral margin appears to be such a sharp line that it may be misinterpreted as pneumothorax. To our knowledge, the fact that the companion shadow may simulate pneumothorax has been reported only in

one article(1). In that article, only passing attention was devoted to it as an example of a Mach band. Furthermore, there has been no detailed description of the radiologic differentiation of the two in any literature. Also, we have noted that the companion shadow may, in some normal cases, show the inwardly convex lower margin mimicking pleural plaque associated with asbestosis.

The purpose of this study is to describe the radiographic characteristics of the companion shadow and, then, to identify it readily on plain chest radiographs without confusion with other pathologic conditions.

* 울산대학교 의과대학 진단방사선과학교실

* *Department of Diagnostic Radiology, College of Medicine, Ulsan University.*

** 서울대학교 의과대학 방사선과학교실

** *Department of Radiology, College of Medicine, Seoul National University.*

이 논문은 1991년 6월 5일 접수하여 1991년 11월 4일에 채택되었음
Received June 5, Accepted November 4, 1991

MATERIALS AND METHODS

We retrospectively reviewed 50 apparently normal PA radiographs of the chest of 33 men (age range, 17-74 years) and 17 women (age range, 14-80 years). There was no evidence of pleural abnormality, apical parenchymal scar, significant mediastinal shift, scoliosis, or asymmetry of the two hemithoraces, any of which could conceivably alter the normal anatomic relationships at the pulmonary apices. Plain chest PA radiographs were obtained in the standard position and projection.

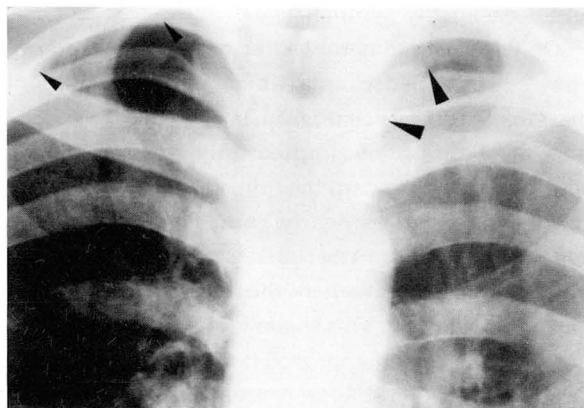
Companion shadows on normal PA chest radiographs were systematically analyzed for the presence on each rib, the sharpness of margin, the relative position, the shape and the thickness. We tried to distinguish the companion shadow from the shadow of the subclavian artery (Fig. 1a)(2,3) or the apical scar(4), either of which may simulate the companion shadow on plain chest radiographs.

We have retrospectively reviewed the PA chest radiographs of four patients (all men aged 21-25 years) with small spontaneous pneumothorax to determine the differences between the internal white line of the companion shadow and the displaced pleura in cases with pneumothorax. In all cases, serial follow-up films, in which pneumothorax was seen, were available and reviewed too. We analyzed the displaced visceral pleura for its shape, thickness, sharpness and relative position to ribs. Also we evaluated the change of its shape or location on follow-up radiographs.

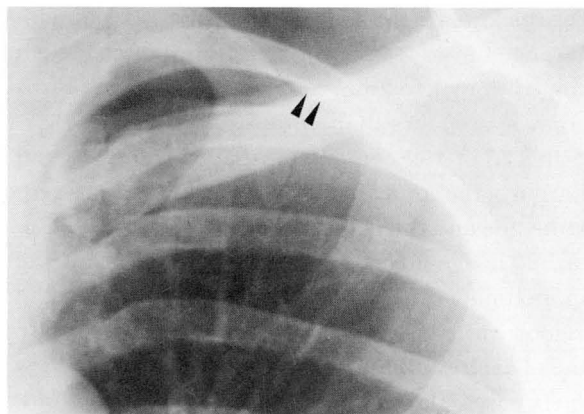
RESULTS

50 Normal cases

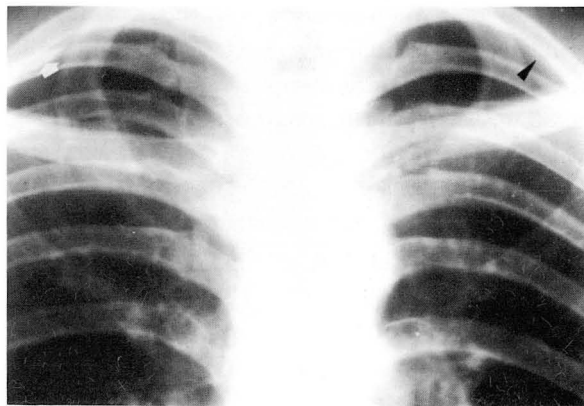
On PA radiographs, companion shadows were observed only on the first to fourth rib and were not notably encountered below the fourth rib. The frequency of the companion shadow on each rib is summarized in the table. The companion shadow is observed on 192 ribs. Forty seven cases (94%) showed the companion shadow on more than one rib. Only a single case showed the shadow on a single rib. Two cases showed no companion shadow on any rib. The shadow was most frequently seen on the second rib



a



b



c

Fig. 1. Companion shadow(a, b, c).

a. Note its typical shape and location on the first and second rib (small arrow heads). The subclavian artery (large arrow heads), with sharp inferior margin, is seen in continuity with the vertical portion of the artery originating from the aortic arch.

b. Particularly on the second rib, its visceral margin looks like a displaced pleura of pneumothorax.

c. Note its inwardly convex lower margin on the second rib mimicking pleural plaque associated with asbestosis (white arrow). Typical companion shadow (arrow head) is seen on the left second rib, mimicking small pneumothorax.

and occasionally symmetrical.

On PA chest radiographs, the companion shadow appeared as a dense area underlying the inferior margin of the upper rib(Fig. 1a, b). The sharp visceral margin of the shadow formed a smooth arc being slightly concave toward the lung field. All visualized companion shadows nearly paralleled the inferior edge of the posterior rib(192/192). It extended often as far as to the point where the rib began to recurve toward the midline. This shadow ended and frequently merged with and appeared never to cross the rib.

The companion shadow was usually thicker at the first rib and was progressively thinner at lower ribs. The thickness of the shadow on the first rib commonly ranged from 2 to 6mm, while on the second rib ranged from 1 to 2mm and at the third and fourth rib measured less than 1mm.

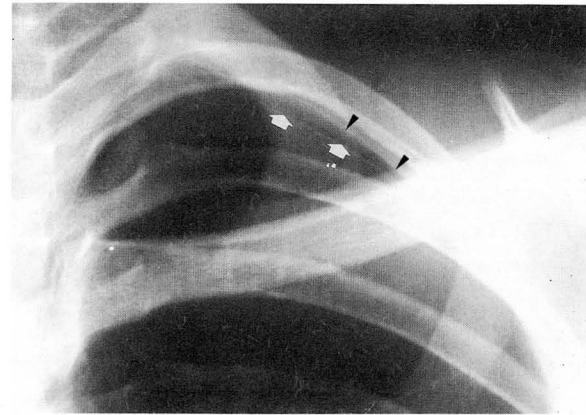
In 173 of 192 companion shadows, the visceral margin of the companion shadow looked like a sharp white line and the outer density was less dense(Fig. 1a, b). Though precise measurement was difficult, the approximate thickness of the visceral margin of the shadow varied from 0.5 to 1mm. The internal white line of each companion shadow is uniformly thick. In six cases, the companion shadow showed an inwardly convex lower margin on a single rib(Fig. 1c).

The companion shadow on the second rib simulated pneumothorax more closely than those on any other ribs due to its apical location and thinness(Fig. 1b). At the level of the first rib, its broader width and outer homogenous soft tissue density readily allowed differentiation from pneumothorax(Fig. 1a). The shadow of the third or fourth rib level occurred, for the most part, only in the axillary segment of each rib, and thus hardly simulate pneumothorax.

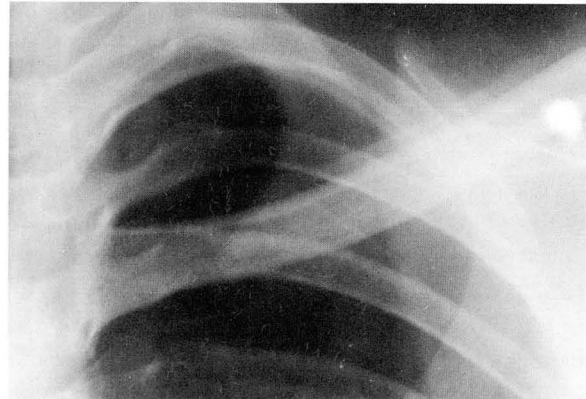
Pneumothorax Cases

Two cases had the pneumothorax in the right hemithorax and the other two in the left. In all cases, companion shadows were similarly well visualized against the background of the air-containing pleural cavity(Fig. 2).

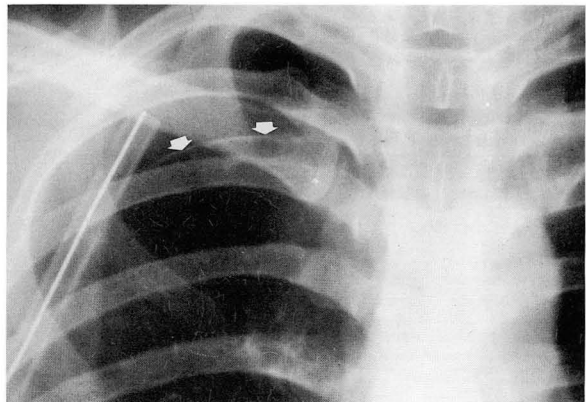
The displaced pleura was a single line(Fig. 2a) and showed changing appearance on follow-up radiographs due to the change of intrapleural air in amount(Fig. 2b). The companion shadows, which were seen in the pleural space, were persistent with



a



b



c

Fig. 2. Cases with pneumothorax(a, b, c)
a. The displaced pleura (arrow) appears as a sharp line and far thinner than the inner margin of the companion shadow(arrow heads) which is well demonstrated against the background of the air-containing pleural cavity.
b. In same case with fig 2a, the displaced pleura changed in its appearance 2 days later due to the change of intrapleural air.
c. Note the unevenly thick and somewhat nodular pleura(arrow) suggestive of apical cap.

Table 1. Frequency of Companion Shadow on 50 Normal Cases

Level of rib	1st Rib			2nd Rib			3rd Rib			4th Rib		
	Rt.	Lt.	Bil.	Rt.	Lt.	Bil.	Rt.	Lt.	Bil.	Rt.	Lt.	Bil.
No. of cases	28	14	12	44	39	36	25	30	20	5	7	2
Percent(%)	56	28	24	88	78	72	50	60	10	10	14	4

Rt. = Right, Lt. = Left, Bil. = Bilateral

the same shape and location in spite of changing appearance of displaced pleura in all cases(Fig. 2). In three cases, the displaced pleura was sharp, smooth, and obviously thinner than the outer companion shadow(Fig. 2a). In a case of pneumothorax, the displaced pleura was unevenly thick and somewhat nodular, suggesting an apical pleural cap or scar(Fig. 2c).

DISCUSSION

Since the companion shadow was first described by Albers-Schönberg(5), various explanations for the anatomy of the companion shadow have been suggested:pleura viewed tangentially(6); connective tissue fascial band corresponding to the fascia of Sibson(7); partial superimposition of the upper bulk of the serratus anterior muscle on the lung apex(8); the heavy subcostal muscles and the connective tissue sheath(9,10); combinations of the shadows of the subcostal and intercostal muscles, the areolar tissue of the endothoracic fascia, and extrapleural fat(11,12). Whatever contributes to the companion shadow, the important thing in this study is that the normal companion shadow may be misinterpreted as significant pathology.

We observed that the companion shadow can be mistaken for the pneumothorax because the visceral margin of the former appears to be a sharp white line mimicking displaced pleura and its outer density looks less dense and, then, mimicking intrapleural air(Fig. 1).

The companion shadow can be readily distinguished from pneumothorax because the displaced pleura appears far thinner than pleura. Even if the pleura is thickened due to chronic pleurisy or the apical cap, it will be unevenly thick as represented in Fig. 2c contrary to the companion shadow, the internal white line of which is uniformly thick. And, thus, it will be readily differentiated. In addition, multiplicity favors

the companion shadow. If confusion persists yet, previously checked roentgenogram or a lateral decubitus film obtained with the involved side up and with full expiration will be helpful, since the companion shadow will not change in its appearance.

The companion shadow often shows inwardly convex visceral margin as Fig. 1c illustrates. To our knowledge, it has not been reported. In this case, it would be reasonable to consider the diagnosis of the companion shadow as well as of pleural plaque although we don't have any comparable cases with asbestosis. Of course, those in the apex alone would favor the companion shadow because pleural plaques are found commonly on the posterolateral thoracic wall and rarely in the apex(11). If that shadow appears in the apex alone in patients belonging to the high risk group of asbestosis, additional oblique views or the CT scans will be helpful to demonstrate, if any, pleural plaques elsewhere. If the shadow persists several years in follow-up radiographs, this finding will also favor the companion shadow. We think this companion shadow is not the pathological apical cap, but a variation of companion shadows based on the description by Jamison(13) and Renner et al(4).

Onik et al(14) reported that hydropneumothorax could be diagnosed on a supine radiograph by recognition of a pleural line with increased density lateral to it in the pleural space. For this reason, the companion shadow can be mistaken for hydropneumothorax on a supine anteroposterior radiograph, although it may appear different from a PA radiograph. When familiarity with the characteristics of the companion shadow is known, the differentiation will be rarely in doubt.

Yoo et al(1) demonstrated that the white stripe along the inner margin of the companion shadow was not a true radiographic density and results from the Mach effect by photodensitometry. This is an example of the Mach effect seen when a concave density (companion shadow) abuts against a more lucent con-

vex area(lung)(15). By covering the silhouette of the lung apex with a piece of white paper, it can be demonstrated that the internal white line of the companion shadow is not present any more.

In conclusion, we have observed that the internal margin of the companion shadow may be seen as such a sharp white line that the companion shadow may be misinterpreted as a small pneumothorax. Also the companion shadow may show the inwardly convex lower margin mimicking pleural plaque associated with asbestosis. The essential features by which the normal companion shadow could be identified as itself are as follows:(1) the white stripe along the visceral margin of the companion shadow seems to be thicker than the normal pleura(2) shadow presence at several rib levels or on both hemithoraces suggests the companion shadow(3) on serial films, persistence of the shadow with a similar appearance suggests the companion shadow(4) the white line of the companion shadow disappears as the silhouette of the lung apex is covered.

REFERENCES

1. 유시준, 정경식, 강홍식, 조병제. 광밀도 계측기를 이용한 Mach band의 분석. 대한방사선학회지 1984; 20: 355-360
2. Gondos B. The roentgen image of the subclavian artery in the pulmonary apex. AJR 1961;86: 1058-1062
3. Poker N, Findy N, Steinberg I. The subclavian arteries: roentgen study in health and disease. AJR

- 1958;80:193-216
4. Renner RR, Markarian B, Pernice NJ, Heitzman ER. The apical cap. Radiology 1974;110:569-573
5. Albers-Schönberg. Die Röntgentechnik. 4th ed. Hamburg: Gräfe & Sillem, 1913:534
6. Rabin CB. Roentgenology of the Chest. Springfield: Thomas, 1958:15
7. Andrus PM. The interpretation of apical linear shadows in roentgenograms of the thorax. Amer Rev Tuberc 1932;25:89-98
8. Gilmartin D. The serratus anterior muscle on chest radiographs. Radiology 1979;131:629-635
9. Knutsson F. zur Kenntnis der normalen Röntgenologie der Pleura Parietalis. Acta radiol 1932;13: 638-677
10. Silverman FC. Caffey's pediatric X-ray diagnosis: An integrated imaging approach. 8th ed. Chicago: Year book medical publishers, 1985:1090-1092
11. Sargent EN, Jacobson G, Gordonson JS. Pleural plaques: a signpost of asbestos dust inhalation. Semin Roentgenol 1977;12:287-297
12. Zawadowski W. Über die Schattenbildungen an der Lungen-Weichteilgrenze. ROEFO 1936;53:306-321
13. Jamison HW. An anatomic-roentgenographic study of the pleural domes and pulmonary apices: with special reference to apical subpleural scars. Radiology 1941;36:302-314
14. Onik G, Goodman PC, Webb WR, Brasch RC. Hydropneumothorax detection on supine rariographs. Radiology 1984;152:31-34
15. Lane EJ, Proto AV, Phillips TW. Mach bands and density perception. Radiology 1976;121:9-17

<국문 요약>

병적인 상태로 보일수 있는 다양한 늑골 동반 음영

국군 청평병원 방사선과, 울산대학교 의과대학 진단방사선과학교실*,

서울대학교 의과대학 진단방사선과학교실**

최요원·유시준*·임정기**

저자들은 흉부 단순 방사선 필름의 폐침부에서 정상적으로 흔히 보이는 늑골 동반 음영(rib companion shadow)이 석면 침착증(asbestosis)으로 인한 늑막 반점(pleural plaque)이나 적은 양의 기흉으로 오진될 수 있는 것을 발견하고, 그런 병적인 상태와 감별될 수 있는 늑골 동반 음영의 특징을 알고자 본 연구를 하였다. 흉부의 단순 후전면(posteroanterior) 촬영상 정상으로 보이는 50명의 환자를 대상으로, 각 늑골에서의 동반 음영의 빈도, 모양, 두께등을 분석 하였고, 늑골 동반 음영과 늑막의 비교를 위해 소량의 기흉이 폐침부에서 보였던 4명의 환자를 대상으로 흉곽 내부로 밀려 들어간 늑막의 모양 두께 등을 분석하였다. 정상인 50명의 흉부 단순 후전면 필름상, 192개의 늑골 동반 음영이 1번부터 4번 늑골에서 관찰되었고 이중 173개에서 폐와의 경계가 하얀 선으로 보여 기흉으로 밀려들어간 늑막과 유사했으며, 특히 2번 늑골 동반 음영은 굉장히 얇고 폐 침부에 위치하여 소량의 기흉으로 가장 오인되기 쉬웠다. 정상인 6명의 경우에서 첫째 혹은 둘째 늑골에 늑골 동반 음영이 흉곽 내부로 돌출되어, 석면 침착증(asbestosis)으로 생기는 늑막 반점(pleural plaque)과 유사하게 보였다. 정상적인 늑골 동반 음영은 양쪽 혹은 여러 늑골에 복수로 존재하며(47/50), 추적 검사상 변화가 없고(4/4), 하얀 선으로 보이는 늑골 동반 음영의 안쪽 경계는 기흉으로 밀려난 늑막보다 훨씬 두껍게 보여(3/4), 병적인 상태와는 감별이 가능하였다.