

## Scintigraphic Demonstration of Peritoneopleural Communication

Heung Suk Seo, M.D.\*, Min Ho Lee, M.D.\*, Sukshin Cho, M.D.\*\*

Department of Radiology, College of Medicine, Hanyang University

<국문초록>

### 복수의 횡격막을 통한 이동

한양대학교 의과대학 방사선과학교실

서 흥 석·이 민 호\*·조 석 신\*\*

복수를 가진 8명의 간경화증 환자 및 Tenckhoff 카테타의 복강내 이식을 받은 한명의 만성 신부전증 환자에 발생한, 호흡곤란을 유발한 수흉이 복수의 횡격막을 통한 이동에 의한 것임을 확인하기 위하여 복강내에  $^{99m}\text{Tc-tin}$  colloid를 주입한 후에 복부와 흉부의 동위원소 주사상을 얻었는데, 모든 환자에서 3분내지 30분후에 흉부에 동위원소의 활동상이 나타나기 시작하여 지속적으로 그 강도가 증가하였다.

따라서 비염증성 복수가 있는 환자들에서 수흉이 발생할 경우 그 원인 규명에 있어 동위원소 주사법이 일차적으로 이용될 수 있는 것으로 생각된다.

**Index Word;** Pleura, Fluid, 66.76

·Ascites, pleural effusion

·Radionuclide imaging,  $^{99m}\text{Tc-tin}$  colloid

### Introduction

There are many diseases which pleural effusion develops without direct extension of the offending

- \* 한양대학교 의과대학 내과학교실
- \* Department of Internal Medicine, College of Medicine, Hanyang University
- \*\* 한양대학교 의과대학 핵의학학교실
- \*\* Department of Nuclear Medicine, College of Medicine, Hanyang University

이 논문은 1989년 7월 20일 접수하여 1989년 8월 19일에 채택되었음

Received July 20, accepted August 19, 1989

organism or cell into the thorax. They are intra-abdominal or retroperitoneal in location and involve the transfer of fluid from below the diaphragm into the pleural space. Pleural involvement from subphrenic inflammation is easy to understand. The effusion is doubtless an extension of the inflammatory process through the interstices of the parietal peritoneum, diaphragm, and parietal pleura. But what about liver cirrhosis, Meigs' syndrome and peritoneal dialysis in which the pleural effusion is constantly associated with ascites and is non-inflammatory?

We present our experience where trans-diaphragmatic migration of peritoneal fluid has been demonstrated in a patient with peritoneal dialysis and eight patients with liver cirrhosis and ascites by scintigraphic study, with brief review of literatures about the possible mechanisms.

### Method and Materials

To prove that pleural effusion was related to ascites, 5 mCi of  $^{99m}\text{Tc}$ -tin colloid was injected into the right lower abdominal cavity, and serial scintigraphic images in anterior view were obtained for 6 hours after injection of the radiopharmaceutical in ten patients.

They included one patient with non-cirrhotic bilateral pleurisy, one with peritoneal dialysis and eight patients with liver cirrhosis and ascites. Of eight cases with liver cirrhosis and ascites, the pleural effusion was right-sided in seven patients and bilateral in one.

Finally, thoracentesis and paracentesis were performed in all patients.

### Result

Scintiscans obtained in the patient with non-cirrhotic bilateral pleurisy showed no radioactivity in the thorax, and pleural effusion was proven to be tuberculous origin on laboratory examination. On the other hand, in the patient with peritoneal dialysis and eight patients with liver cirrhosis and ascites radioactivity appeared and was increased continuously in the thorax, and thoracentesis showed a fluid that had the characteristics of a transudate as did peritoneal fluid.

### Representative Case Reports:

**Case 1:** A 46-year-old woman was admitted for dyspnea and diffuse abdominal pain with duration of two days. She had been previously diagnosed as

having a renal disease, and a diagnosis of CRF was made one month earlier.

On admission, she looked acutely ill, and was afebrile with regular pulse rate of 78/min. and a blood pressure of 120/90 mmHg. Other physical findings and laboratory tests support the diagnosis of chronic renal failure.

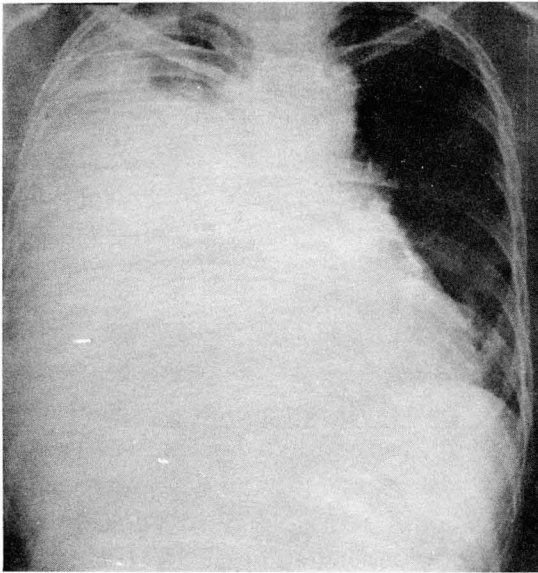
The initial chest radiograph shows streaky and spotty fibrocalcific densities in both upper lung fields suggestive of inactive pulmonary tuberculosis. Tenckhoff catheter was implanted into the peritoneal cavity at operating room under local anesthesia. One day after implantation, the patient complained of breathlessness of acute onset. Subsequent chest radiograph demonstrated a massive right pleural effusion (Fig. 1A). Thoracentesis showed a fluid that had the characteristics of a transudate as did Peritosol<sup>®</sup> (dialysate solution). One day after the thoracentesis of 1300 cc, the right hemithorax was entirely refilled.

To certify that right hydrothorax was due to migration of peritoneal fluid, 5 mCi of  $^{99m}\text{Tc}$ -tin colloid was injected intraperitoneally and scintigraphic images were obtained serially at 3, 5, 10, 15, 20, 25, 30 and 40 minutes after injection of the radiopharmaceutical.

At 3 minute the radioactivity appeared in the right hemithorax, and increased continuously (Fig. 1B). After further thoracentesis and removal of the catheter, a repeat chest radiograph revealed that most of the pleural effusion was no longer present.

The conclusion was drawn that pleural effusion occurred through peritoneo-pleural communication, particularly by way of diaphragmatic defects.

**Case 2:** A 37-year-old man who had liver cirrhosis and ascites was admitted because of general weakness and abdominal distension. Chest radiograph showed homogeneous increased density in the lower half of the right hemithorax, which revealed fluid shift on the right lateral decubitus view.



A

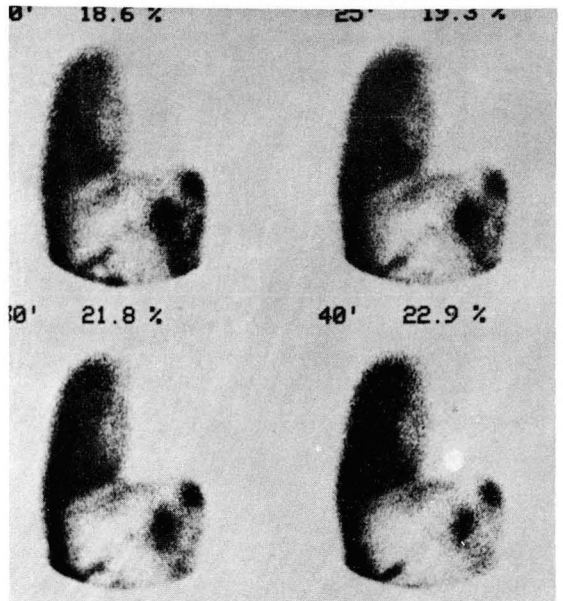
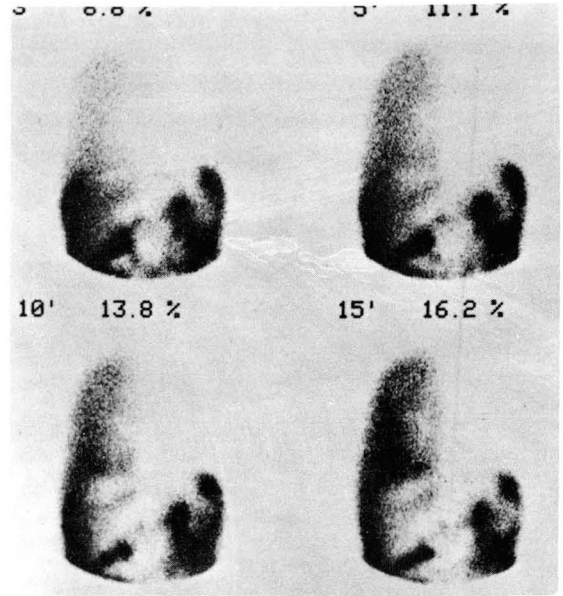
**Fig. 1.** A. Chest PA shows a massive right pleural effusion producing nearly total opacification of the right hemithorax. B. Serial scintigraphic images of abdomen and thorax were obtained after intraperitoneal injection of 5 mCi of  $^{99m}\text{Tc}$ -tin colloid. Migration of radioisotope appears at 3 minute image, and increased continuously.

Scintigrams were obtained serially at 15 minute, 30 minute, 1, 2, and 6 hours after intraabdominal injection of the radioisotope. At 30 minute the radioactivity appeared in the right hemithorax, and increased continuously (Fig. 2). Thoracentesis showed a fluid that had the characteristics of a transudate as did ascites.

**Case 3:** A 44-year-old cirrhotic female had complained of shortness of breathness and abdominal distension. Chest radiograph showed the right subpulmonic effusion and free pleural fluid in the left hemithorax. Scintigrams showed gradually increasing radioactivity in the thorax bilaterally (Fig. 3). Thoracentesis showed a fluid that had the same natures as did ascites.

### Discussion

Since ascites may be associated with pleural



B

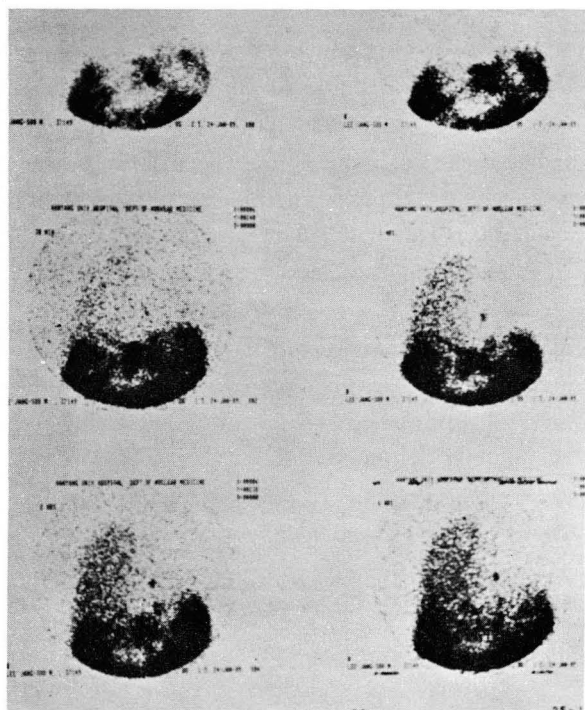
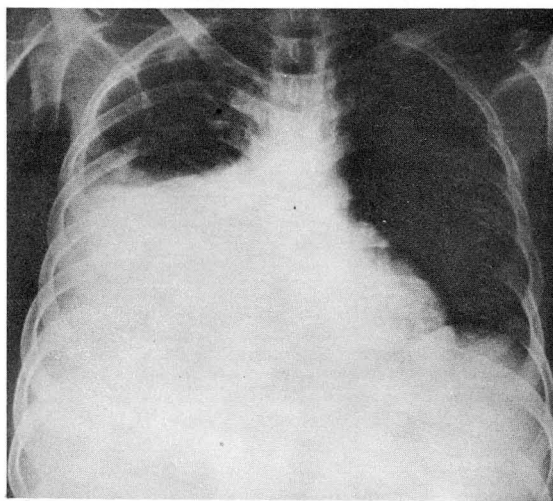
effusion, it might reasonably be anticipated that peritoneal dialysis as well as liver cirrhosis might sometimes lead to hydrothorax. There are at least three possible mechanisms for the development of pleural effusion in patients with liver cirrhosis-hypoproteinemia, azygos hypertension, and transfer of peritoneal fluid to the pleural cavity.

For a variety of reasons neither hypoproteinemia nor azygos hypertension is likely to be a major factor. At least two such cases with peritoneal dialysis have been reported<sup>1-2</sup>). Since such patients are uremic, it may not be possible to distinguish pleural effusion secondary to ascites from that associated with uremia itself. Uremic pleuritis as a sole cause can be excluded because there are many patients who have uremia but never develop pleural effusion, and this can not explain pleural effusion occurring in non-uremic patients and unilaterality. The most probable mechanism proposed in the literatures is that hydrothorax is derived directly from the peritoneal to the pleural space either by way of diaphragmatic lymphatics and in others by way of diaphragmatic defects<sup>2-10</sup>).

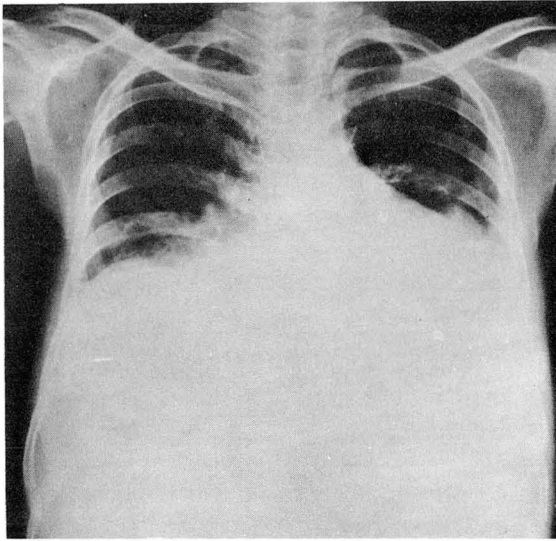
Some authors described lymphatic channels that carry particulate matter from the peritoneum to the thorax and found that those of the right hemidiaphragm are larger and carry more fluid than those of the left. Johnston et al<sup>5</sup>). confirmed these

observations by an experimental work; it was shown that, in the presence of ascites, carbon particles or radioiodinated serum albumin instilled into the peritoneal space passes into the pleural space in a patient with right hydrothorax, and that flow is always from the peritoneum to the pleura and never in the reverse direction. The autopsy showed no gross defect in the right hemidiaphragm.

On the other hand, severe and prolonged distension of the peritoneal sac by fluid or air stretches the diaphragm and its closely attached parietal peritoneum and pleura to such an extent that the fibers pull apart. The widened interstices permit the diaphragm to become microscopically and even grossly permeable to air or fluid<sup>3</sup>). These have been demonstrated either by rapid passage of dye from the ascites into pleural effusion, or induction of hydropneumothorax by intra-abdominal instillation of oxygen<sup>8,9</sup>). Liberman et al<sup>7,8</sup>). have established this hypothesis with the following evidence, based on a study of a group of cirrhotics;

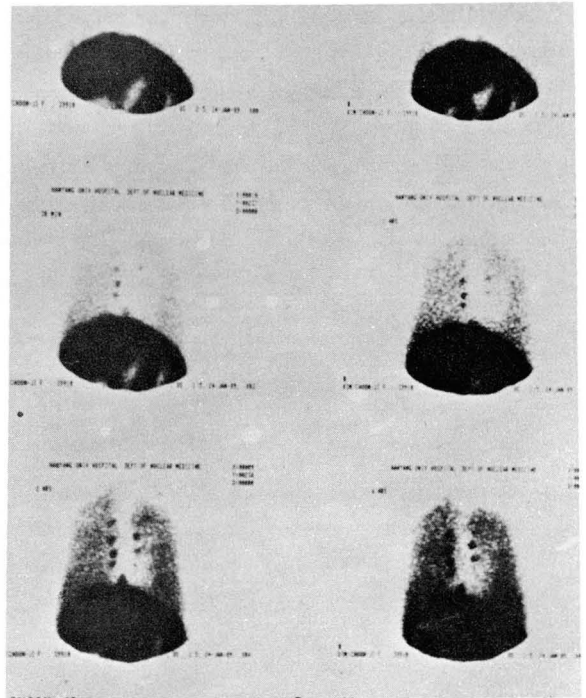


**A**  
**Fig. 2. A.** Chest PA shows homogeneous increased density in the lower half of the right hemithorax. **B.** At 30 minute scintigram the radioactivity appears in the right hemithorax and increased gradually.



**A**

**Fig. 3.** A. Chest PA shows the right subpulmonic effusion and free pleural fluid in the left hemithorax. B. Scintigrams show gradually increasing radioactivity in the thorax bilaterally.



**B**

1.  $^{131}\text{I}$  injected into the ascites appeared in higher concentration in the pleural fluid than in the blood plasma or lymph.

2. Thoracentesis reduced the volume of the ascites.

3. Air (500-1000 cc) injected into the peritoneal sac of the sitting patient appeared in the pleural fluid within 1 to 48 hours.

4. A small opening or leaking blister in the diaphragm was identified at thoracoscopy or autopsy in several of these patients.

5. Separation of collagenous bundles in the tendinous portion of the diaphragm was demonstrated at autopsy in each of the patients.

After all, in some patients fluid transfer from the peritoneal to the pleural space occurs by way of diaphragmatic lymphatics and in others by way of diaphragmatic defects.

To find the source and route of pleural fluid, that is, to prove the migration of fluid from the peritoneal to the pleural space, scintigraphic study

can be done by intraperitoneal injection of radio-pharmaceutical agent such as  $^{99\text{m}}\text{Tc}$ -sulfur or tin colloid or  $^{99\text{m}}\text{Tc}$ -MAA<sup>2,6,9</sup>.

Verreault et al<sup>9</sup>) postulated that there is a relationship between ascites and pleural effusion if radioisotope injected intraperitoneally is mixed with ascites and its migration from peritoneal to pleural space is right sided as is the pleural effusion. And the speed at which the radioisotope migrates from peritoneal to pleural space may be a differential point between the two pathophysiological mechanisms described previously.

If it happens within a few minutes as was seen for our patient<sup>10</sup>), a diaphragmatic defect is probably present, particularly when the accumulation is as intense as peritoneal activity. If it takes a longer period of time as was reported by Verreault et al. migration of ascites fluid may be attributed to diaphragmatic lymphatics particularly when that accumulation is less intense than peritoneal activity.

Conclusively, scintigraphic study can show the source of pleural effusion and can suggest the mechanism of migration of ascites in the patients with liver cirrhosis, Meigs' syndrome, and also in patients with peritoneal dialysis. And thus we can manage the patient properly by coping with possible situations if hydrothorax developed.

## REFERENCES

1. Edwards SR, Unger AM: *Acute hydrothorax—a new complication of peritoneal dialysis*. *JAMA* 199:853-855, 1967
2. Spadaro JJ, Thakur V, Nolph KD: *Technetium-99m-labelled macroaggregated albumin in demonstration of trans-diaphragmatic leakage of dialysate in peritoneal dialysis*. *Am J Nephrol* 2:36-38, 1982
3. Felson B: *Chest Roentgenology*. 446, W.B. Saunders Co., Philadelphia, 1973
4. Fraser RF, Pare JAP: *Diagnosis of Diseases of the Chest*. 2nd Ed Vol 3:1765, W.B. Saunders Co., Philadelphia, 1979
5. Johnston RF, Loc RV: *Hepatic hydrothorax. Studies to determine the source of the fluid and report of thirteen cases*. *Ann Intern Med* 61:385-401, 1964
6. Stanley NN, Williams AJ, Dewar CA, Blendis LM, Reid L: *Hypoxia and hydrothoraces in a case of liver cirrhosis Correlation of physiological, radiographic, scintigraphic, and pathological findings*. *Thorax* 32:457-471, 1977
7. Lieberman FL, Peters RL: *Cirrhotic hydrothorax—further evidence that an acquired diaphragmatic defect is at fault*. *Arch Intern Med* 125:114-117, 1970
8. Lieberman FL, Hidemura R, Peters RL, Reynolds TB: *Pathogenesis and treatment of hydrothorax complicating cirrhosis with ascites*. *Ann Intern Med* 64:341-351, 1966
9. Verreault J, Lepage S, Bisson G, Plante A: *Ascites and right pleural effusion: Demonstration of a peritoneo-pleural communication*. *J Nucl Med* 27:1706-1709, 1986
10. Seo HS, Kang CM, Cho S: *Scintigraphic demonstration of trans-diaphragmatic migration of ascites*. *Korean J Nucl Med* 21:79-82, 1987