

Acute Horseshoe Abscess of the Hand after Local Steroid Injection: A Case Report

**Young Jun Kim, Chang Min Kang,
Hyun Ho Lee, Duke Whan Chung**

*Department of Orthopedic Surgery, Kyung Hee
University Hospital, Kyung Hee University
School of Medicine, Seoul, Korea*

Received: July 17, 2015

Revised: [1] August 28, 2015

[2] September 15, 2015

Accepted: September 21, 2015

Correspondence to: Duke Whan Chung
Department of Orthopedic Surgery, Kyung Hee
University Hospital, Kyung Hee University
School of Medicine, 23 Kyungheedaero-ro,
Dongdaemun-gu, Seoul 02447, Korea

TEL: +82-2-958-8346

FAX: +82-2-964-3865

E-mail: dukech@khmc.or.kr

The differential diagnosis of hand infections is difficult because hand infections can manifest with variable clinical presentations due to the unique anatomic structures of the hand, and the significance of these infections is often overlooked. A horseshoe abscess is a rare type of deep space infection that can occur due to extension of infection through communications between the deep spaces of the hand. Although horseshoe abscesses are well known due to their anatomic characteristics, there are few clinical reports of such occurrences. Such a case has not been reported in the Korean literature. Here we report a case of horseshoe abscess of the hand after local steroid injection.

Keywords: Hand, Infection, Flexor tenosynovitis, Horseshoe abscess

This is an Open Access article distributed under the terms of the Creative Commons Attribution Non-Commercial License (<http://creativecommons.org/licenses/by-nc/3.0/>) which permits unrestricted noncommercial use, distribution, and reproduction in any medium, provided the original work is properly cited.

INTRODUCTION

There are a number of anatomically unique spaces and compartments in the hand. Gaining an understanding of these important structures is essential for accurate diagnosis, management, and prediction of the spread of infection in the hand. Typically, the proximal extent of the sheath in the thumb and little finger is more proximal than the flexor tendon sheaths in the other three fingers. Additionally, these sheaths may communicate with the radial and ulnar

bursae, respectively. The radial and ulnar bursae also communicate with each other at the level of the palm and wrist¹. Tendon sheath infections of the little finger and thumb can track into each other through this communication. This explains the formation of a horseshoe abscess as a rare variant of flexor tenosynovitis in the hand².

Horseshoe abscesses are well known due to their anatomic characteristics. However, there are few clinical reports of such occurrences. Also, such a case has not been reported in the Korean literature. This rare type of infection was

reported to occur after penetrating injury^{3,4}, and common spread of infection was pyogenic flexor tenosynovitis from the radial or less commonly the ulnar bursae². This report describes a horseshoe abscess in the hand after local steroid injection for trigger thumb that was successfully managed with catheter irrigation.

CASE REPORT

A 73-year-old female patient presented to the outpatient clinic with severe pain and swelling in the right hand. The patient had no external wound on the affected hand. She had trigger finger of the thumb and middle finger. She had recently undergone treatment for trigger thumb with three rounds of local steroid injections over the metacarpal neck area of the thumb, but she had not been treated with an injection into the middle finger or elsewhere. The last steroid injection was given three days prior to presentation, and it was administered into the metacarpal neck of the thumb. Following that injection, the patient began to experience

pain and swelling in the thenar area within one day, which subsequently spread to the palm and hypothenar area.

Clinical examination revealed edema of the right thenar area and thumb, hypothenar area and little finger, and palm (Fig. 1). There was heating sensation over the entire hand,

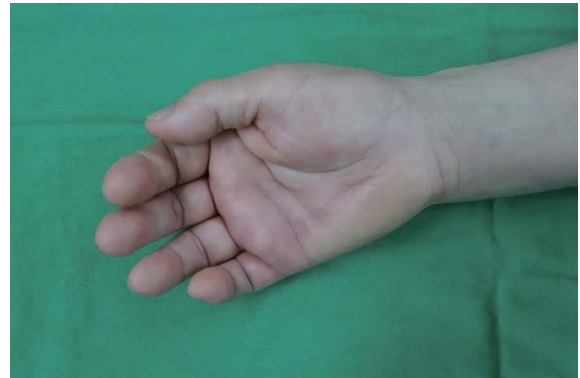

Fig. 1. Preoperative photographs of the right hand. Note the diffuse swelling and erythema of the entire hand including the thenar and hypothenar areas. Swelling was obvious distal to the wrist crease.

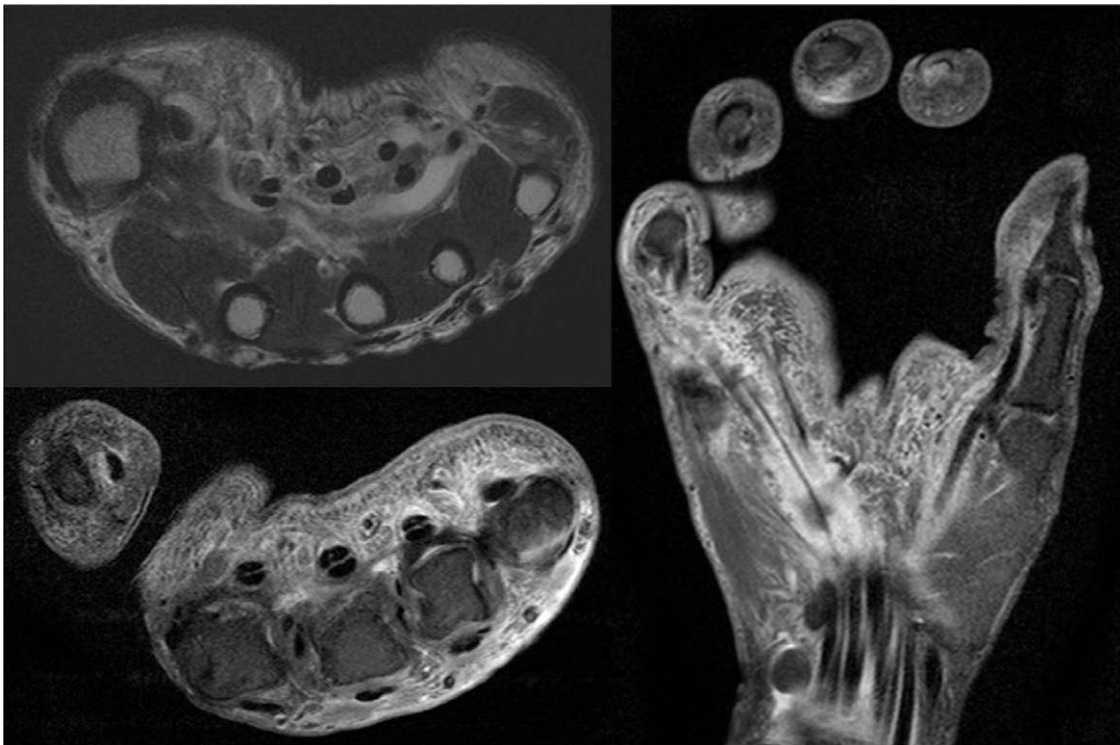


Fig. 2. A contrast-enhanced magnetic resonance image demonstrating fluid collection with distension, and the common flexor tendon sheath, radial and ulnar bursae, and first and fifth flexor tendon sheaths showed diffuse inflammation around the tendon sheaths and adjacent lumbrical muscles.

but her body temperature was normal. Passive extension and palpation of the thumb and little finger caused more severe pain than that of the other fingers. There was no edema or erythema extending into the forearm.

Initial blood test revealed a white blood cell count of $9.28 \times 10^3 \mu\text{L}$ (range, $4.0\text{--}10.0 \times 10^3 \mu\text{L}$), segmented neutrophils: 79.8% (range, 40%–74%), erythrocyte sedimentation rate of 48 mm/hr (range, 0–20 mm/hr), C-reactive protein level of 6.69 mg/dL (range, 0–0.3 mg/dL). Magnetic resonance imaging revealed extensive fluid collection and distension of the common flexor tendon sheath in the palmar carpal area and dorsum of the hand. The flexor tendon sheaths of the thumb and little finger were also involved distally (Fig. 2).

The patient was diagnosed with a horseshoe abscess after local steroid injection into the thumb. It was speculated that tenosynovitis occurred after injection into the thumb and then spread to the little finger through communication of the bursae. The patient was immediately admitted for

urgent surgical drainage with intravenous cefazolin.

Considering the history of triggering of the thumb and middle finger, we planned to release the A1 pulley in addition to closed irrigation using two catheters. The A1 pulleys of the thumb and middle finger were accessed through a limited skin incision over the volar side of each metacarpal head. Another skin incision was made over the volar side of the carpal tunnel to decompress the carpal tunnel and drain the fluid collection. Turbid fluid with solid steroid deposit gushed out of all incision sites (Fig. 3). We incised the transverse carpal ligaments and A1 pulley and performed irrigation. A nested 8F urinary catheter which has multiple side holes throughout the whole length was inserted into the palmar carpal incision and threaded into the bursal tissue and flexor tendon sheath. The catheter was pulled out through the thumb and third metacarpal skin incisions (Fig. 3C). There was outflow of the injected fluid from the distal catheter hole when the irrigation fluid was injected through the proximal hole of the catheter. We also checked the out-

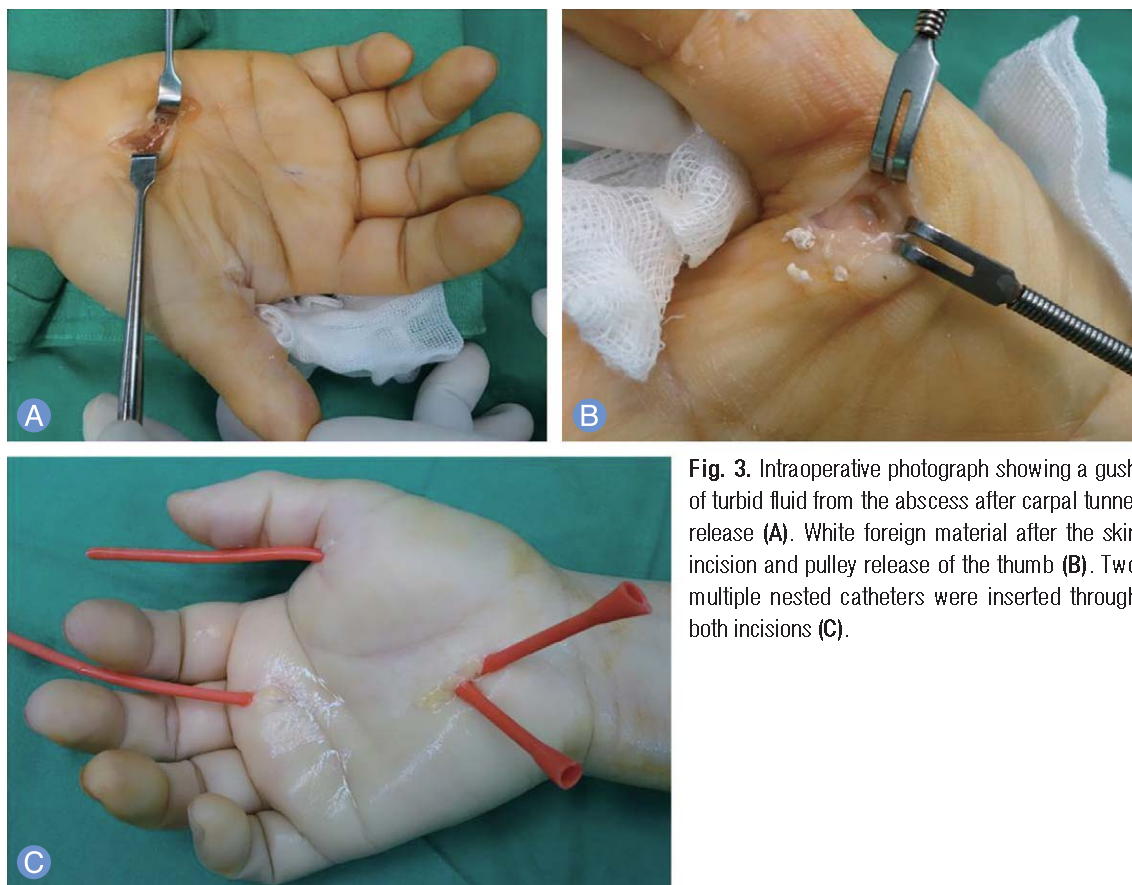

Fig. 3. Intraoperative photograph showing a gush of turbid fluid from the abscess after carpal tunnel release (A). White foreign material after the skin incision and pulley release of the thumb (B). Two multiple nested catheters were inserted through both incisions (C).

flow between soft tissue and outside of the catheter at both the proximal and distal ends.

The patient was allowed immediate range of motion without immobilization. We performed irrigation through the catheter daily (500 mL/day). Minimally pressurized irrigation was performed gently within the acceptable range of patient compliance, along with continuous monitoring of outflow from the distal catheter hole and skin incision site. Intraoperative cultures grew *Staphylococcus aureus* which is sensitive to cefazolin, and we continued to administer intravenous cefazolin while the patient was in the hospital. The catheters were removed gradually after improvement in pain and erythema. The signs of infection in the blood test including leukocytosis and increased C-reactive protein were normalized after 15 days of the operation. We decided to perform complete removal of both catheters after the incision site had dried completely. The patient's clinical course was uneventful, except for residual edema of the little finger. The patient achieved full range of active extension and passive flexion of the affected hand after 8 weeks of surgery (Fig. 4). The last follow up was at 6 months postoperatively, and there was no residual edema and pain.

DISCUSSION

A horseshoe abscess is a rare variant of tenosynovitis of the hand. Although it has been described as a well-known anatomic feature, it has rarely been documented in the lit-

erature^{3,4}.

The flexor tendon sheath of each finger terminates at the bony insertion of the flexor digitorum profundus tendon. Typically, the proximal extent of the sheaths of the index, middle, and ring fingers is just proximal to the A1 pulley. The flexor pollicis longus sheath extends proximally to continue as the radial bursae in most people, while the flexor tendon sheath of the little finger communicates proximally with the ulnar bursae in a more variable proportion of the population¹.

There is considerable variation in the pattern of communication between the flexor tendon sheaths and bursae of the hand. The ulnar bursa surrounds the flexor digitorum profundus tendons and flexor digitorum superficialis tendons of the index, long, and ring fingers, but the bursa is not commonly contiguous with the distal sheaths of these digits^{1,5}. Proximally, the ulnar bursa extends into the palm and it is contiguous with the radial bursa. Anatomical studies have found the presence of a communication in 33%–100% of people^{1,5}. These are the points where the radial and ulnar bursae can communicate with each other^{6,7}. This communication creates the potential for formation of a horseshoe abscess, in which an infection in the small finger tracks into the palm and extends into the thumb, or vice versa. Also, the space of Parona is a potential space located at the level of the distal forearm between the flexor digitorum profundus tendons and the pronator quadratus fascia, and it communicates with the radial and ulnar bursae. The most

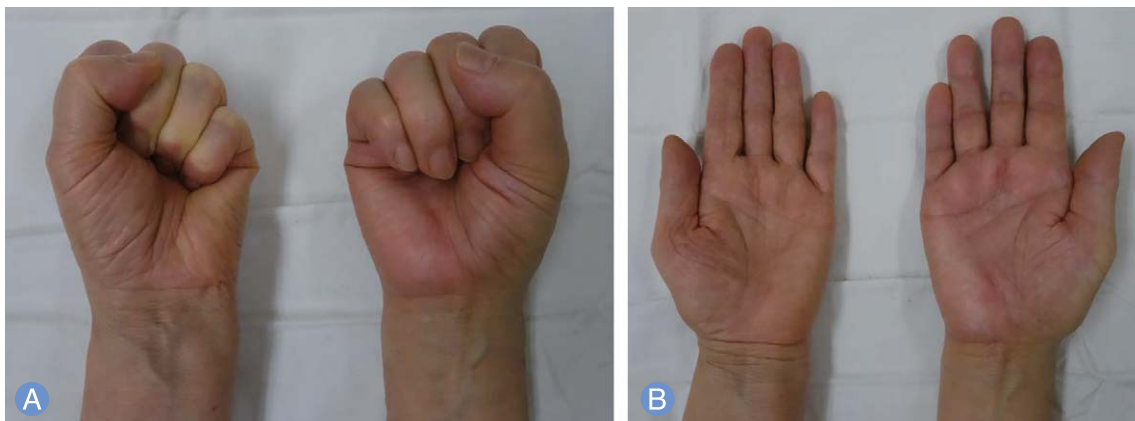


Fig. 4. Photographs at 8 weeks after the operation. Of note, the patient had a pain-free active grip (A) and full extension with a cosmetically acceptable scar (B).

common mechanism of spread of infection is pyogenic flexor tenosynovitis from the radial bursae, or less commonly, the ulnar bursae². These abscesses are associated with poor functional outcomes due to flexor tendon sheath adhesions and destruction of the sheath and pulley system. Elevated compartment pressure can occur, and afterwards it is crucial to check for signs of acute median nerve compression and to promptly perform a decompression procedure³.

The traditional open drainage technique remains the treatment of choice for most advanced cases of pyogenic flexor tenosynovitis and deep space infection. This technique has been used for removal of necrotic tissue through a direct approach, although it can leave a wide incision scar and damage the adjacent soft tissue. Patients are at risk for difficult postoperative rehabilitation and impaired hand function.

Closed catheter irrigation with limited skin incision has several advantages as it avoids the possible complications of neurovascular injury and additional surgical trauma. Limited synovial sheath dissection also preserves the synovial environment, thus reducing adhesion formation and allowing rapid return of function. These advantages have been reported consistently, and they have led to modification of techniques used to treat infective tenosynovitis^{8,9}. The small caliber of the tubes, such as pediatric feeding tubes, allows their easy introduction into the flexor sheath. Hand therapy can therefore be easily implemented in order to reduce adhesion formation and improve long-term mobility. Catheter insertion through the palm area is more convenient than through the digit area as smaller caliber tubes are needed. However, there are possible problems including the dislodgement of the catheter and blockage of the catheter side holes by adjacent soft tissue adhesions, and increased pressure in the sheath⁹. Insertion technique through the confined area of the tendon sheath and verification of the exact position of the catheter are difficult. We recommend proper suturing of the catheter to the skin and securing the catheter to the dressing material to prevent catheter dislodgement, and minimal pressure irrigation is also needed to prevent an increase in sheath pressure. This technique is associated with the possibility of insufficient removal of infected tissues. It must be considered in cases

in which early diagnosis is possible and intraoperative finding of the tendon sheath or bursae is favorable. Close postoperative monitoring is essential to avoid further deterioration. Additionally, we observed late resolution of clinical symptoms in the little finger, and this may be due to insufficient drainage of ulnar bursae because we did not insert the catheter into the little finger.

In the present case, the patient developed symptoms after local steroid injection without any evidence for other clinical causes. Additionally, the patient had no comorbidities. Local steroid injections of the hand are widely accepted as the management for trigger finger, de Quervain's disease, and carpal tunnel syndrome. It is a relatively safe procedure, but there is a risk for devastating complications, including necrotizing fasciitis¹⁰ and suppurative infections. Our report of complications associated with corticosteroid injections is intended to increase awareness among clinicians while performing this simple outpatient procedure.

A horseshoe infection should be suspected in case of pyogenic flexor tenosynovitis showing such a clinical scenario. The knowledge of anatomic relations with spreading pattern is essential for the diagnosis, and prompt surgical management with early mobilization is critical for achieving a better functional outcome.

REFERENCES

1. Fussey JM, Chin KF, Gogi N, Gella S, Deshmukh SC. An anatomic study of flexor tendon sheaths: a cadaveric study. *J Hand Surg Eur Vol.* 2009;34:762-5.
2. Sharma KS, Rao K, Hobson MI. Space of Parona infections: experience in management and outcomes in a regional hand centre. *J Plast Reconstr Aesthet Surg.* 2013;66:968-72.
3. Simon DA, Taylor TL. Horseshoe abscess associated with acute carpal tunnel syndrome: somebody wake up the hand surgeon. *CJEM.* 2012;14:124-7.
4. Fairbairn N. A rare case of communicating infection in the hand: the horseshoe abscess. *Injury Extra.* 2012;43:25-7.
5. Aguiar RO, Gasparetto EL, Escuissato DL, et al. Radial and ulnar bursae of the wrist: cadaveric investigation of regional anatomy with ultrasonographic-guided tenog-

- raphy and MR imaging. *Skeletal Radiol.* 2006;35:828-32.
6. Jamil W, Khan I, Robinson P, Thalava R. Acute compartment syndrome of the forearm secondary to infection within the space of parona. *Orthopedics.* 2011;34:728.
 7. Jebson PJ. Deep subfascial space infections. *Hand Clin.* 1998;14:557-66.
 8. Neviaser RJ. Closed tendon sheath irrigation for pyogenic flexor tenosynovitis. *J Hand Surg Am.* 1978;3:462-6.
 9. Gutowski KA, Ochoa O, Adams WP Jr. Closed-catheter irrigation is as effective as open drainage for treatment of pyogenic flexor tenosynovitis. *Ann Plast Surg.* 2002;49:350-4.
 10. Yam A, Teoh LC, Yong FC. Necrotising fasciitis after corticosteroid injection for trigger finger: a severe complication from a 'safe' procedure. *J Hand Surg Eur Vol.* 2009;34:689-90.

국소 스테로이드 주사 후 발생한 수부의 마제 농양: 증례 보고

김영준 · 강창민 · 이현호 · 정덕환

경희대학교 의과대학 경희의료원 정형외과

수부의 감염은 고유한 해부학적 구조로 인하여 다양한 임상 양상을 나타내게 되며 그 감별에 있어 어려움이 많고 흔히 과소 평가되는 경향이 있다. 마제 농양은 심부 감염의 드문 형태로서 감염이 심부 공간의 교통을 통하여 파급되어 나타나는 것이다. 마제 농양을 일으키는 해부학적 특징에 대하여는 잘 알려져 있으나 임상에서의 보고는 적으며 국내에서의 보고는 없었다. 저자들은 수부의 국소 스테로이드 주사 후 발생한 마제 농양의 증례를 보고하고자 한다.

색인단어: 수부, 감염, 골극 건초염, 마제 농양

접수일 2015년 7월 17일 **수정일** 1차: 2015년 8월 28일, 2차: 2015년 9월 15일

게재확정일 2015년 9월 21일

교신저자 정덕환

서울특별시 동대문구 경희대로 23

경희대학교 의과대학 경희의료원 정형외과

TEL 02-958-8346 **FAX** 02-964-3865

E-mail dukech@khmc.or.kr