



Successful Treatment of Glycine-Receptor-Antibody-Mediated Progressive Encephalomyelitis with Rigidity and Myoclonus by Combining Steroids and Azathioprine

Eung-Joon Lee^a
Kitae Kim^b
Jeong-Yoon Choi^b
Kyung Seok Park^b

^aDepartment of Neurology, Seoul National University Hospital, Seoul National University College of Medicine, Seoul, Korea

^bDepartment of Neurology, Seoul National University Bundang Hospital, Seoul National University College of Medicine, Seongnam, Korea

Dear Editor,

A 40-year-old male presented with hypersomnia, dysphagia, and difficulties in eye opening, voiding, and gait for 2 weeks. His symptoms were gradually progressing from the onset of drowsiness to the full body, and he complained that his limb muscles became rigid. The patient had experienced similar neurological symptoms 8 years previously, but a definitive diagnosis was not made at that time despite an extensive evaluation. It was notable that these previous neurological symptoms have improved over several months without specific treatment. A neurological examination revealed bilateral ptosis (Fig. 1), increased deep tendon reflex in both lower extremities, and spastic gait. However, his horizontal and vertical eye motions and the strength and sensations in all extremities were normal. The findings of serological investigations including infectious condition and thyroid disorder were unremarkable, with negativity for autoantibodies (antinuclear antibody, antiganglioside, acetylcholine receptor, anti-Hu, anti-Yo, anti-Ri, antiampiphysin, anti-Ma2, and antiglutamic acid decarboxylase). A cerebrospinal fluid (CSF) analysis showed a normal white blood cell count (0/mm³) with no red blood cells. The glucose and total protein concentrations in the CSF were 76 mg/dL (blood glucose level: 98 mg/dL) and 46.6 mg/dL, respectively. Repeated nerve conduction studies, ice eye tests, and measurements of acetylcholine receptor antibody also produced normal findings, as did magnetic resonance imaging of the brain and spine. The findings for tumor markers and computed tomography of the chest and abdominopelvic area for suspicion of paraneoplastic disorder were unremarkable.

The patient was diagnosed with an unspecified autoimmune disorder mainly involving the brainstem, and he was further evaluated for anti-glycine-receptor (GlyR) antibodies. The patient's symptoms improved dramatically with the empirical administration of intravenous methylprednisolone at 1 g/day for 5 consecutive days. The symptoms improved completely with further immunomodulatory treatments with 100 mg of oral azathioprine and 40–50 mg of oral prednisolone daily for 2 months. The presence of serum GlyR antibodies (Oxford Neuroimmunology Testing Service, Oxford University Hospitals, Oxford, United Kingdom) was finally confirmed. Based on the clinical presentation and serological test, the patient was finally diagnosed with progressive encephalomyelitis with rigidity and myoclonus (PERM).

PERM is known to have clinical findings similar to stiff-man syndrome, but there are differences due to additional brainstem and autonomic functions.¹ Thus, PERM is also coined as stiff-man-plus syndrome.^{2,3}

GlyR antibodies were first found in a typical PERM patient in 2008.⁴⁻⁶ GlyRs mediate inhibitory neurotransmission mainly in the brainstem and spinal cord, and so GlyR antibodies may disrupt inhibition mechanisms.⁷ We believe that the present report is the first of PERM in a Korean patient and the first in a Korean patient confirmed with GlyR antibodies. The

Received April 19, 2019

Revised June 3, 2019

Accepted June 10, 2019

Correspondence

Kyung Seok Park, MD, PhD
Department of Neurology,
Seoul National University
Bundang Hospital,
Seoul National University
College of Medicine,
82 Gumi-ro 173beon-gil, Bundang-gu,
Seongnam 13620, Korea

Tel +82-31-870-2475

Fax +82-31-870-2826

E-mail parkk@snu.ac.kr

© This is an Open Access article distributed under the terms of the Creative Commons Attribution Non-Commercial License (<https://creativecommons.org/licenses/by-nc/4.0>) which permits unrestricted non-commercial use, distribution, and reproduction in any medium, provided the original work is properly cited.

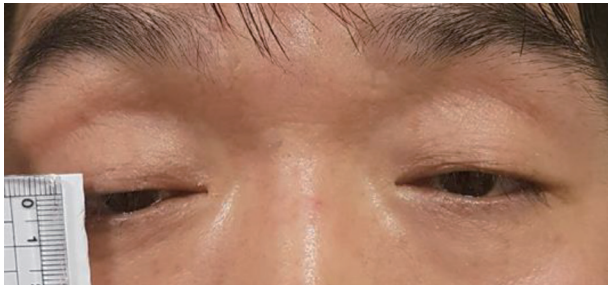


Fig. 1. The patient presented with bilateral eyelid ptosis.

presence of antibodies that bind extracellularly to GlyRs suggest that this is an autoantibody-mediated disease that will respond to immunotherapies.^{8,9} Most cases show improvement with corticosteroids and intravenous immunoglobulin and plasmapheresis, but relapse may occur,¹⁰ and so maintenance immunotherapy may be required. Previous studies have used cyclophosphamide, rituximab, azathioprine, or mycophenolate for ongoing immunotherapy; in our case, azathioprine produced good results. Many clinicians advocate starting immunotherapy immediately upon clinical suspicion, as in the present case. It is therefore important to recognize the clinical features of PERM early, and prompt examination of GlyR antibodies should be performed.

In conclusion, we have reported the first Korean case of PERM that was successfully treated with the combination of steroids and azathioprine. We emphasize that clinicians should be aware of the clinical symptoms of PERM in order to ensure its early diagnosis and treatment.

Author Contributions

Conceptualization: Eung-Joon Lee, Kyung Seok Park. Investigation: Eung-Joon Lee, Kitae Kim. Supervision: Kyung Seok Park. Writing—original draft: Eung-Joon Lee. Writing—review & editing: Jeong-Yoon Choi.

ORCID iDs

Eung-Joon Lee

<https://orcid.org/0000-0002-5326-1111>

Kitae Kim

<https://orcid.org/0000-0002-9862-3569>

Jeong-Yoon Choi

<https://orcid.org/0000-0003-2159-9967>

Kyung Seok Park

<https://orcid.org/0000-0003-1553-5932>

Conflicts of Interest

The authors have no potential conflicts of interest to disclose.

REFERENCES

- Whiteley AM, Swash M, Urich H. Progressive encephalomyelitis with rigidity. *Brain* 1976;99:27-42.
- Brown P, Marsden CD. The stiff man and stiff man plus syndromes. *J Neurol* 1999;246:648-652.
- McKeon A, Robinson MT, McEvoy KM, Matsumoto JY, Lennon VA, Ahlskog JE, et al. Stiff-man syndrome and variants: clinical course, treatments, and outcomes. *Arch Neurol* 2012;69:230-238.
- Hutchinson M, Waters P, McHugh J, Gorman G, O'Riordan S, Connolly S, et al. Progressive encephalomyelitis, rigidity, and myoclonus: a novel glycine receptor antibody. *Neurology* 2008;71:1291-1292.
- Carvajal-Gonzalez A, Leite MI, Waters P, Woodhall M, Coutinho E, Balint B, et al. Glycine receptor antibodies in PERM and related syndromes: characteristics, clinical features and outcomes. *Brain* 2014;137:2178-2192.
- Iizuka T, Leite MI, Lang B, Waters P, Urano Y, Miyakawa S, et al. Glycine receptor antibodies are detected in progressive encephalomyelitis with rigidity and myoclonus (PERM) but not in saccadic oscillations. *J Neurol* 2012;259:1566-1573.
- Crisp SJ, Balint B, Vincent A. Redefining progressive encephalomyelitis with rigidity and myoclonus after the discovery of antibodies to glycine receptors. *Curr Opin Neurol* 2017;30:310-316.
- Ueno S, Miyamoto N, Shimura H, Ueno Y, Watanabe M, Hayashi A, et al. Successful immune moderation treatment for progressive encephalomyelitis with rigidity and myoclonus. *Intern Med* 2015;54:219-221.
- Stern WM, Howard R, Chalmers RM, Woodhall MR, Waters P, Vincent A, et al. Glycine receptor antibody mediated progressive encephalomyelitis with rigidity and myoclonus (PERM): a rare but treatable neurological syndrome. *Pract Neurol* 2014;14:123-127.
- De Blauwe SN, Santens P, Vanopdenbosch LJ. Anti-glycine receptor antibody mediated progressive encephalomyelitis with rigidity and myoclonus associated with breast cancer. *Case Rep Neurol Med* 2013;2013:589154.