

LETTER TO THE EDITOR

Nail Change after Chemotherapy: Simultaneous Development of Beau's Lines and Mees' Lines

In Su Kim, M.D., Jin Woong Lee, M.D., Kui Young Park, M.D., Kapsok Li, M.D., Seong Jun Seo, M.D., Chang Kwun Hong, M.D.

Department of Dermatology, Chung-Ang University College of Medicine, Seoul, Korea

Dear Editor:

The effects of chemotherapeutic agents on rapidly proliferating organs, such as skin, hair, and the gastrointestinal tract are well-known, and clinically manifest as exfoliative dermatitis, alopecia, and diarrhea, respectively. As a "skin" appendage, nails are no exception. For example, cytotoxic chemotherapeutic agents can induce temporary arrest of proliferative function of the nail matrix, which can be clinically observed as Beau's lines in the nail plate^{1,2}.

A 49-year-old male with lung cancer was referred for evaluation of nail changes that had developed on both fingernails and toenails after initiation of chemotherapy with paclitaxel-cisplatin at 3-week intervals. Both nail changes developed at the same time. Physical examination revealed multiple white lines on the nail plates, with regular distance between the lines reflecting chemotherapy cycles of 3-week intervals. With regard to the detailed morphology of the white lines, interestingly, both fingernails and toenails displayed multiple transverse bands of white discoloration and depressions, known as Mees' lines and Beau's lines, which alternately developed on the nail plates (Fig. 1). Both were more prominent on the toenail plates (Fig. 2A). The width of stripes was thicker on the fingernail plate than the toenail plate with

regular intervals. Upon completion of chemotherapy, white transverse lines migrated distally as the nail grew, and no new stripes developed (Fig. 2B). Along with migration of nail growth, all stripes disappeared.

Our patient received combination chemotherapy with paclitaxel-cisplatin. Docetaxel is most frequently responsible for nail matrix damage. Together with docetaxel, paclitaxel forms the drug category of the taxanes. But, it rarely causes side-effects affecting nails, therefore related publications are sparse³. The other component of the chemotherapy was cisplatin, one of the family of drugs called platinum compounds. We have not found any report on similar nail alterations caused by cisplatin.

We now briefly discuss the relationship between Mees' lines and Beau's lines in this case, and the implication of nail changes with respect to the clinical course of chemotherapy. Cytotoxic chemotherapeutic agents can induce temporary arrest of proliferative function of the nail

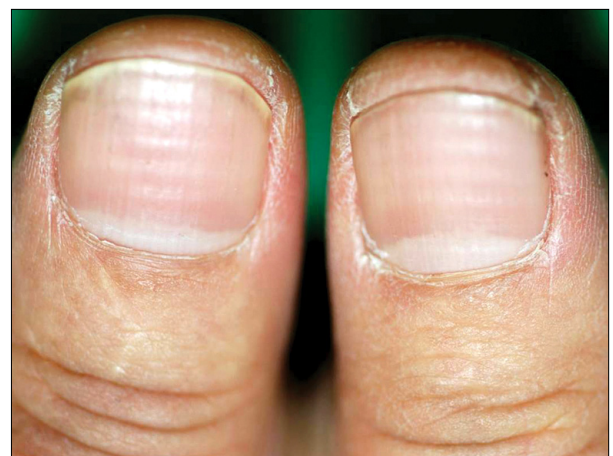


Fig. 1. Both thumbnails showed multiple transverse bands of white discoloration and depressions of the nail plates, which are alternate layers of Mees' lines and Beau's lines.

Received June 20, 2011, Revised August 17, 2011, Accepted for publication August 23, 2011

Corresponding author: Kapsok Li, M.D., Department of Dermatology, Chung-Ang University Hospital, 224-1 Heukseok-dong, Dongjak-gu, Seoul 156-755, Korea. Tel: 82-2-6299-1525, Fax: 82-2-823-1049, E-mail: ksli0209@medimail.co.kr

This is an Open Access article distributed under the terms of the Creative Commons Attribution Non-Commercial License (<http://creativecommons.org/licenses/by-nc/3.0>) which permits unrestricted non-commercial use, distribution, and reproduction in any medium, provided the original work is properly cited.

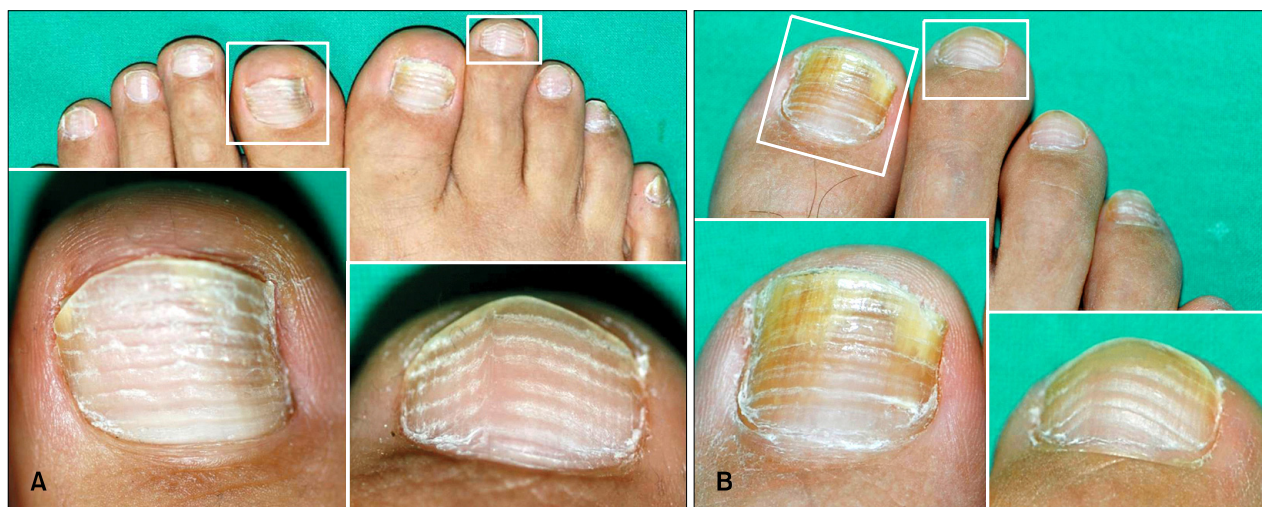

Fig. 2. (A) Both toenails also showed multiple transverse bands, which are alternate layers of Mees' lines and Beau's lines. Both Mees' lines and Beau's lines were more prominent on the toenail plates. (B) After 4 months, he discontinued the chemotherapy and his toenails show a transverse depression that migrates distally as the nail grows.

matrix, which may manifest as multiple Mees' lines or Beau's lines in the nail plate⁴. Mees' lines are signs of toxicity to the distal nail matrix, resulting in parakeratosis of the nail plate, which becomes white and opaque. Drug-induced true leukonychia (Mees' lines) appears as one or several parallel transverse white bands affecting all nails at the same level and moving distally with nail growth⁵. Beau's lines are typical signs of acute toxicity to the nail matrix with transient arrest in nail plate production. The nail shows a transverse depression that migrates distally as the nail grows⁵.

Both are signs of toxicity to the nail matrix. What was the difference between fingernails and toenails with leukonychia in this case? We hypothesize that the difference of proliferative potential between fingernails and toenails leads to different clinical manifestations. A fingernail takes approximately 40 days to emerge from the proximal nail fold and a toenail approximately 80 days⁵; therefore, we suppose that the proliferative potential of a fingernail is higher than that of a toenail. In general, organs of rapid mitotic activity are damaged more severely from chemotherapy in much the same way fingernails are more vulnerable to anticancer drugs than toenails. Interestingly, in our patient, rapidly proliferating fingernails were less affected by chemotherapeutic nail matrix damage; consequently, less severe depression and less opaque Mees' lines manifested. In general, slowly proliferating toenails are seriously affected, and these show definitive Beau's lines and more opaque Mees' lines. The depth of the depression indicates the degree of the damage, and the width indicates the duration of the insult⁶. Different

mechanisms lead to different nail changes. A decrease in matrix cell proliferation can lead to Beau's lines, which are associated with temporary cessation of nail growth according to cycles of chemotherapy at 3-week intervals. As a result of proliferative function turnaround, disorganized keratinization of the nail matrix results in parakeratosis of the nail plate, which becomes white and opaque, known as Mees' lines⁷.

Beau's line or Mees' line can sometimes be one of the first symptoms after chemotherapy; however, to the best of our knowledge, development of Beau's lines in patients with Mees' line has not previously been reported.

REFERENCES

1. Chen GY, Chen W, Huang WT. Single transverse apparent leukonychia caused by 5-fluorouracil plus leucovorin. *Dermatology* 2003;207:86-87.
2. Miyoshi I, Kubota T, Taguchi H. Beau's lines after chemotherapy for ALL. *Intern Med* 2007;46:61.
3. Lehoczky O, Pulay T. Transverse leukonychia secondary to paclitaxel-carboplatin chemotherapy in a patient with ovarian cancer. *J Obstet Gynaecol* 2002;22:694.
4. Naumann R, Wozel G. Transverse leukonychia following chemotherapy in a patient with Hodgkin's disease. *Eur J Dermatol* 2000;10:392-394.
5. Piraccini BM, Iorizzo M, Tosti A. Drug-induced nail abnormalities. *Am J Clin Dermatol* 2003;4:31-37.
6. Piraccini BM, Iorizzo M, Starace M, Tosti A. Drug-induced nail diseases. *Dermatol Clin* 2006;24:387-391.
7. Parakh A, Kocchar AM. Chemotherapy induced transverse leukonychia (Mees lines). *Indian Pediatr* 2007;44:865.