

CASE REPORT

An Unusual Case of Congenital Dermal Melanocytosis

Sanghoon Lee, M.D., Dae-Hyun Kim, M.D., Gunhong Lee, M.D., Kyu-Uang Whang, M.D.,
Jong Suk Lee, M.D., Young-Lip Park, M.D.

Department of Dermatology, College of Medicine, Soonchunhyang University, Seoul, Korea

Dermal melanocytosis is characterized by the presence of ectopic melanocytes in the dermis. The most common forms include the Mongolian spot, blue nevus, nevus of Ota, and nevus of Ito. Some types of dermal melanocytosis do not fit into any of these morphologic categories, however. Our case demonstrated an extensive amount of uniform deep blue patches of nevi with unilateral distribution on the left face, neck, chest, shoulder, and back. On histopathologic examination, a number of elongated melanocytes scattered throughout the dermis were found. We herein report a case of congenital unilateral dermal melanocytosis. (*Ann Dermatol* 22(4) 460~462, 2010)

-Keyword-

Congenital unilateral dermal melanocytosis

INTRODUCTION

Dermal melanocytosis is characterized by the presence of ectopic melanocytes in the dermis. The most common forms include the Mongolian spot, blue nevus, nevus of Ota, and nevus of Ito. Some cases of dermal melanocytosis do not fit into any of these morphologic categories, however. Dermal melanocytosis rarely occurs in unusual regions or covers extensive areas of the body¹. Atypical types of dermal melanocytosis reported in the literature include dermal melanocyte hamartoma and congenital segmental dermal melanocytosis^{2,3}.

We herein report the clinical and histological features of an unusual case of congenital dermal melanocytosis.

Received December 7, 2009, Revised February 12, 2010, Accepted for publication February 12, 2010

Corresponding author: Young-Lip Park, M.D., Department of Dermatology, College of Medicine, Soonchunhyang University, 1174 Jung-dong, Bucheon 420-767, Korea. Tel: 82-32-621-5452, Fax: 82-32-621-5018, E-mail: ylpark@schmc.ac.kr

CASE REPORT

A 21-month-old Korean girl presented with an asymptomatic pigmented patch on her left face, neck, chest, shoulder, and back that had been present since birth. The pigmented patch had grown proportionately to the patient's size throughout her life; otherwise, there had been no appreciable change in its color or texture. The patient had no family history of pigment disorders, and her physical and mental development was normal. On physical examination, the patient had an extensive amount of uniform deep blue patches that covered the left side of her face, neck, chest, shoulder, and back in a unilateral pattern, with a few dark blue-brown macules in the lesions. There were also scattered satellite lesions of a similar appearance on her backbone area (Fig. 1). The epidermal surface was unaltered, and no underlying induration was clinically apparent. Except for the skin lesions, there were no remarkable findings on physical examination. There was no discoloration or other abnormality on ophthalmologic examination.

A biopsy specimen from a lesion on the patient's back demonstrated a number of elongated melanocytes located throughout the dermis. Melanocytes were numerous in the upper and middle dermis. Immunohistochemical analysis showed that melanocytes and melanin were positive for S-100 and Fontana-Masson stains, but cells were negative for CD68, which can be a marker for melanophages. Melanocytes were scattered among the collagen bundles, and some of these cells were aggregated around blood vessels. Their elongated cytoplasm were loaded with fine melanin (Fig. 2). Nevus cell nests were not seen in the epidermis or dermis. Appendages were normal.

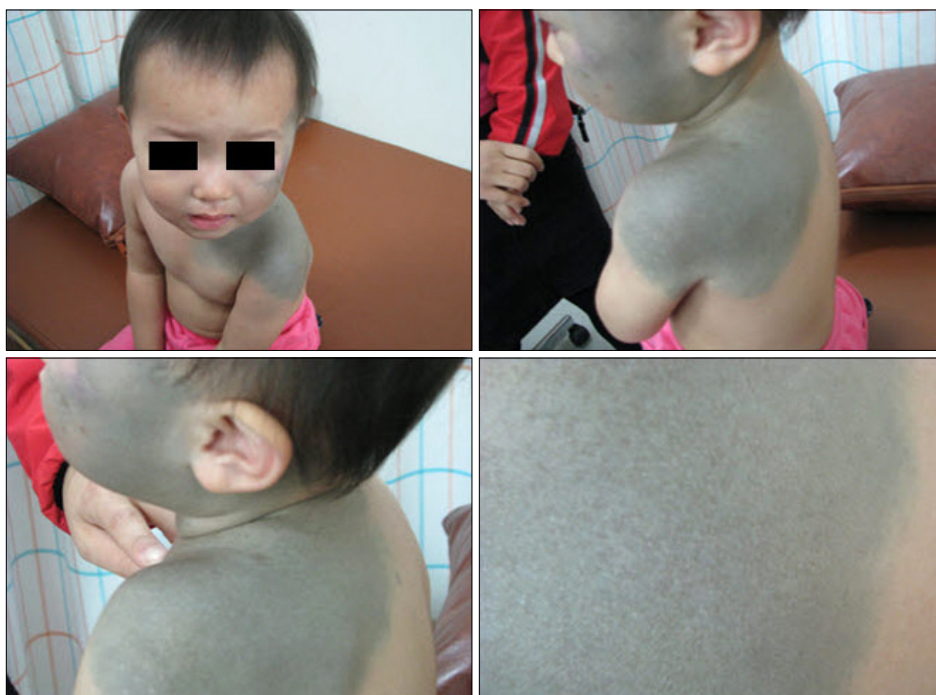

Fig. 1. An extensive amount of uniform deep blue patches were seen to cover the left unilateral side of the face, neck, chest, shoulder, and back.

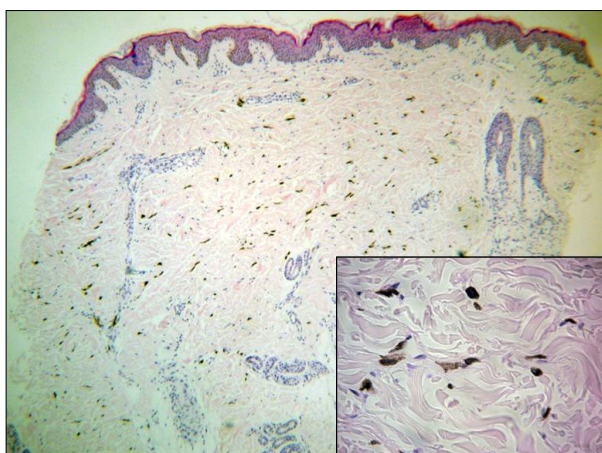


Fig. 2. Melanocytes were numerous in the upper and middle dermis. Melanocytes were scattered among the collagen bundles, and some of these cells were aggregated around the blood vessels. Their elongated cytoplasm were loaded with fine melanin. Melanophages were not seen (H&E, $\times 40$, inset $\times 400$).

DISCUSSION

Except for blue nevi, the various types of dermal melanocytosis are similar in their histopathologic characteristics; they just differ in the concentration and location of the melanocytes. The characteristics they share include elongated dermal melanocytes that are widely scattered between collagen fibers in the dermis. These melanocytes do not alter the normal topography of the skin³.

In our case, the skin lesion involved the face and acromioclavicular region, respectively sites for the nevus of Ota and the nevus of Ito, but our patient's lesion extensively covered the chin and neck with no involvement of the eye. In nevi of Ota and Ito, the melanocytes are mainly situated in the upper dermis, and the basal layer of the epidermis may be hyperpigmented. However, in our case, melanocytes were also found in the middle and lower dermis.

Typical Mongolian spots occur in the sacrococcygeal region as pale-blue to slate-gray macular hyperpigmentation. Occasionally, however, they occur outside the lumbosacral region on places such as the middle or upper part of the back as aberrant Mongolian spots. Histopathologically, the melanocytes of Mongolian spots predominantly reside in the lower portions of the dermis. These features are clinically and histopathologically different from our case.

The blue nevus usually presents as a well-demarcated, blue-black papule, nodule or plaque that is generally acquired. Histologic features of the blue nevus include a high concentration of dermal melanocytes in the middle and lower third of the dermis. Melanophages and variable degrees of fibrosis are present. These features are different from our case.

A few cases of unusual congenital dermal melanocytosis have been documented (Table 1). In 1981, Bashiti et al.¹ reported a female infant with generalized blue-gray discoloration of the skin. In the same year, Burkhart and Gohara² described an 18-month-old male with diffuse,

Table 1. Less common variants of congenital dermal melanocytosis

	Distribution	Morphology	Course
Bashiti et al. ¹ (1981)	Generalized except for the face, palms, soles, genital area, and nipples were spread	Blue-gray pigmentation	Decreased substantially
Burkhardt and Gohara ² (1981)	Buttocks bilaterally and right leg in a dermatomal pattern	Gray-blue patch with several conspicuous macules in the lesion	No tendency to resolution in the first 18 months of life
Vélez et al. ³ (1992)	Right aspect of the trunk in a segmental distribution with several thoracic dermatomes affected	Mottled gray-blue pigmentation heterogeneous in color, with numerous maculae of darker hue	Persistent
Grézard et al. ⁴ (1999)	In a dermatomal distribution on the two sides of the back from the fourth to the eighth dorsal dermatome and extended laterally on the external part of breasts	Gray-blue pigmentation	Slowly spreading
Present case	Left unilateral aspect of face, neck, chest, shoulder, and back in a segmental pattern with scattered satellite lesions on the back-bone area	Uniform, deep blue patches with a few dark blue-brown macules in the lesion	No tendency to resolution in the first 21 months of life

bilateral gray-blue pigmentation on his buttocks that extended in a dermatomal pattern down the entire length of his right leg. They used the term “dermal melanocyte hamartoma” to describe this phenomenon. In 1992, Vélez et al.³ documented the case of a 28-year-old white woman with extensive, speckled, gray-blue pigmentation in a segmental pattern on the right side of her trunk. They proposed the term “congenital segmental dermal melanocytosis” to describe the findings. In 1999, Grézard et al.⁴ reported a 45-year-old Caucasian woman with a slowly spreading bilateral congenital pigmentation of the back in a dermatomal distribution from the fourth to the eighth dorsal dermatome that extended laterally to the external part of the breasts.

Several authors have also documented cases of isolated small patch forms of congenital dermal melanocytosis⁵⁻⁷. The pathogenesis of congenital dermal melanocytosis is not well understood. It is believed that during embryogenesis, dermal melanocytes migrate from the neural crest to their designated site at the epidermal-dermal junction. Dermal melanocytosis occurs when the melanocytes fail to properly reach that designated site⁸.

Our case has some similarities to those of Burkhardt and Gohara² and Vélez et al.³, but the unilateral distribution and melanocytes throughout the dermis did not fit into any of the cases that have been reported. As a result, we propose the term, “congenital unilateral dermal melano-

cytosis,” to name the lesion on our patient.

We herein report a case of congenital unilateral dermal melanocytosis.

REFERENCES

1. Bashiti HM, Blair JD, Triska RA, Keller L. Generalized dermal melanocytosis. *Arch Dermatol* 1981;117:791-793.
2. Burkhardt CG, Gohara A. Dermal melanocyte hamartoma. A distinctive new form of dermal melanocytosis. *Arch Dermatol* 1981;117:102-104.
3. Vélez A, Fuente C, Belinchón I, Martín N, Furió V, Sánchez Yus E. Congenital segmental dermal melanocytosis in an adult. *Arch Dermatol* 1992;128:521-525.
4. Grézard P, Berard F, Balme B, Perrot H. Congenital bilateral dermal melanocytosis with a dermatomal pattern. *Dermatology* 1999;198:105-106.
5. Krishnan RS, Roark TR, Hsu S. Isolated patch of speckled, congenital, pigmented dermal melanocytosis outside the face or acromioclavicular regions. *J Eur Acad Dermatol Venereol* 2003;17:238-239.
6. Kim S, Kim JA, Kim WS, Lee JH, Yang JM. Congenital dermal melanocytosis confined to the palm. *J Eur Acad Dermatol Venereol* 2007;21:1116-1117.
7. Kim S, Park JH, Kim JA, Lee JH, Yang JM, Lee ES, et al. Congenital combined dermal and epidermal melanocytosis: a new entity? *J Eur Acad Dermatol Venereol* 2007;21:1282-1283.
8. Stanford DG, Georgouras KE. Dermal melanocytosis: a clinical spectrum. *Australas J Dermatol* 1996;37:19-25.