

## Saddle Nose Deformity as a Result of an Aseptic Nasal Abscess Accompanied by Ulcerative Colitis and Pyoderma Gangrenosum

Jinsoon Chang, MD, PhD

*Department of Otolaryngology-Head and Neck Surgery, Inje University Seoul Paik Hospital, Seoul, Korea*

Ulcerative colitis (UC) is a chronic inflammatory bowel disease (IBD) that causes granulomatous inflammation in the mucous membrane of the intestinal tract, especially in the colon. Additionally, UC can be accompanied by extraintestinal manifestation (EIM). EIM of UC includes cutaneous lesions such as pyoderma gangrenosum, and rarely, systemically occurring aseptic abscesses (AA) have been reported in a few cases. Nasal involvement of UC as an extraintestinal manifestation of IBD is rare, and few reports of nasal mucosa and septal cartilage involvement have been documented in the literature. However, aseptic nasal abscess involving septal cartilage associated with UC and pyoderma gangrenosum resulting in saddle nose deformity have not been reported. The author presents a case of a 52 year-old woman with UC and pyoderma gangrenosum and an aseptic abscess in the nasal septal cartilage resulting in saddle nose deformity, which was corrected by augmentation rhinoplasty.

**KEY WORDS:** Saddle nose deformity · Aseptic abscess · Ulcerative colitis · Pyoderma gangrenosum.

### INTRODUCTION

Ulcerative colitis is a chronic idiopathic inflammatory disorder of the bowel (IBD). Besides the intestinal tract, this disease sometimes has been associated with extraintestinal manifestation. It is known to cause cutaneous manifestations such as pyoderma gangrenosum and more rarely, aseptic abscess in the body. Nasal manifestations are even rarer and, only a few cases have been reported to date in the literature. However, aseptic nasal abscess involving septal cartilage associated with ulcerative colitis and pyoderma gangrenosum resulting in saddle nose deformity has not yet been reported in the literature. The author herein presents an unusual case of a 52 year-old woman who suffered from ulcerative colitis and pyoderma gangrenosum and subsequently, developed an aseptic abscess in the nasal septal cartilage causing saddle nose deformity.

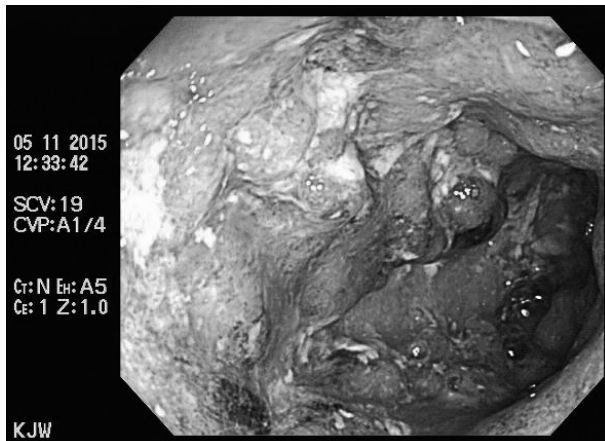
### CASE REPORT

A 52 year-old female patient was hospitalized due to recurrent bloody diarrhea and abdominal pain. Four weeks prior to admission, she had skin necrosis in her right ankle. She also developed bilateral nasal obstruction and complained of change in her nose shape recently. All these symptoms and signs occurred simultaneously and the colonoscopic examination showed mucosanguineous exudates and spontaneous bleeding from the ulcerative lesion in the edematous mucous membrane of the colon (Fig. 1). Histopathologic findings were consistent with ulcerative colitis but an immunohistologic result revealed negative ANCA. Another biopsy was performed on the extensive ulcerative lesion in the right ankle and diagnosed pyoderma gangrenosum (Fig. 2). Nasal endoscopic examination showed that septal mucosa remained intact but with severe bulging, which looked highly suspicious of abscess. The bulging

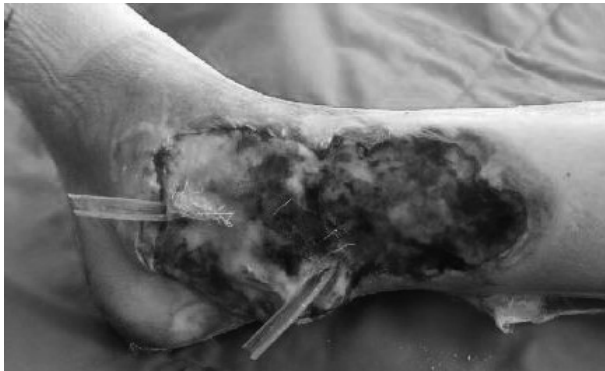**Received:** April 18, 2018 / **Revised:** May 8, 2018 / **Accepted:** May 14, 2018

**Address for correspondence:** Jinsoon Chang, MD, PhD, Department of Otolaryngology-Head and Neck Surgery, Inje University Seoul Paik Hospital, Marunae-ro 9 Choong-gu, Seoul 04551, Korea

Tel: +82-2-2270-0558, Fax: +82-2-2270-0073, E-mail: [jsc4g@paik.ac.kr](mailto:jsc4g@paik.ac.kr)

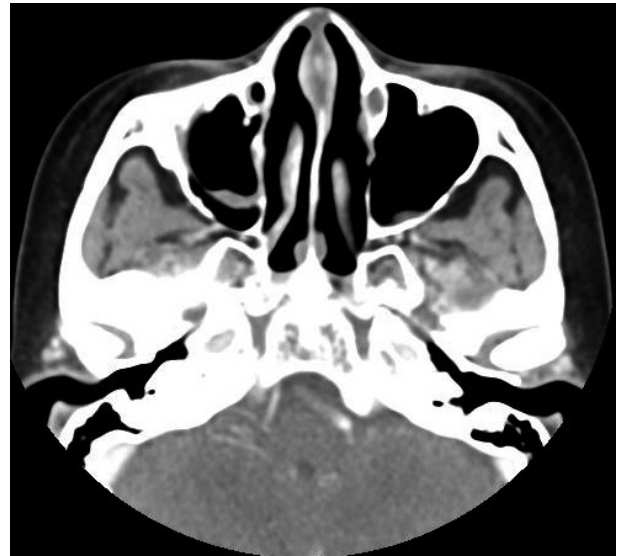


**Fig. 1.** Colonoscopy shows severe mucosanguineous exudates and spontaneous bleeding from the ulcerative lesion in the edematous mucous membrane of the colon with relative rectal sparing.

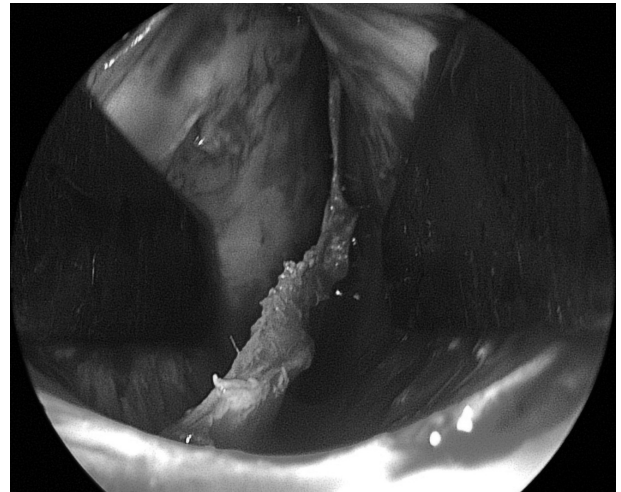

**Fig. 2.** Pyoderma gangrenosum on the right leg.

mucosa was aspirated and seromucoid aspirate sent for bacterial culture. Bacteria was not identified from the culture. A paranasal sinus CT scan was performed (Fig. 3). Upon examination of the septum deep to mucosa, the majority of septal cartilage was missing due to necrosis, leaving only normal looking cartilage in front of the perpendicular plate of ethmoid and vomer (Fig. 4). The biopsy on the margin of missing septal cartilage was done to determine whether the saddle nose was caused by direct cartilaginous involvement of ulcerative colitis. However, it revealed that there were no signs of granulomatous inflammation. The patient was diagnosed with ulcerative colitis based only on her clinical symptoms and colonoscopic findings. Pyoderma gangrenosum in the leg skin was suspected as an extraintestinal manifestation of ulcerative colitis and that saddle nose deformity resulted from an aseptic nasal septal abscess. Therefore, the patient was placed on corticosteroid therapy and infliximab, a tumor necrosis factor (TNF) antibody. Her nasal dorsum was intermittently observed during the course



**Fig. 3.** Contrast enhanced paranasal sinuses computed tomography (CT). There was no residual abscess other than mild edema of the nasal septum in the axial image.

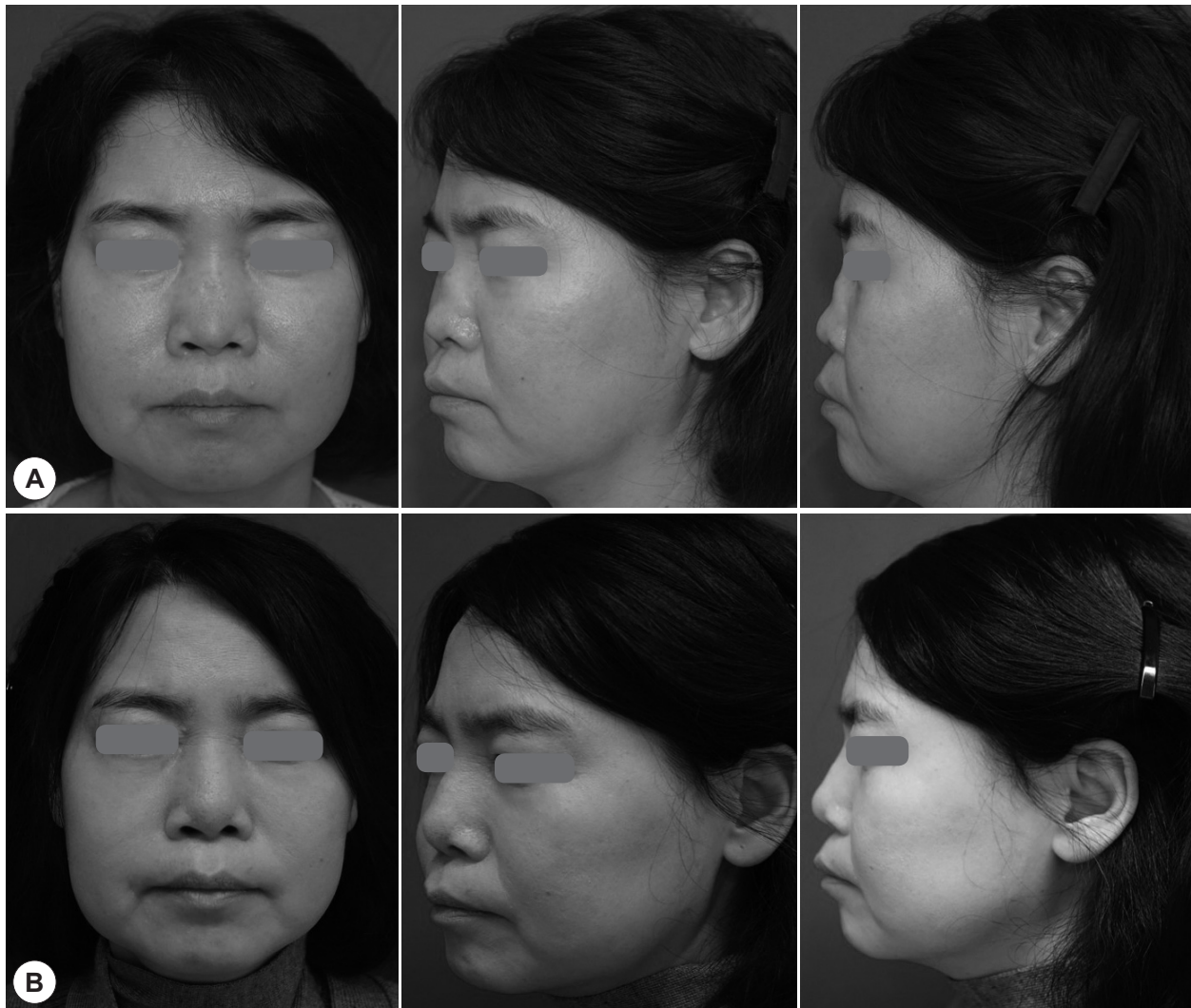

**Fig. 4.** Nasal endoscopic finding showed missing septal cartilage. There was small amount of remaining cartilage in the perpendicular plate inside the intact septal mucosa.

of medical treatment to determine whether there was any further deformity of her nose. When it was confirmed that there was no further change in her nose in seven months, augmentation rhinoplasty using Tutoplast<sup>®</sup> Fascia lata allograft was done. The patient was then followed up for a year after surgery and there was no evidence of recurrence in the nose inside and out.

## DISCUSSION

Ulcerative colitis is a chronic granulomatous inflamma-



**Fig. 5.** The Frontal, three-quarter, and lateral views of a 52 year-old woman with ulcerative colitis. A: The saddle nose deformity due to middle vault collapse. B: The saddle nose deformity corrected through augmentation rhinoplasty.

tory process confined to the large bowel and, is a type of inflammatory bowel disease (IBD). Symptoms of IBD outside the gastrointestinal system however are common and well documented. In more than one-third of IBD patients, extraintestinal manifestation (EIM) can involve skin, liver, lung, bone and the kidney.<sup>1)</sup> During the last few years many authors have reported serious complications of IBD manifesting in the ear-nose-throat (ENT).<sup>2)</sup> The cutaneous manifestation usually presents as either erythema nodosum and/or pyoderma gangrenosum. It is believed, however, there is no consistent relationship between pyoderma gangrenosum and that of ulcerative colitis regarding disease course.<sup>3)</sup> The present case exhibited pyoderma gangrenosum with a clinical course paralleling that of UC exacerbation. The nasal involvement in IBD, particularly limited to

nasal septum as in this case seems extremely rare but nasal septal perforation<sup>4)</sup> and saddle nose deformity<sup>5)</sup> have been reported. However, these manifestations are more common in Crohn's disease than in ulcerative colitis. The aseptic abscess (AA) may also occur in all parts of the body as an extraintestinal manifestation of inflammatory bowel disease (IBD-AA). AA has been documented as an EIM and can be found before, during, and after the diagnosis of IBD.<sup>6)</sup> This may indicate a need to perform colonoscopy on a patient with AA because IBD can be diagnosed concomitant with or following AA. With respect to IBD type, incidence of Crohn's disease is higher compared to UC-associated AA. However, it is important to realize that AA as an EIM occurs regardless of the type of underlying IBD. Diagnosis of AA is usually made at the time of exacerbation of ulcer-

ative colitis as in this case. The diagnostic criteria for identifying nasal lesion caused by ulcerative colitis has not yet been established, making it difficult to determine the causal relationship. Several reports have demonstrated that granulomatous tissue with abundant neutrophils can be regarded as a characteristic feature,<sup>8,9)</sup> but in this case, biopsy of the cartilage could not determine causal relationship because the tissue area needed to be taken for the test was missing, leaving only healthy normal cartilage behind. Although the diagnostic criteria for AA has not clearly been established, several common characteristic features were well identified. First, an aseptic abscess is a deep abscess with predominantly neutrophilic infiltration. Secondly, it is associated with negative serologic and hematologic test for bacteria and fungi as well as culture test by aspiration. Thirdly, it fails to be treated by broad spectrum antibiotics including anti-tuberculosis therapy. Lastly, occurrence of prompt clinical improvement on corticosteroid therapy with or without additional immunosuppressant therapy and subsequent radiologic evidence of abscess resolution.<sup>7)</sup> In the present case, the causal relationship between ulcerative colitis and intranasal symptoms could not be confirmed by histological examination. However, in light of the fact that the bacterial culture of the nasal septum was negative and the deterioration of symptoms resolved after the immunosuppressive treatment, we believe aseptic abscess in the septal cartilage caused nasal septal necrosis, which eventually led to the saddle nose deformity in this patient. After confirming that medication resolved the symptom such as pyoderma gangrenosum and there was an absence of exacerbation of saddle nose deformity, an augmentation rhinoplasty was performed with excellent results. Finally, it should be important

to keep in mind that the possibility of aseptic nasal abscess involving septal cartilage causing the saddle nose can present as an extraintestinal manifestation of ulcerative colitis. This report highlights the importance of considering nasal involvement of extraintestinal manifestation of ulcerative colitis and that diagnosis and treatment of ulcerative colitis should be initiated promptly and thoroughly in order to prevent complications like in this case.

## REFERENCES

- 1) Vavricka SR, Schoepfer A, Scharl M, Lakatos PL, Navarini A, Rogler G. Extraintestinal Manifestations of Inflammatory Bowel Disease. *Inflamm Bowel Dis* 2015;21(8):1982-92.
- 2) Zois CD, Katsanos KH, Tsianos EV. Ear-nose-throat manifestations in Inflammatory Bowel Diseases. *Ann gastroenterol* 2007;20(4):265-74.
- 3) Powell FC, Schroeter AL, Su WP, Perry HO. Pyoderma gangrenosum: a review of 86 patient. *Q J Med* 1985;55(217):173-86.
- 4) Krikovich MD, Kelly SM, Jackson WD. Nasal septal perforation: rare extraintestinal manifestation of Crohn's disease. *Ear Nose Throat* 2000;79:520-3.
- 5) Merkonidis C, Verma S, Salam MA. Saddle nose deformity in a patient with Crohn's disease. *J Laryngol Otol* 2005;119:573-6.
- 6) Andre MF, Piette JC, Kemery JL, Ninet J, Jégo P, Delevaux I et al. Aseptic abscesses: a study of 30 patients with or without inflammatory bowel disease and review of the literature. *Medicine* 2007;86:145-61.
- 7) Bollegala N, Khan N, Scaffidi MA, Al-Mazroui A, Tessolini J, Showler A, et al. Aseptic Abscess and inflammatory bowel disease: Two cases and Review of Literature. *Can J Gastroenterol Hepatol* 2017;2017:5124354.
- 8) Yilmaz B, Yusel O, Coban S, Cakmak I, Basar O, Ekiz F. Rare Complication of Ulcerative Colitis: Aseptic Nasal Septal Abscess. *Inflamm Bowel Dis* 2011;17(7):E71.
- 9) Goral V. Rare and New Extraintestinal Complication of Ulcerative Colitis: Nasal Septal Perforation. *Inflamm Bowel Dis* 2012;18(2):E397-8.