

## Case Report

# Total hip replacement in a dog

Nam-Soo Kim<sup>1,\*</sup>, Md. Rafiqul Alam<sup>1</sup>, In-Seong Jeong<sup>2</sup>, Jong-Il Lee<sup>1</sup>, In-Hyuk Choi<sup>1</sup>

<sup>1</sup>Department of Surgery and Radiology, College of Veterinary Medicine, Chonbuk National University, Jeonju 561-756, Korea

<sup>2</sup>Royal Animal Medical Center, Seoul 131-878, Korea

**An intact male German shepherd dog (4 y, body wt. 35.5 kg) was referred to the Animal Medical Center, Chonbuk National University with severe lameness, pain and gait abnormality on the right hind limb. Survey radiographs of the pelvis revealed dysplasia of the right coxofemoral joint with subluxation. The dog was surgically treated performing total hip replacement (THR) using Modular Biolox Canine Modular THR System. The dog began to bear weight and slowly returned to a normal exercise pattern 2 months after surgery. THR resulted in satisfactory clinical functions with 6 months follow up and no complications were observed. Canine modular THR could be a successful modality for the management of disabling conditions of the coxofemoral joint.**

**Key words:** dog, subluxation, total hip replacement

Canine total hip replacement (THR) has become well established as an effective method for the treatment of disabling conditions of the hip [6,12]. It is the treatment of choice for re-establishing normal, pain-free limb function and joint mechanics in dogs with hip dysplasia and associated osteoarthritis, chronic luxation, fractures, failed femoral head and neck excision, and avascular necrosis of the femoral head [1,2,8]. The Richards Canine II THR was the first clinically available hip prosthesis for dogs [13]. Now-a-days Modular Biolox Canine Modular THR System (Osteonics, USA) has become available. The Modular Biolox Total Hip prosthesis consists of three components- a femoral stem, femoral head, and acetabulum. The femoral stem and femoral head are made of cobalt chrome stainless steel or titanium metal alloy and the acetabulum is made of ultra high molecular weight polyethylene. Polymethyl methacrylate is used to cement and hold these implants in place [4]. The purpose of this report is to represent the surgical technique, complications and final functional outcome of THR in a dog.

A four-year-old (body wt. 35.5 kg) intact male German shepherd dog was referred to the Animal Medical Center, Chonbuk National University with severe lameness, pain and gait abnormality on the right hind limb. Physical, hematobiochemical and radiological examinations were performed. The pulse, respiration and body temperature were normal. The blood sample was submitted to a complete blood count (CBC) and chemistry screening (CS), but no hematological or biochemical abnormalities were found. Survey radiographs of the pelvis revealed dysplasia of the right coxofemoral joint with subluxation (Fig. 1). The reported specific criteria (clinical signs, radiographic findings, age, size, and overall health condition) for selecting a dog for THR were supportive in our patient [9-11]. The diagnosis was made as unilateral (right) hip dysplasia with subluxation.

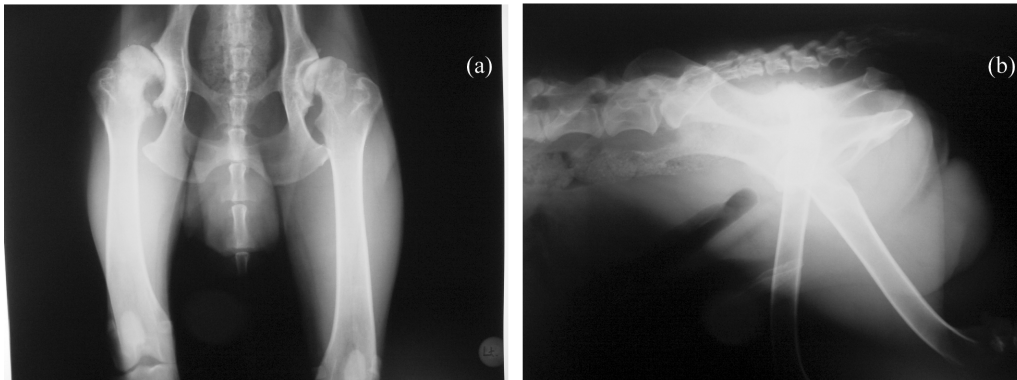
The dog was premedicated with atropine sulphate (Huons, Korea) 0.05 mg/kg, SC and induction of anesthesia was performed using thiopentone sodium (Daehan Pharmaceutical, Korea) 25 mg/kg, IV. Anesthesia was maintained with enflurane and oxygen delivered through a cuffed endotracheal tube. Supportive fluid therapy was maintained throughout the procedure and cephalothin sodium (Kyngebo Pharmaceutical, Korea) 25 mg/kg, IV was administered at the time of induction. The dog was positioned on left lateral recumbency. The surgery was performed following the technique reported by Olmstead *et al.* in 1981 [7]. Osteotomy of the femoral neck was performed using a power saw in a plane to correspond to the collar on the femoral stem and in a neutral anteversion. The femur was then retracted caudally and the middle gluteal muscle was reflected dorsally to expose the acetabulum. The acetabulum was reamed to a depth of its medial wall with an acetabular reamer. Four holes (5 mm) were made with drill bits in the acetabular bed to place polymethyl methacrylate to anchor the acetabular cup. The acetabular component was tested for proper fit (Fig. 2). The femoral canal was opened with a drill bit, reamed with a femoral reamer, and shaped with a femoral rasp to allow unrestricted seating of the appropriate sized femoral stem into the marrow cavity (Fig. 3).

The acetabular bed was re-exposed and thoroughly cleaned. The polymethyl methacrylate cement mixture was

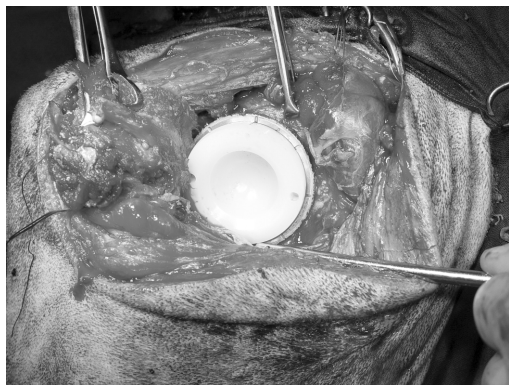\*Corresponding author

Tel: +82-63-270-2800, Fax: +82-63-270-3778

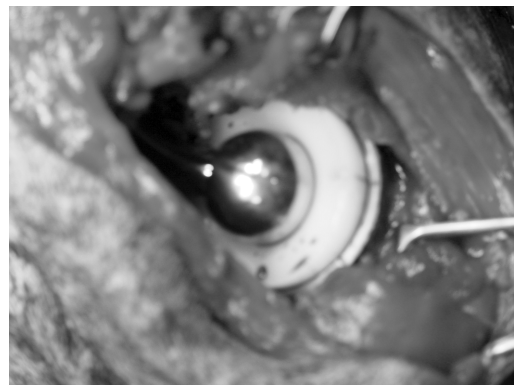
E-mail: namsoo@chonbuk.ac.kr



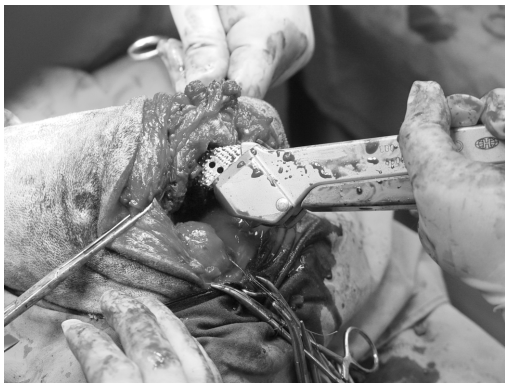**Fig. 1.** Ventrodorsal (a) and lateral (b) radiographs of the pelvis revealed dysplasia and subluxation of the right coxofemoral joint.



**Fig. 2.** A test implantation of the acetabular cup.



**Fig. 4.** Photograph of the coxofemoral joint after implantation of the artificial prosthesis.



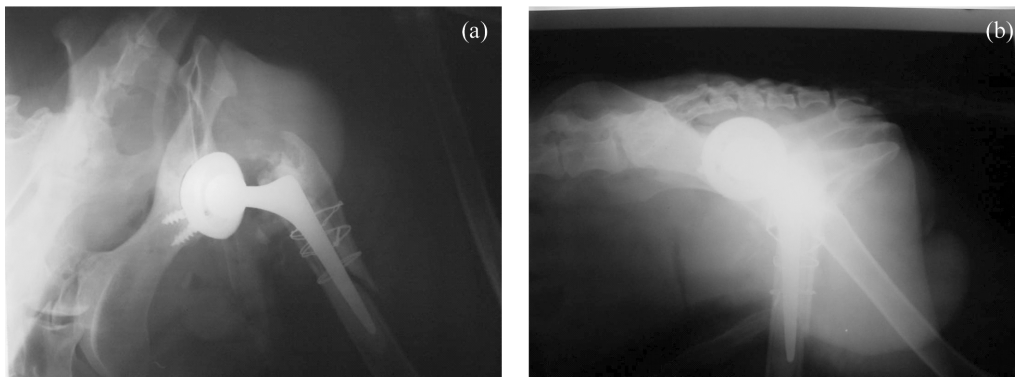
**Fig. 3.** Reaming of the femoral canal.

prepared and when it reached a doughy state, it was thumb packed into the acetabular bed filling the anchor holes and lining the surface. The acetabular cup was then seated and held in place with an acetabular positioner until the cement became polymerized and hardened. The trial endoprosthesis was inserted into the femoral shaft, and a test reduction was performed and it was seemed to be proper fit. The trial endoprosthesis was removed. The femoral canal was then flushed with saline solution and a suction tube was placed. The polymethyl methacrylate cement mixture was injected

into the medullary canal. When the canal became filled the tube was removed, the femoral stem was inserted until the collar rested on the bone, and held in position until the cement became hardened. Then the head of the endoprosthesis was reduced into the acetabular component (Fig. 4). The joint capsule was securely closed in an overlapping pattern. The muscles, subcutaneous tissues and skin were closed in a routine manner.

Postoperative care consisted of limiting the degree of exercise by compartmental confinement for the first week followed by 3 weeks of very limited activity on a leash and continual restriction at cage. After the first operative month exercise was gradually increased. The out side activity was allowed only on a leash with no running, jumping or playing and minimal use of restrain. Postoperative oral cephalixin therapy (Youngil Pharmaceutical, Korea, 25 mg/kg, qid) was continued for 1 week.

Physical, radiographic examinations and medical history were used in pre- and post-operative patient evaluation. Immediately after surgery, radiographs of the hip (Figs. 5a and b) were taken to evaluate the position of the prosthesis and how completely the cement filled the area. The radiographs revealed a well polymerization and appropriate placement of the prosthesis. The optimal angle of the hip



**Fig. 5.** Ventrodorsal (a) and lateral (b) radiographs of the pelvis taken immediately after THR.

joint following THR appeared to be 135°. For evaluating the function of THR, orthopedic and radiographic examinations of the hip were performed at every 2 weeks for 3 months. The dog began to bear weight with a normal range of motion in the hip and slowly returned to a normal exercise pattern 2 months after the implantation of the prosthesis.

THR becomes one of the most successful procedures performed today, with predictably excellent and reproducible results [3]. The minimum age 10 months and body weight 35 pounds reported to be suitable for THR in the dog [10,13]. There is no upper age or size limit for THR. Dogs as old as 14 years have had successful THR [9]. In our patient, the age, size, signalment and outcomes were in consistent with the previous reports [9-11]. In this patient, we used modular prosthesis which is better than the fixed-head prosthesis [11]. A minimum period of 4 weeks after the surgical correction is reported to be adequate for evaluating the function of THR [8]. In our case, however, we followed up for 12 weeks for the evaluation of the functional outcome of the THR. Complications associated with THR include luxation, aseptic loosening, sciatic neurapraxia, infection, femur fracture, patellar luxation, pulmonary embolism etc [4,5,6]. The reported complication rate for THR was 8.7% for dislocation, 7.7% for infection of all origin, 3.2% for fracture and noninfected loose acetabular cups, and 2.2% for sciatic neuroapraxia [8]. However, in our patient THR resulted in satisfactory clinical functions and no complications were observed during 6-month follow up period. The dog began to bear weight with a normal range of motion in the hip and slowly returned to a normal exercise pattern. The findings of this study suggest that canine modular THR could be a successful treatment modality for the management of disabling conditions of the coxofemoral joint and could provide a pain-free normal function for the joint.

### Acknowledgments

This work was supported by the Korea Science and

Engineering Foundation Grant (No. P01-2004-000-10459-0).

### References

1. **Bergh MS, Muir P, Markel MD, Manley PA.** Femoral bone adaptation to stable long-term cemented total hip arthroplasty in dogs. *Vet Surg* 2004, **33**, 214-220.
2. **Bergh MS, Muir P, Markel MD, Manley PA.** Femoral bone adaptation to unstable long-term cemented total hip arthroplasty in dogs. *Vet Surg* 2004, **33**, 238-245.
3. **Chung WK, Liu D, Foo LSS.** Mini-incision total hip replacement-surgical technique and early results. *J Orthop Surg* 2004, **12**, 19-24.
4. **Konde LJ, Olmstead ML, Hohn RB.** Radiographic evaluation of total hip replacement in the dog. *Vet Radiol* 1982, **20**, 98-106.
5. **Liska WD.** Femur fractures associated with canine total hip replacement. *Vet Surg* 2004, **33**, 164-172.
6. **Montgomery RD, Milton JL, Pernel R, Aberman HM.** Total hip arthroplasty for treatment of canine hip dysplasia. *Vet Clin North Am Small Anim Pract* 1992, **22**, 703-719.
7. **Olmstead ML, Hohn BH, Turner TM.** Technique for canine total hip replacement. *Vet Surg* 1981, **10**, 44-50.
8. **Olmstead ML, Hohn BH, Turner TM.** A five-year study of 221 total hip replacement in the dog. *J Am Vet Med Assoc* 1983, **183**, 1991-1994.
9. **Olmstead ML.** Total hip replacement in the dog. *Semin Vet Med Surg (Small Anim)* 1987, **2**, 131-140.
10. **Olmstead ML.** Total hip replacement. *Vet Clin North Am Small Anim Pract* 1987, **17**, 943-955.
11. **Olmstead ML.** The canine cemented modular total hip prosthesis. *J Am Anim Hosp Assoc* 1995, **31**, 109-124.
12. **Olmstead ML.** Canine cemented total hip replacement: State of the art. *J Small Anim Pract* 1995, **36**, 395-399.
13. **Tomlinson J, McLaughlin RJr.** Total hip replacement: The best treatment for dysplastic dogs with osteoarthritis. *Symposium on CHD: Surgical Management. Vet Med* 1996, **91**, 118-124.