

Overview of Surgical Scar Prevention and Management

Daegu Son¹ and Aram Harijan²

¹Department of Plastic and Reconstructive Surgery, Keimyung University School of Medicine, Daegu; ²Well Plastic Surgery Clinic, Seoul, Korea

Received: 22 November 2013
Accepted: 9 April 2014

Address for Correspondence:

Daegu Son, MD
Department of Plastic and Reconstructive Surgery, Keimyung University School of Medicine, 56 Dalseong-ro, Jung-gu, Daegu 700-712, Korea
Tel: +82.53-250-7636, Fax: +82.53-255-0632
E-mail: handson@dsmc.or.kr

Management of incisional scar is intimately connected to stages of wound healing. The management of an elective surgery patient begins with a thorough informed consent process in which the patient is made aware of personal and clinical circumstances that cannot be modified, such as age, ethnicity, and previous history of hypertrophic scars. In scar prevention, the single most important modifiable factor is wound tension during the proliferative and remodeling phases, and this is determined by the choice of incision design. Traditional incisions most often follow relaxed skin tension lines, but no such lines exist in high surface tension areas. If such incisions are unavoidable, the patient must be informed of this ahead of time. The management of a surgical incision does not end when the sutures are removed. Surgical scar care should be continued for one year. Patient participation is paramount in obtaining the optimal outcome. Postoperative visits should screen for signs of scar hypertrophy and has a dual purpose of continued patient education and reinforcement of proper care. Early intervention is a key to control hyperplastic response. Hypertrophic scars that do not improve by 6 months are keloids and should be managed aggressively with intralesional steroid injections and alternate modalities.

Keywords: Skin Tension Line; Skin Wound Healing; Cicatrix, Hypertrophic; Keloid; Surgical Wound

INTRODUCTION

Advanced understanding of stem cell lineages, biomolecular signaling cascades, cellular responses, and wound healing kinetics has shed much insight into the mechanism of wound healing. Significant findings in basic science research have been translated into clinical applications. Notable examples are biologic acellular matrices, negative pressure wound therapy, and bioabsorbable polymer products.

For most physicians and patients, however, clinical management of wounds continues to lag behind decades-old research. The plethora of ineffective commercial product (miracle scar creams, for instance) confuses and misleads patients, while the tsunami of basic science text amount to an indigestible intellectual burden for busy clinicians. The opinion of the authors is that a sixteen-page chapter out of general surgery textbook from the 1980s still contains 90% of the clinically relevant information found across multiple chapters in a contemporary multi-volume plastic surgery textbook.

This article was prepared in an attempt to re-iterate the time-honored traditions of wound healing management and to clarify the most up-to-date rationale for these traditions. We review the wound healing processes and discuss how these processes, especially the remodeling phase, relate to prevention and management of unsightly surgical scars.

SCAR FORMATION

Wound healing

The generic model of wound healing can be divided into three main processes: inflammation, proliferation, and remodeling. Inflammation commences with disruptions in capillary blood vessels and induction of hemostatic cascade. The leaked intravascular contents form fibrin clots, which are composed of fibrin mesh and platelets. This provisional extracellular matrix (ECM) in the wound paves the way for migration of various cells that participate in the wound healing process.

The second stage in wound healing is proliferation, which begins around day 4 or 5 with the migration of fibroblasts into the wound matrix. By 2 to 4 weeks, the fibroblasts are maximally up-regulated and replace the fibrin with a more robust matrix of collagen fibers. In the mature wound, the initial elastic fiber network is no longer observed and explains the firmness and absence of elasticity of scars (1). Another important aspect of the proliferative phase is the inward epithelialization of keratinocytes from the wound margin. Wound contraction begins around day 10 to 12, but this timing can vary with wound severity and general conditions of the patient (2).

The third and last stage in wound healing is the remodeling phase, which usually begins 3 weeks after tissue injury. Microscopic findings of this stage include decreases in fibroblast count, occlusion of blood vessels, and hardening of collagen fibers.

Continuous collagen production and degradation has an effect of remodeling the mature wound matrix for approximately 6 months post injury. At this point, production and degradation balances each other, and no significant change in collagen amount is observed. The remodeling phase is the most responsible for intra- and interpersonal variations in scar qualities. A healing incisional wound can become an unsightly scar during this period.

Understanding these three main phases, wound healing can be optimized. Modifiable factors of incisional scar response include incision design, atraumatic handling of soft tissue, hemostasis, aseptic techniques, and tension reducing approaches in both the short and long-term postoperative setting (3).

Wound healing phases are not discrete. Proliferation phase begins even before the inflammation phase has completed and continues even as remodeling has begun. The remodeling phase itself continues long after the sutures have been removed and dressing abandoned. Because of this, the care of an incisional wound should be considered as a continual process, and minimizing scar formation should be a long-term goal. These are important aspects of wound management that must be emphasized to encourage patient participation (4, 5).

Skin tension and incision design

The external shape of human body is determined by the underlying bony skeletal framework, which the skin must cover. To conform to this complex shape, the skin must be both viscous

and elastic to deform and return to its original shape. Mechanically, it needs to be both strong and flexible.

The tension vectors across the skin are specific to the volume and movement of the underlying structure, and high skin tension is most closely associated with scar formation. Unfortunately, quantitative measurement of skin tension is neither reliable nor practical in clinical settings. Instead, skin lines have been used as surrogate indicators of tension vectors. While a multitude of skin lines have been introduced over time (6), Langer's line and relaxed skin tension line are the most widely known. A punch excision in the skin usually results in a circular defect that immediately deforms into an ellipse. When multiple punch excisions are performed and the major axes of these ellipses are connected, the resulting line is considered as a Langer's line (Fig. 1) (7). These lines run parallel to the main collagen bundles in the dermis but do not always follow the line of wrinkle.

Relaxed skin tension line (RSTL) is a furrow created when the skin is pinched and relaxed in the absence of local tension (Fig. 2) (8, 9). Clinically, the skin is maximally extensible perpendicular to RSTL, and this implies that the tension is minimized when incisions are created along RSTLs. While Langer's lines and RSTLs run in the same direction over many parts of the body, they are significantly different in mechanically complex areas such as the mouth corner, lateral canthal area, and temple.

A proper understanding of skin tension vectors is crucial to incision design. In the opinion of the authors, improper incision designs are the number one reason for hypertrophic scar

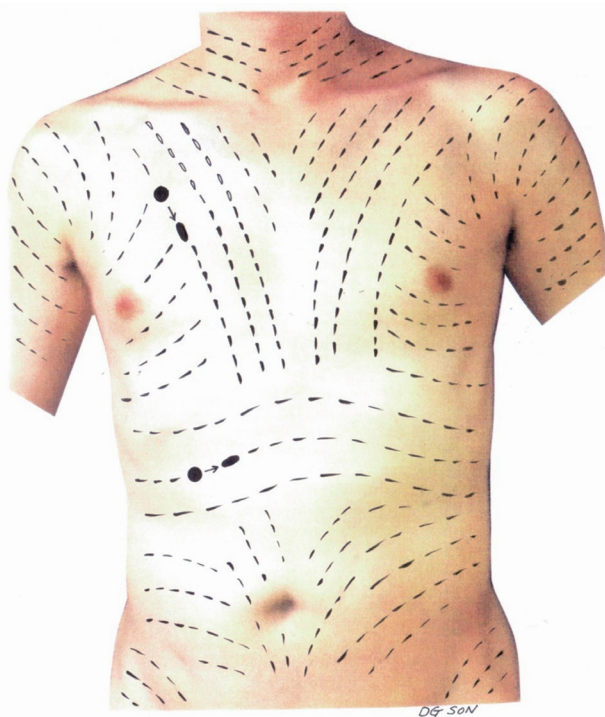


Fig. 1. Langer's lines.

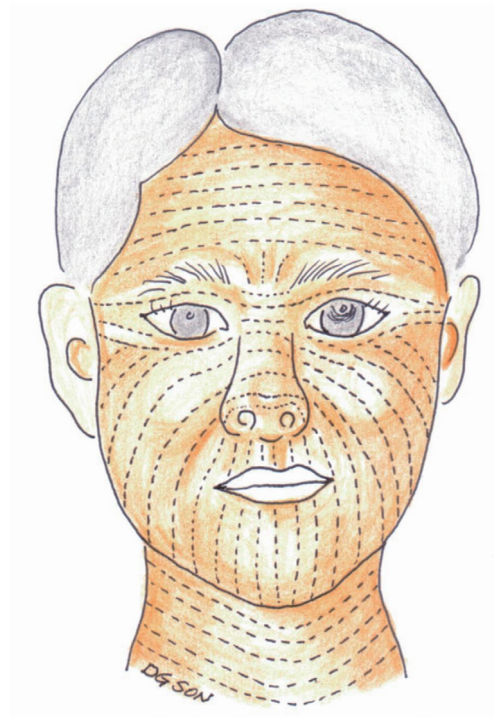


Fig. 2. Resting static tension lines on the face.

response observed in a remodeling wound. Great tension across an incision threatens to pull the skin edges apart. In response, the wound must try to hold itself together more tightly. Microscopically, this appears as increase collagen deposition. Macroscopically, the wound appears to become hypertrophic. The cruelty is in the timing. Because hypertrophic responses are observed months after an incision has been made, the surgeon cannot correct the errors of his/her ways - except perhaps to placate the patient.

In certain areas of extreme skin tension, hypertrophic response is unavoidable regardless of the direction of incision (i.e. shoulders). For this reason, traditional incisions almost always avoid the skin directly over extensor joints. The converse is also true; flexor creases welcome the scalpel with open arms.

Determinants of scar response other than skin tension

Blood supply

Blood supply is a significant factor in wound healing, and area of the skin with rich supply of vasculature is known to heal with finer scars. The face is a prime example.

From the major arteries, the blood flows through septocutaneous and musculocutaneous perforators, and supplies the fascial, subcutaneous, and dermal plexuses. Eventually, the blood exchanges nutrients and oxygen for carbon dioxide and other unwanted metabolites during the transit through dermal capillaries. The epidermis has no blood vessel, and nutrients are delivered from the dermis to epidermal cells by the process of diffusion.

A viable wound margin must receive its blood supply, and the blood supply has to come through one of two routes. Either it comes from a perforator vessel in the vicinity of wound bed, or it comes from a distant perforator vessel by the way of the dermal plexus. Often, the perforator vessels in the operative field cannot be preserved, especially if extensive undermining is required. In these circumstances, it is of utmost importance that the dermal plexus is respected. A skin flap created next to an old incision line is an island flap unless proven otherwise. If the few perforator vessels under the flap are divided during dissection, the surgeon has turned the flap into a full thickness composite tissue without any vascular supply. Many unfortunate abdominal incision wounds have died in this manner.

Patient factors

Aging tends to decrease skin tension and sebaceous gland activity, and as such, hypertrophic scars are observed with lesser frequency in the elderly. This is in contrast to incisional scars in children, among whom hypertrophic scars are common because of increased cellular activity, prolonged scar maturation, rapid physical growth, and increased skin elasticity.

Additionally, ethnic skin characteristics and their association to postoperative scar response have been well documented. Peo-

ple of European descent are more likely to form fine scars, while people of African descent appear genetically predisposed to hypertrophic scars and keloids.

Previous history of poor wound healing, hypertrophic scars, and keloids overrides all other patient factors. It is the patient with a keloid in the earlobe who is more likely to develop a keloid after a surgical incision.

While these demographic factors are just as important as respecting skin tension and blood supply, none of these is physiologically modifiable. Still, understanding these patient factors is important because the knowledge becomes a liability if not used as a part of informed consent. Untold, the liability has a tendency to grow with compound interest. Appropriate, patient-specific discussion during the preoperative visit can make the difference between a day in the courtroom and a thank you card after the postoperative follow up.

SCAR MANAGEMENT

Surgical technique

The operator experience and technique are known modifiable factors of outcomes relating to scar appearances, with increased experience associated improved aesthetic outcomes (10). The experience incorporates the time-honored incision designs used in various fields of surgery, as well as intraoperative techniques described as the 5 A's - a sepsis, absence of tension, accurate approximation, avoidance of raw surface, and atraumatic tissue handling.

Delicate instruments force operators to use as little traction and crushing force required to handle wound edges. In the same line, the smallest sutures that can adequately overcome wound tension is used in all layers of approximation. Non-absorbable sutures, such as nylon, should be removed as soon as the wound has gained the strength to hold itself together. With every skin closure, the surgeon must remember that the role of suture is to provide "approximation without tension." It is the job of the fibroblasts and collagen fibers - not sutures - to hold the wound together.

Postoperative care in the first few days

Dressing materials are known to influence postoperative surgical wound healing and scar formation (11, 12). After closure, wound hydration is controlled with foam dressings, which is changed daily or every other day. The wound can be cleaned with saline or tap-water, but alcohol or iodide is cytotoxic to the cells trying to do the work of healing within the wound. These cleaning products from a by-gone era should not be used to clean a wound that is healing well without any signs of infection.

Postoperative care in the first week

Any non-absorbable sutures are removed, and skin tape is ap-

plied to reduce tension. At one week after the surgery, the tensile strength across an incision is only 3% of that of uninterrupted skin. This figure increases to 20% by the third week when remodeling begins and to 80% after three months. Therefore, skin tape should be applied across the incision for at least three months to reduce the tension the remodeling wound must bear (13). These load-bearing tapes are most appropriate on convex skin surfaces but are not mandatory over flexor crease incisions.

Postoperative care in the first three months

This is the time at which remodeling is at its peak during a normal wound healing process. While most properly designed and executed operative incisions will continue to heal without significant protest, those incisions destined for hypertrophic response will begin to reveal themselves during this period. Therefore, monthly clinic examination of the scar is reasonable. Patients should be encouraged to continue dressing the wound with skin tape. Additionally, each patient be counseled to return to clinic earlier than the appointed clinic visit if the wound is beginning to look “beefy” or “upset”. During this period, a scar can undergo hypertrophic response, which is discussed in the following subsection.

Keloids and hypertrophic scars

Keloids and hypertrophic scars are suboptimal consequences of skin wound healing, and are believed to be unique to human skin. These two clinical entities belong to a spectrum of fibroproliferative disorders, and are difficult to differentiate histologically in the absence of relevant clinical details (14).

Hypertrophic scar

Synthesis and degradation of collagen fibers define the remodeling phase. As a wound reaches maturity, extracellular cyto-

kines change for cessation of further collagen synthesis and degradation. However, a number of genetic and environmental factors can interfere with this ‘stop’ signal, and the lack of negative feedback can lead to continual production of collagen fibers in the wound. Clinically, this response is observed as a hypertrophic scar.

A distinctive feature of hypertrophic scar is that, while its surface is elevated in relation to normal skin, the proliferation is contained within the margin of the wound. Under excessive tension, a scar can become wider and hypertrophic. However, the increase in collagen deposition does not continue beyond the wound margin.

Clinically, hypertrophic scars are often red and grow from 3 to 6 months (Fig. 3). Most hypertrophic scars begin to lose the redness and diminish in size around 6 months, and this process continues for 2 yr until the elevated surface flattens (15). Severe hypertrophic scars, however, can cause severe pain and pruritus. The latter often responds to antihistamine medication.

Silicone gel sheets or silicone oil-based cream has been proved to be effective in limiting hypertrophic growth of scars (16), and are believed to decrease scar size by the increase in hydration and local skin temperature under the occlusive membrane (17, 18). In patients with predisposing factors for hypertrophic scar, silicone gel sheets should be applied as early as two weeks after an operation. The gel sheet is trimmed slightly larger than the scar, and is applied every two hours with 30-min rest intervals between. The interval is gradually increased to four hours with 30-min rest intervals. This is continued for up to six months after the operation. In locations where sheet attachment is difficult, scar cream can be used instead (19) upon complete epithelialization of the wound surface. The cream is topically applied 3 to 4 times a day and massaged for 5 to 10 min with each application.

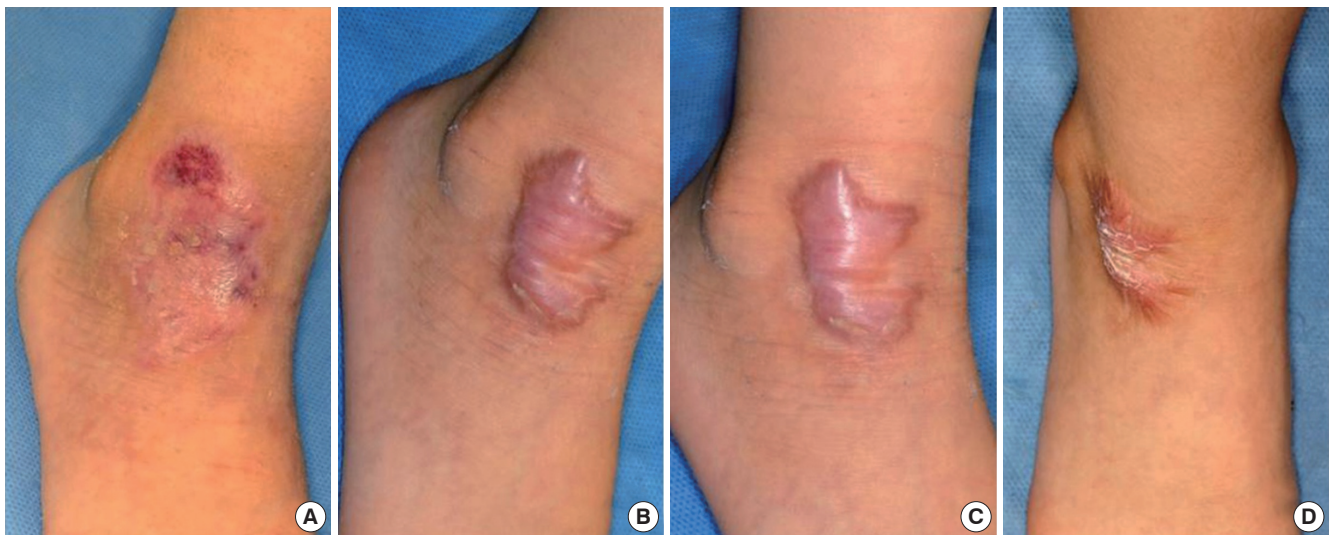


Fig. 3. Serial photographs of a healing wound from abrasion over the ankle. (A) At full epithelialization, (B) 3 months, (C) 6 months, and (D) 12 months from abrasion.

While used more frequently for keloids, intralesional steroid injections are highly effective in the management of hypertrophic scars. As with keloids, the steroid (Kenalog 40 mg/mL) is injected directly within the fibrous portion of the scar (20, 21). The steroid inhibits expressions of genes related with collagen synthesis, which reduces collagen production and increases degradation.

In the face, 2.5-20 mg/mL of the mixture is injected, and 20-40 mg/mL can be injected for lesions elsewhere in the body. The injections can be repeated every month for 4-5 months. The total amount of one-time injection should not exceed 120 mg in adults and 80 mg in children. Because injections into the scar tissue requires significant amount of pressure, syringes with fixed needle or dermojet are used to deliver the mixture. The authors prefer the use of 1 mL syringe with fixed needle.

Steroid injection into subcutaneous fat of surrounding skin can result in skin atrophy, depigmentation, and telangiectasis. In such cases, injections should not be repeated, and these changes ameliorate over time.

Pressure therapy can prevent some scar elevation (22) and should be started soon after clinical wound healing. Local hypoxia by physical pressure induces regeneration of fibroblasts, suppresses collagen production, and activates collagenase, which expedites collagen dismantling. The pressure should exceed 24 mmHg for more than 30 min every day for 3-12 months. Pressure therapy is physically uncomfortable. Patient compliance is expectedly low. Thus, results are highly dependent on patient motivation. This treatment significantly limits daily activity and should be reserved for more severe cases of hypertrophic scars.

Additionally, various forms of lasers, including Nd:YAG 1064, fractional laser, pulsed dye laser, IPL, Q-switched laser, have been reported to improve scar appearance (23, 24).

Ultimately, hypertrophic scars unresponsive to treatments above can be revised through excision. If the orientation of the previous incision placed the scar in the line of tension, a Z-plasty or W-plasty can be used to transpose the tension vector across the newly created incision.

Keloid

Keloids are frequently observed in wounds experiencing high tensile forces. Additionally, predisposition to keloids are known to be passed down as autosomal dominant traits and are more commonly found in Africans and Asians than in Caucasians (15). More specifically, populations of African descent experience keloid incidences as high as 4.5 to 16 percent (25).

The feature distinguishing keloids from hypertrophic scars is the continued scar hypertrophy during the later phase of remodeling process between 6 and 18 months. A keloid scar grows beyond the original wound margin, turns from red to brown, and behaves like a benign tumor of the skin (Fig. 4).

From a molecular biology perspective, a keloid is product of

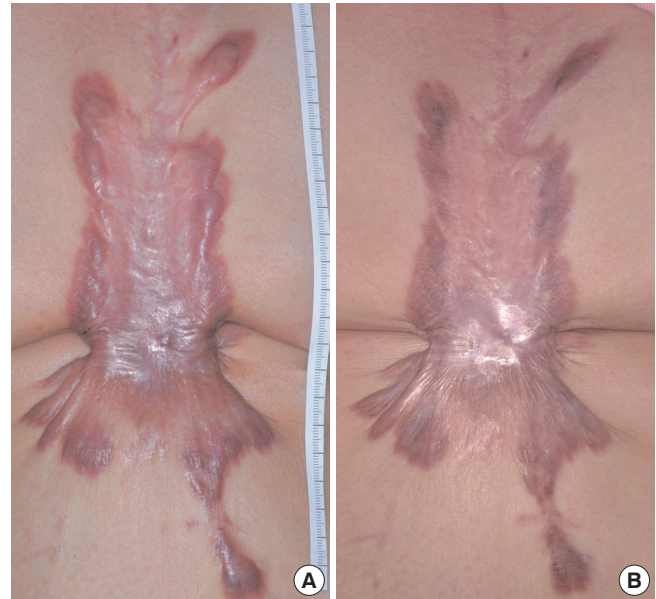


Fig. 4. Steroid injection in keloid. (A) Keloids over the sternum in a 62-yr-old female patient after open heart operation. (B) The keloid responded well after three injections of intralesional steroid.

uninhibited deposition of collagen. Within a normally healing wound, proliferation of fibroblasts phases out, with cells undergoing apoptosis in the peripheral margin. This down regulation of fibroblasts and collagen deposition is also observed within hypertrophic scars in the late phase of remodeling (26, 27). In keloids, however, fibroblasts continue to proliferate despite the fact that the dermal matrix is more than strong enough to offset the tensile forces across the wound. Even after decades of research, the exact etiology behind keloids remains unclear (28-30).

Postoperative management of keloid begins with frequent survey of the incision site for early keloid formation. Silicone gel sheeting and silicone oil-based cream are often applied to keloids, but the outcomes are not as encouraging when compared to hypertrophic scars. Instead, the mainstay of keloid treatment continues to be intralesional steroid injections, which often result in significant improvements after 3 to 4 administrations. The steroids also improve pain and itching frequently associated with keloids. Unlike hypertrophic scars, however, keloids can recur after cessation of steroid injections. Follow up interventions are often necessary.

Physical pressure treatments generally are not effective, but one exception is found in magnetic pressure earrings. The ring can be applied on small keloids of the earlobe, and large keloids can be debulked prior to the application of magnetic earrings.

Keloids have been removed using a variety of surgical methods, from simple core excision with primary closure to complete wide-margin excisions and closure with skin grafts. Despite the variations in surgical techniques and adjunctive treatment options, relapse rates range from 45 to 100%. Radiation therapy is effective as an adjunctive treatment to surgical exci-

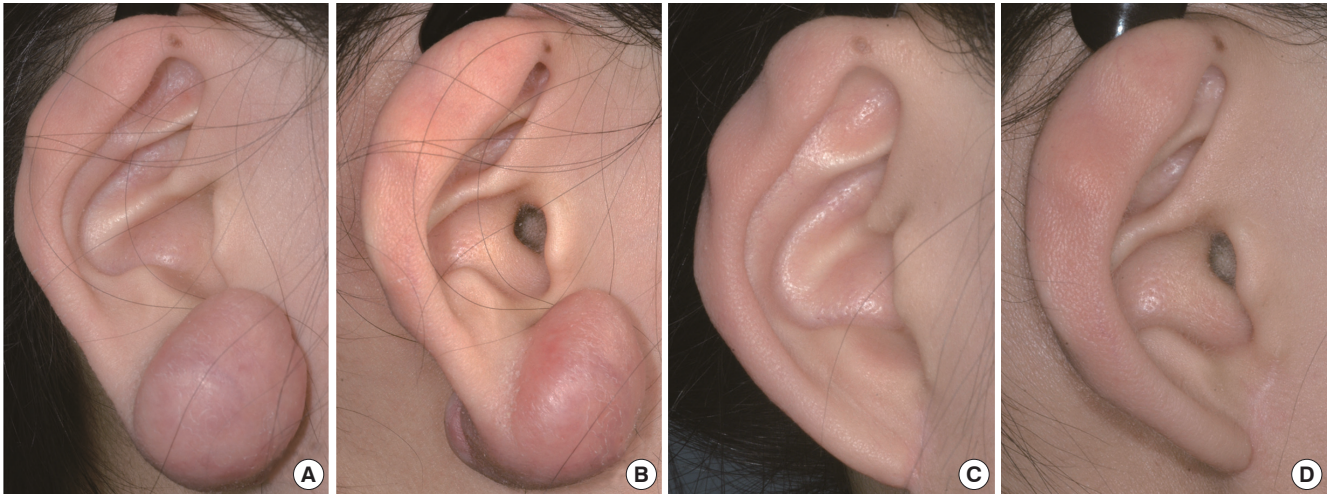


Fig. 5. Radiation therapy after keloid excision. (A, B) Photographic views of a 15-yr-old teenage girl with keloids from ear piercing. (C, D) One year after surgical excision and radiation therapy.

sions (Fig. 5). In a previously study, the authors have found that radiation therapy was associated with an average decrease of 55% at 30 months of follow up (31). Although adjunctive radiation therapy decreases recurrence rate, non-discriminate use of radiation is discouraged because of increased risk of cancer with all ionizing forms of radiation. Nonetheless, reports of cancer cases after irradiation on keloids are rare.

The use of intralesional steroids and radiotherapy do decrease recurrence rates, but this does little to comfort the patients still experience from recurrence after having exhausted all available forms of treatments. Prior to any surgical intervention, patients with significant personal or family history of keloids should thoroughly be counseled regarding the high likelihood of recurrence and the need for continued management.

Alternative approaches have been described in keloid literature. Chemotherapy agents, 5-fluorouracil and bleomycin, have been used in keloid (32, 33). Presently, novel modalities such as molecular targets (34) and mesenchymal stem cells (35-37) lack adequate evidence for clinical application.

CONCLUSION

Clinical management of incisional scar begins with a thorough preoperative discussion. Before all elective operation, a patient should be aware of personal predisposing factors for excessive scar formation. The largest modifiable factor of scar formation is the design of skin incision that bears the least amount of tension in the postoperative period. Skin tension lines are to be respected, as well as blood supplies to the wound margins. Non-absorbable sutures are removed as early as the wound is able to hold itself together. Tension-bearing skin tapes are used during the period of remodeling. Patients should be encouraged to take active participation in wound care, even long after the skin

appears to have healed. Postoperative visits should focus on prevention, screening, and treatment of hypertrophic scars. Hypertrophic scars that do not improve after six months are no longer hypertrophic scars. They are keloids, and require intensive management.

DISCLOSURE

The authors have no conflicts of interest to disclose.

ORCID

Daegu Son <http://orcid.org/0000-0002-4653-1048>

REFERENCES

1. Almine JF, Wise SG, Weiss AS. *Elastin signaling in wound repair. Birth Defects Res C Embryo Today* 2012; 96: 248-57.
2. Bae SH, Bae YC, Nam SB, Choi SJ. *A skin fixation method for decreasing the influence of wound contraction on wound healing in a rat model. Arch Plast Surg* 2012; 39: 457-62.
3. Larson BJ, Longaker MT, Lorenz HP. *Scarless fetal wound healing: a basic science review. Plast Reconstr Surg* 2010; 126: 1172-80.
4. Kim HY, Kim JW, Park JH, Kim JH, Han YS. *Personal factors that affect the satisfaction of female patients undergoing esthetic suture after typical thyroidectomy. Arch Plast Surg* 2013; 40: 414-24.
5. Toll EC, Loizou P, Davis CR, Porter GC, Pothier DD. *Scars and satisfaction: do smaller scars improve patient-reported outcome? Eur Arch Otorhinolaryngol* 2012; 269: 309-13.
6. Chu HJ, Son DG, Kwon SY, Kim JH, Han KH. *Characteristics of wound contraction according to the shape and anatomical regions of the wound in porcine model. J Korean Soc Plast Reconstr Surg* 2011; 38: 576-84.
7. Wilhelmi BJ, Blackwell SJ, Phillips LG. *Langer's lines: to use or not to use. Plast Reconstr Surg* 1999; 104: 208-14.

8. Borges AF. *Relaxed skin tension lines (RSTL) versus other skin lines. Plast Reconstr Surg* 1984; 73: 144-50.
9. Borges AF. *Relaxed skin tension lines. Dermatol Clin* 1989; 7: 169-77.
10. Bush JA, McGrouther DA, Young VL, Herndon DN, Longaker MT, Mustoe TA, Ferguson MW. *Recommendations on clinical proof of efficacy for potential scar prevention and reduction therapies. Wound Repair Regen* 2011; 19: s32-7.
11. Kang BS, Na YC, Jin YW. *Comparison of the wound healing effect of cellulose and gelatin: an in vivo study. Arch Plast Surg* 2012; 39: 317-21.
12. Shin HS, Oh HY. *The effect of platelet-rich plasma on wounds of OLETF rats using expression of matrix metalloproteinase-2 and -9 mRNA. Arch Plast Surg* 2012; 39: 106-12.
13. Atkinson JA, McKenna KT, Barnett AG, McGrath DJ, Rudd M. *A randomized, controlled trial to determine the efficacy of paper tape in preventing hypertrophic scar formation in surgical incisions that traverse Langer's skin tension lines. Plast Reconstr Surg* 2005; 116: 1648-56.
14. Verhaegen PD, van Zuijlen PP, Pennings NM, van Marle J, Niessen FB, van der Horst CM, Middelkoop E. *Differences in collagen architecture between keloid, hypertrophic scar, normotrophic scar, and normal skin: an objective histopathological analysis. Wound Repair Regen* 2009; 17: 649-56.
15. Bran GM, Goessler UR, Hormann K, Riedel F, Sadick H. *Keloids: current concepts of pathogenesis (review). Int J Mol Med* 2009; 24: 283-93.
16. Juckett G, Hartman-Adams H. *Management of keloids and hypertrophic scars. Am Fam Physician* 2009; 80: 253-60.
17. Chang CC, Kuo YF, Chiu HC, Lee JL, Wong TW, Jee SH. *Hydration, not silicone, modulates the effects of keratinocytes on fibroblasts. J Surg Res* 1995; 59: 705-11.
18. Borgognoni L. *Biological effects of silicone gel sheeting. Wound Repair Regen* 2002; 10: 118-21.
19. Sawada Y, Sone K. *Treatment of scars and keloids with a cream containing silicone oil. Br J Plast Surg* 1990; 43: 683-8.
20. Tang YW. *Intra- and postoperative steroid injections for keloids and hypertrophic scars. Br J Plast Surg* 1992; 45: 371-3.
21. Rosen DJ, Patel MK, Freeman K, Weiss PR. *A primary protocol for the management of ear keloids: results of excision combined with intraoperative and postoperative steroid injections. Plast Reconstr Surg* 2007; 120: 1395-400.
22. Niessen FB, Spauwen PH, Schalkwijk J, Kon M. *On the nature of hypertrophic scars and keloids: a review. Plast Reconstr Surg* 1999; 104: 1435-58.
23. Bouzari N, Davis SC, Nouri K. *Laser treatment of keloids and hypertrophic scars. Int J Dermatol* 2007; 46: 80-8.
24. Parrett BM, Donelan MB. *Pulsed dye laser in burn scars: current concepts and future directions. Burns* 2010; 36: 443-9.
25. Oluwasanmi JO. *Keloids in the African. Clin Plast Surg* 1974; 1: 179-95.
26. Appleton I, Brown NJ, Willoughby DA. *Apoptosis, necrosis, and proliferation: possible implications in the etiology of keloids. Am J Pathol* 1996; 149: 1441-7.
27. Ladin DA, Hou Z, Patel D, McPhail M, Olson JC, Saed GM, Fivenson DP. *P53 and apoptosis alterations in keloids and keloid fibroblasts. Wound Repair Regen* 1998; 6: 28-37.
28. DiPietro LA. *Angiogenesis and scar formation in healing wounds. Curr Opin Rheumatol* 2013; 25: 87-91.
29. Huang C, Akaishi S, Ogawa R. *Mechanotransduction pathways in cutaneous scarring. Arch Dermatol Res* 2012; 304: 589-97.
30. Sarrazy V, Billet F, Micallef L, Coulomb B, Desmoulière A. *Mechanisms of pathological scarring: role of myofibroblasts and current developments. Wound Repair Regen* 2011; 19: s10-5.
31. Son DG, Lee HG, Han KH, Kim JH. *Radiation therapy following total keloidectomy; a preliminary report. J Korean Soc Plast Reconstr Surg* 2005; 32: 717-22.
32. Nanda S, Reddy BS. *Intralesional 5-fluorouracil as a treatment modality of keloids. Dermatol Surg* 2004; 30: 54-6.
33. Tziotzios C, Profyris C, Sterling J. *Cutaneous scarring: pathophysiology, molecular mechanisms, and scar reduction therapeutics Part II. Strategies to reduce scar formation after dermatologic procedures. J Am Acad Dermatol* 2012; 66: 13-24.
34. Occeleston NL, Fairlamb D, Hutchison J, O'Kane S, Ferguson MW. *Avotermin for the improvement of scar appearance: a new pharmaceutical in a new therapeutic area. Expert Opin Investig Drugs* 2009; 18: 1231-9.
35. Jackson WM, Nesti LJ, Tuan RS. *Mesenchymal stem cell therapy for attenuation of scar formation during wound healing. Stem Cell Res Ther* 2012; 3: 20.
36. Sung HM, Suh IS, Lee HB, Tak KS, Moon KM, Jung MS. *Case reports of adipose-derived stem cell therapy for nasal skin necrosis after filler injection. Arch Plast Surg* 2012; 39: 51-4.
37. Yang JD, Choi DS, Cho YK, Kim TK, Lee JW, Choi KY, Chung HY, Cho BC, Byun JS. *Effect of amniotic fluid stem cells and amniotic fluid cells on the wound healing process in a white rat model. Arch Plast Surg* 2013; 40: 496-504.