



ORIGINAL ARTICLE

Topical Brimonidine as an Effective Adjuvant to Local Anesthetics for Post Treatment Erythema and Pain Reduction

Hyun Jung Kwon, Jae Min Kim, Guk Jin Jeong, Sang Ju Lee¹, Hae Woong Lee², Kui Young Park, Seong Jun Seo

Department of Dermatology, Chung-Ang University College of Medicine, ¹Yonsei Star Skin & Laser Clinic, Seoul, ²Louis Dermatologic Clinic, Guri, Korea

Background: There are few pharmacologic options to reduce laser-associated post treatment erythema and to extend topical anesthesia duration. To improve the tolerability of painful laser treatment, dermatologists should encourage development of a novel adjuvant agent to topical lidocaine cream.

Objective: To report the efficacy and safety of a combination of topical brimonidine and anesthetic cream as an aid for post treatment erythema and pain. **Methods:** A total of 15 Korean subjects were randomized to receive a split-face application of a mixture of brimonidine and anesthetics on one side and only anesthetics on the other side of the face for anesthesia. After non-ablative fractional full-face skin resurfacing, Clinician's Erythema Assessment, erythema index, and visual analogue scale were assessed at four time points: immediately after resurfacing, 30 minutes after, 60 minutes after, and 1 day after. **Results:** A combination of brimonidine and anesthetics significantly lowered post treatment erythema until 60 minutes after the laser procedure. Furthermore, patients reported significantly lower post-procedural pain from the side of their face that received the mixture of anesthetics and

brimonidine than they did for the side that only received anesthetics. **Conclusion:** Topical brimonidine can be used as an effective adjuvant agent to lidocaine-based topical anesthetics. (*Ann Dermatol* 31(3) 315 ~ 319, 2019)

-Keywords-

Alpha-2-agonist, Anesthesia, Brimonidine tartrate, Erythema, Pain

INTRODUCTION

The recent growth in the demand for cosmetic and invasive dermatologic procedures has resulted in increased use of topical anesthetics, which are necessary to control pain and ensure patient satisfaction and safety. Some types of topical anesthetics have been introduced to diminish patient discomfort, including EMLA[®] cream (lidocaine 2.5% and prilocaine 2.5%; AstraZeneca, London, UK), which is the most widely used topical anesthetic agent and is an amide anesthetic composed of 25 mg/ml of lidocaine and 25 mg/ml of prilocaine in an oil-in-water emulsion¹. Product recommendations suggest applying EMLA[®] to intact skin, under occlusion, for at least one hour. The application duration is directly correlated with analgesia depth, which reaches 3 mm after 60 minutes and 5 mm after 120 minutes². EMLA[®] cream may cause several adverse reactions, from allergic contact dermatitis to serious systemic toxicity. Prilocaine can cause serious allergic contact dermatitis and methemoglobinemia, which may result in cyanosis, respiratory insufficiency, or, on rare occasions, even death³. Systemic absorption of lidocaine can also cause dose-dependent adverse effects on the central nerv-

Received October 24, 2018, Revised December 6, 2018, Accepted for publication January 6, 2019

Corresponding author: Kui Young Park, Department of Dermatology, Chung-Ang University Hospital, 102 Heukseok-ro, Dongjak-gu, Seoul 06973, Korea. Tel: 82-2-6299-1525, Fax: 82-2-6299-1718, E-mail: momo920@hanmail.net
ORCID: <https://orcid.org/0000-0001-5965-1754>

This is an Open Access article distributed under the terms of the Creative Commons Attribution Non-Commercial License (<http://creativecommons.org/licenses/by-nc/4.0>) which permits unrestricted non-commercial use, distribution, and reproduction in any medium, provided the original work is properly cited.

Copyright © The Korean Dermatological Association and The Korean Society for Investigative Dermatology

ous system⁴. However, when EMLA[®] was applied to a 1,296-cm² area, the concentration in the blood did not exceed 1,100 ng/ml for lidocaine and 200 ng/ml for prilocaine. In clinical settings, no systemic side effects would be expected in typical cases when applying 5 g to 10 g of EMLA[®] cream⁵.

Brimonidine gel (0.33%, Mirvaso[®]; Galderma SA, Lausanne, Switzerland) is a highly selective α 2-adrenergic receptor agonist with potent vasoconstrictive activity and has received United States Food and Drug Administration (FDA) approval for treating facial erythema due to rosacea. It improves moderate to severe erythema after the first application with a rapid onset of action within 30 minutes and a reduction in erythema for up to 12 hours⁶. Recently, Gerber reported observing that brimonidine gel effectively reduces post treatment erythema after daylight-activated photodynamic therapy⁷. Also, Schleichert and Weiss⁸ demonstrated the use of brimonidine gel as an efficient hemostatic agent in dermatologic surgery. These experimental trials demonstrate the vasoconstrictive properties of topical brimonidine gel, but there have been no evaluations of the additional effect of brimonidine gel when used in combination with EMLA[®].

For example, Spencer demonstrated that epinephrine prolongs analgesia duration, including local infiltration of lidocaine, in a dose-related manner. The magnitude of epinephrine-induced vasoconstriction correlated with analgesia duration, which may explain why local vasoconstriction decreases the systemic absorption rate of anesthesia despite the local toxicity of epinephrine that decreases wound healing and promotes cell death⁹.

Therefore, herein, we report for the first time on the efficacy of the combined use of topical brimonidine and EMLA[®] as an aid in post treatment erythema and effective anesthesia in dermatologic procedures.

MATERIALS AND METHODS

Patients

Fifteen Korean volunteers (aged 25~38 years old with Fitzpatrick skin types III~IV) were enrolled after study approval by the Institutional Review Board of Chung-Ang University Hospital (IRB no. 1740-004-277). Written informed consent was obtained from all participants after the risks and benefits of the procedure were explained in detail. Participants were excluded if they reported a history of rosacea or persistent facial flushing, hypersensitivity to drugs, active cutaneous inflammation, current intake of monoamine oxidase inhibitors, or having undergone any laser treatments within the last four weeks.

Treatment protocols

A split-face study was designed for an efficacy and safety evaluation with fifteen Korean subjects who received a combination formula (1:1 mixture of 5 g of EMLA[®] and 5 g of Mirvaso[®], total 10 g of mixed formula) on one half of their faces and 5 g of EMLA[®] cream on the other side. After 30 minutes without occlusion, each participant received non-ablative fractional full-face skin resurfacing with a 1,550-nm erbium-glass fractionated laser (Sellas; Dinona Inc., Daejeon, Korea) at an 18-mJ fluence and one pass in stamping mode.

Assessments

Post treatment erythema was evaluated using the internationally validated Clinician's Erythema Assessment (CEA), which is a 5-point scale (0=clear skin with no signs of erythema; 1=almost clear, slight redness; 2=mild erythema, definite redness; 3=moderate erythema, marked redness; 4=severe erythema, fiery redness), and with the erythema index (EI). We obtained these measures with a Mexameter MX18 (Courage-Khazaka Electronic GmbH, Köln, Germany) from both sides of the cheek immediately after the procedure, 30 minutes after, 60 minutes after, and 1 day after.

Patient discomfort and pain were evaluated using the numeric visual analogue scale, which ranks pain from 0 (no discomfort/pain) to 10 (extreme discomfort/pain). We evaluated the pain for anesthetics only and for the brimonidine combination. Pain was evaluated during the laser procedure, immediately after, 30 minutes, 60 minutes, and 1 day after the procedure. Current digital photographs were compared to the previous photos at each follow-up throughout the study. The statistical analysis package IBM SPSS Statistics ver. 19.0 (IBM Co., Armonk, NY, USA) was used to evaluate the efficacy of the Mirvaso[®] and EMLA[®] mixture for procedural pain reduction and post treatment erythema. The significance level was set at p -value ≤ 0.05 . Paired t-tests were used to compare between the test and control side at each evaluation point.

RESULTS

Efficacy evaluation

1) Post treatment erythema

The mean CEA scores were 2.88, 2.38, 2.13, and 2.00 for the EMLA[®]-only side, and 1.50, 1.06, 0.50, and 1.53 for the EMLA[®]-Mirvaso[®] combination side immediately after, 30 minutes after, 60 minutes after, and 1 day after the procedure, respectively (Fig. 1). The CEA score for the EMLA[®]

and Mirvaso[®] combination was lower than for EMLA[®] alone throughout the follow-up period. The differences in CEA according to investigator assessments were only significant up to 60 minutes after the procedure. Similarly, the mean EI scores, as measured by Mexameter, were 293.00, 273.70, 282.04, and 350.03 for the EMLA[®]-only side, and 219.64, 193.94, 202.78, and 312.4 for the EMLA[®] and Mirvaso[®] combination side immediately after, 30 minutes after, 60 minutes after, and 1 day after the procedure, respectively (Fig. 2). The EI for the combination side was also lower than for the EMLA[®]-only side.

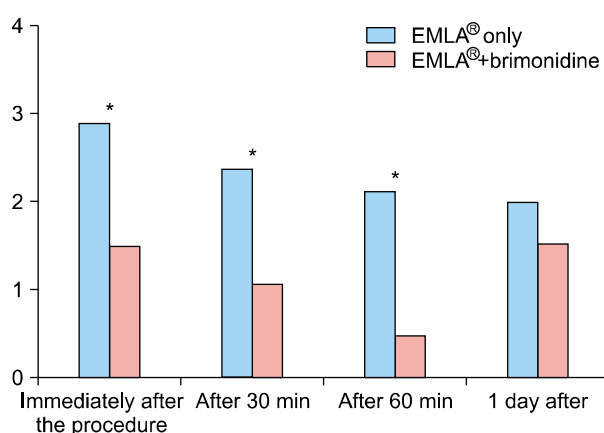


Fig. 1. Clinician's Erythema Assessment was assessed by investigators after laser treatment ($*p < 0.05$), which is a 5-point scale (0=clear skin with no signs of erythema; 1=almost clear, slight redness; 2=mild erythema, definite redness; 3=moderate erythema, marked redness; 4=severe erythema, fiery redness). Erythema index measured by Mexameter after laser treatment ($*p < 0.05$).

The differences in EI were only significant up to 60 minutes after the procedure. Serial photographic images of post treatment erythema are presented in Fig. 3. We received the patient's consent form about publishing all photographic materials.

2) Procedural pain

The mean values for procedure-related pain for the EMLA[®]-only side were 3.88, 3.69, 3.13, 1.88, and 0.47 during, immediately after, 30 minutes, 60 minutes, and 1 day after the procedure, respectively. The mean values for the EMLA[®] and Mirvaso[®] combination side were 3.38, 3.19, 2.13, 1.00, and 0.40, respectively (Fig. 4). There were only significant differences between both sides 30 and 60 minutes after the procedures ($p = 0.046$ and $p = 0.027$, re-

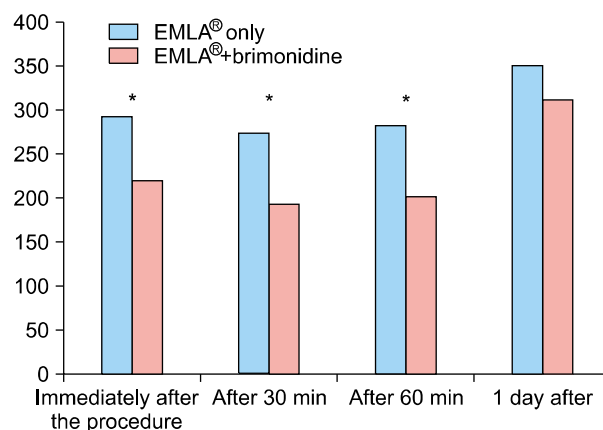


Fig. 2. Erythema index measured by Mexameter after laser treatment ($*p < 0.05$).

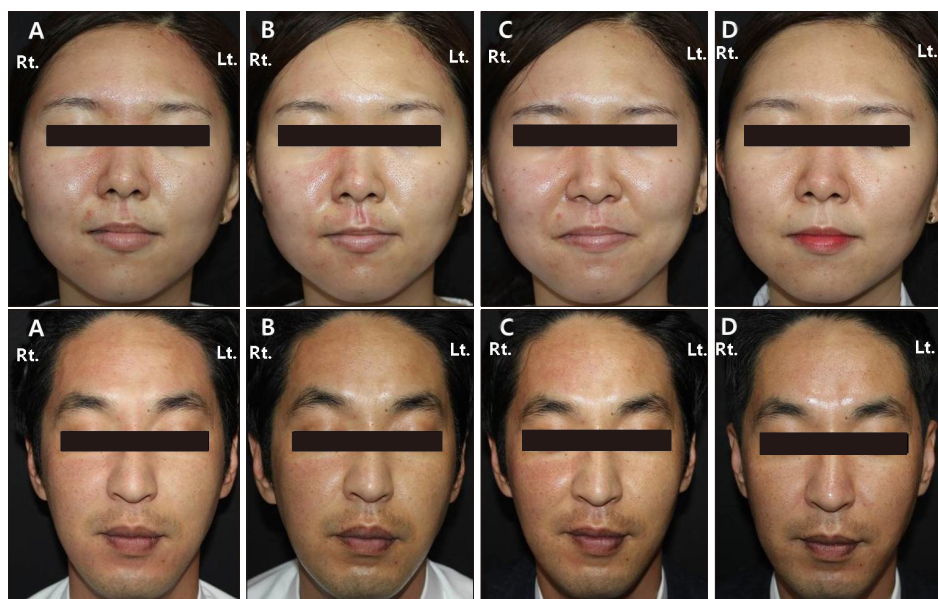

Fig. 3. Mixture of brimonidine and EMLA[®] applied to the right side of the face effectively reduced post treatment erythema associated with fractional laser immediately after the procedure and 30 and 60 minutes after the procedure. Immediately after (A); 30 minutes (B); 60 minutes (C); 1 day after laser treatment (D). Rt.: right, Lt.: left.

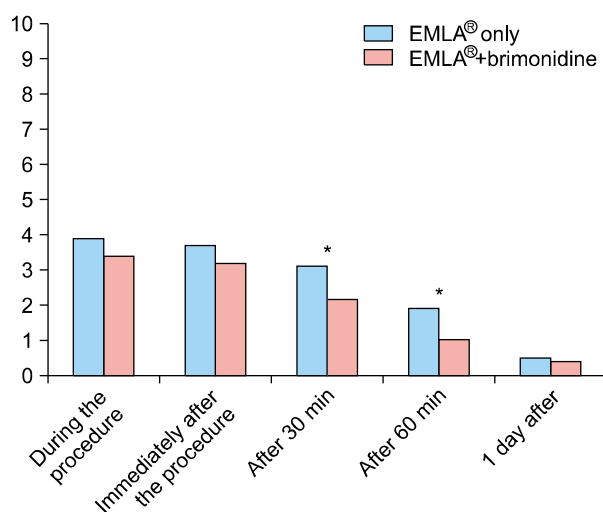


Fig. 4. Visual analog scale after application of topical anesthetics for 30 minutes. A combination of EMLA[®] and brimonidine was statistically superior to the EMLA[®]-only application at 30 and 60 minutes after laser treatment (* $p < 0.05$).

spectively). The pain gradually declined over the 60 minutes immediately following the procedure on both sides.

3) Safety evaluation

Both treatments were well tolerated. There was only one case of an adverse reaction, which was associated with allergic contact dermatitis to EMLA[®]; the case was mild and self-limiting without remaining sequelae. Furthermore, the investigators did not observe any rebound erythema after brimonidine cessation.

DISCUSSION

Topical anesthetics including lidocaine and prilocaine inhibit nerve-fiber depolarization, thus blocking action-potential transmission¹⁰. The painful stimuli are transmitted by small unmyelinated nerve fibers, which are more sensitive to anesthetics than myelinated fibers that transmit other types of sensations. Consequently, patients may feel pressure and vibration even while being insensitive to pain¹¹. Like epinephrine, the adjuvant effect of adding clonidine to local anesthetics for nerve block has been examined. Clonidine, an α_2 adrenergic agonist, significantly shortened the time to onset of sensory block and also prolonged the duration of local anesthesia¹².

However, prolongation of nerve blockade duration by clonidine is not mediated by an α -adrenergic mechanism via local vasoconstriction; rather, it likely involves I_h channel blockade. In other words, clonidine enhances activity-dependent hyperpolarization by inhibiting the I_h channel¹³. Also, because α_2 adrenoreceptors are not present on the

axon on the normal peripheral nerve, I_h channel blockade activity, not α_2 adrenoreceptor activity, contributes to enhancing prolongation by clonidine¹⁴. However, in another study assessing human cutaneous nerve blockade, local vasoconstrictive effects might slow lidocaine absorption, suggesting that prolongation of the nerve block was at least partially pharmacokinetically mediated¹⁵. In accordance with clinical studies, it is assumed that the adjuvant effect of brimonidine in prolonging anesthesia could be more potent, since it is 7- to 12-fold more α_2 -selective than clonidine¹⁶.

Braun et al.¹⁷ demonstrated that applying topical brimonidine reduced laser-associated post treatment erythema and, thus, may improve the tolerability of ablative lasers. After two-hour applications, the patients showed nearly complete regression of laser-induced erythema, an effect that lasted up to 12 hours. Brimonidine was approved to treat facial erythema and is often prescribed to rosacea patients; consequently; its vasoconstrictive activity is expected to reduce facial erythema and flushing after laser therapy.

In this study, we analyzed the adjuvant effect of brimonidine gel on a specific use of EMLA[®]. The EMLA[®] and brimonidine mixture significantly lowered post treatment erythema up to 60 minutes after the laser procedure via cutaneous vasoconstriction. However, we observed no significant differences in post treatment erythema between both sides 24 hours after the procedure. The likely reason for this is that the pharmacologic action time of brimonidine is about 12 hours; thus, no significant difference was observed between the two groups by 24 hours after the procedure.

Patients also reported significantly lower post procedural pain with the EMLA[®] and brimonidine combination treatment 30 and 60 minutes after the procedure than with the EMLA[®]-only treatment. We further showed that adjuvant brimonidine subsequently extended the duration of anesthesia via I_h channel blockade and it enhanced patient comfort. Alternatively, these outcomes may be associated with the vasoconstrictive effect, exhibiting reduced post treatment erythema because patients often reported post procedure hot flush or heating sensations as pain. However, pain during the procedure was not different between two groups after receiving the EMLA[®] and brimonidine combination than after receiving EMLA[®]-only. This demonstrated that brimonidine did not diminish the time to onset of sensory block or enhance the potency of anesthesia; rather, it prolonged the anesthesia duration.

Both topical agents were well tolerated and showed no systemic toxicity or drug-related adverse events, with the exception of one case of allergic contact dermatitis to EMLA[®]. Though brimonidine is formulated for less central

nervous system (CNS) penetration, topical brimonidines that are systemically absorbed may cause central α_2 agonism, leading to CNS depression, bradycardia, and hypotension^{18,19}. Also, there may be potential for over-absorption of brimonidine when used in conjunction with ablative device procedures. Therefore, to avoid poisoning from systemic exposure to excessive doses, clinicians should apply topical brimonidine prior to ablative laser treatment, limit the total application dose and this must be wiped off immediately before the laser procedure. The study is limited by its small sample size. Through further robustly-designed studies, ideal dosage, mixture regimen, and safety guidelines can be established. Although the optimal dose of brimonidine and the exact mechanisms of its effects are not definitely known, brimonidine can be used as an effective adjuvant agent when added to topical anesthetics.

ACKNOWLEDGMENT

Brimonidine gel (Mirvaso[®]; Galderma SA, Lausanne, Switzerland) was supported by Galderma Korea, Inc., Seoul, Korea.

CONFLICTS OF INTEREST

K.Y.P. is in receipt of research grants from Galderma Korea, Inc., Seoul, Korea.

ORCID

Hyun Jung Kwon, <https://orcid.org/0000-0001-8376-2358>
 Jae Min Kim, <https://orcid.org/0000-0001-7333-3883>
 Guk Jin Jeong, <https://orcid.org/0000-0002-2379-0370>
 Sang Ju Lee, <https://orcid.org/0000-0003-2228-7121>
 Hae Woong Lee, <https://orcid.org/0000-0003-0721-344X>
 Kui Young Park, <https://orcid.org/0000-0001-5965-1754>
 Seong Jun Seo, <https://orcid.org/0000-0003-2915-839X>

REFERENCES

- Friedman PM, Mafong EA, Friedman ES, Geronemus RG. Topical anesthetics update: EMLA and beyond. *Dermatol Surg* 2001;27:1019-1026.
- Huang W, Vidimos A. Topical anesthetics in dermatology. *J Am Acad Dermatol* 2000;43:286-298.
- Jussi L, Lammintausta K. Sources of sensitization, cross-reactions, and occupational sensitization to topical anaesthetics among general dermatology patients. *Contact Dermatitis* 2009;60:150-154.
- ECC Committee, Subcommittees and Task Forces of the American Heart Association. 2005 American Heart Association guidelines for cardiopulmonary resuscitation and emergency cardiovascular care. *Circulation* 2005;112(24 Suppl): IV1-203.
- Ohlsén L, Englesson S, Evers H. An anaesthetic lidocaine/prilocaine cream (EMLA) for epicutaneous application tested for cutting split skin grafts. *Scand J Plast Reconstr Surg* 1985;19:201-209.
- Layton AM, Schaller M, Homey B, Hofmann MA, Bewley AP, Lehmann P, et al. Brimonidine gel 0.33% rapidly improves patient-reported outcomes by controlling facial erythema of rosacea: a randomized, double-blind, vehicle-controlled study. *J Eur Acad Dermatol Venereol* 2015;29: 2405-2410.
- Gerber PA. Topical brimonidine tartrate 0.33% gel effectively reduces the post-treatment erythema of daylight-activated photodynamic therapy. *Br J Dermatol* 2016;174: 1422-1423.
- Schleichert R, Weiss E. Topical brimonidine gel as a hemostatic agent after dermatologic surgery. *Dermatol Surg* 2015; 41:872-873.
- Liu S, Carpenter RL, Chiu AA, McGill TJ, Mantell SA. Epinephrine prolongs duration of subcutaneous infiltration of local anesthesia in a dose-related manner. Correlation with magnitude of vasoconstriction. *Reg Anesth* 1995;20: 378-384.
- Carvalho Froes G, de Assis Ottoni F, Gontijo G. Topical anesthetics. *Surg Cosmet Dermatol* 2010;2:111-116.
- Covino BG. Pharmacology of local anaesthetic agents. *Br J Anaesth* 1986;58:701-716.
- Pöpping DM, Elia N, Marret E, Wenk M, Tramèr MR. Clonidine as an adjuvant to local anesthetics for peripheral nerve and plexus blocks: a meta-analysis of randomized trials. *Anesthesiology* 2009;111:406-415.
- Kroin JS, Buvanendran A, Beck DR, Topic JE, Watts DE, Tuman KJ. Clonidine prolongation of lidocaine analgesia after sciatic nerve block in rats is mediated via the hyperpolarization-activated cation current, not by alpha-adrenoceptors. *Anesthesiology* 2004;101:488-494.
- Eisenach JC, De Kock M, Klimscha W. Alpha(2)-adrenergic agonists for regional anesthesia. A clinical review of clonidine (1984-1995). *Anesthesiology* 1996;85:655-674.
- Kopacz DJ, Bernards CM. Effect of clonidine on lidocaine clearance in vivo: a microdialysis study in humans. *Anesthesiology* 2001;95:1371-1376.
- Burke J, Schwartz M. Preclinical evaluation of brimonidine. *Surv Ophthalmol* 1996;41 Suppl 1:59-18.
- Braun SA, Artzi O, Gerber PA. Brimonidine tartrate 0.33% gel for the management of posttreatment erythema induced by laser skin resurfacing. *J Am Acad Dermatol* 2017;76: e53-e55.
- Montague AJ, Bangh S, Cole JB. Bradycardia in a child after using brimonidine as toothpaste. *JAMA Dermatol* 2017;153: 330-331.
- Shagalov DR, Taylor D, Schleichert R, Weiss J, Weiss E. Association of central nervous system depression with topical brimonidine when used for hemostasis: a serious adverse event. *JAMA Dermatol* 2017;153:575-577.