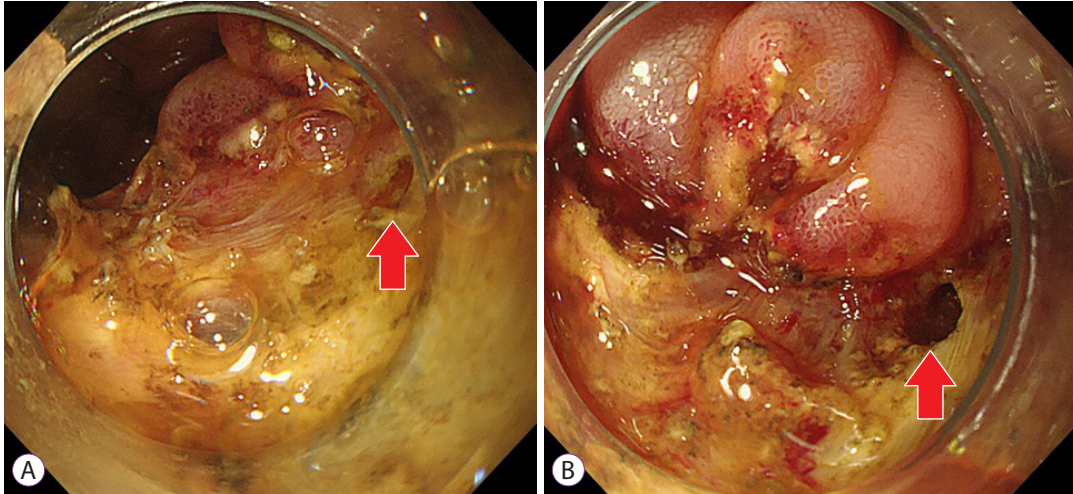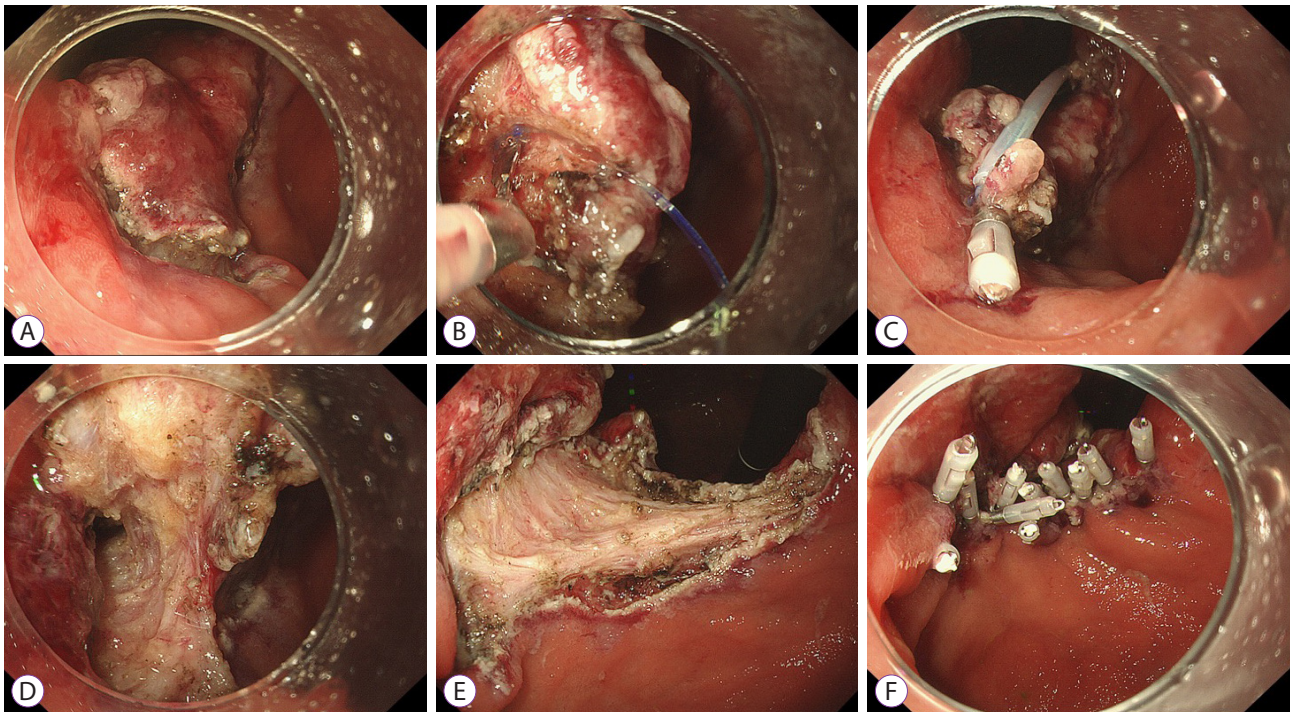


**Supplementary Fig. 1.** Perforation on the duodenal side. (A) Small perforation on the duodenal side (red arrow). (B) Perforation size progressively became larger (red arrow).



**Supplementary Fig. 2.** Technical tips for endoscopic submucosal dissection. (A) Make an incision close to the lesion on the duodenal side. (B-D) Perform the traction method on the duodenal side to facilitate access to the submucosal layer. (E, F) After resection, close the mucosal defect on the duodenal side.