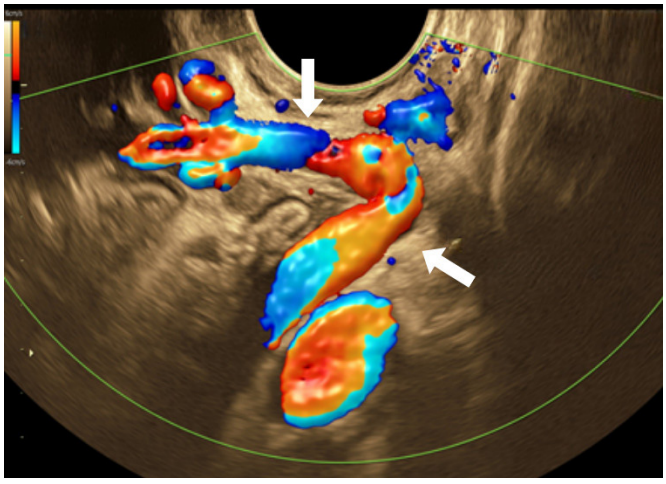

A

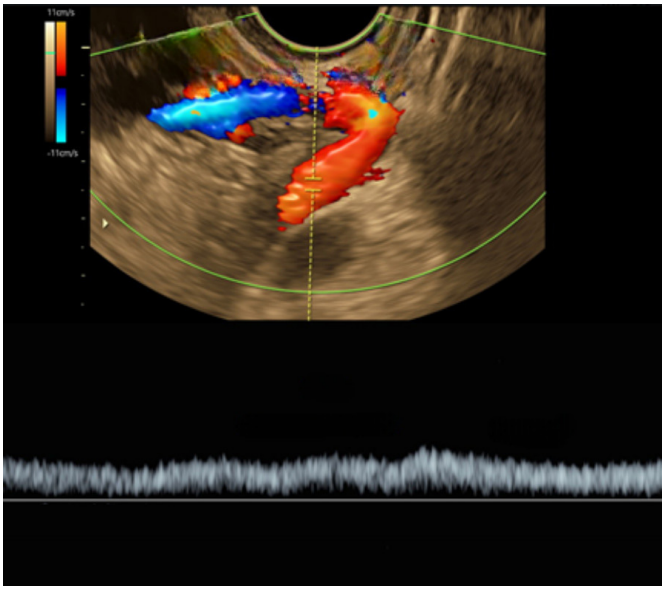

B

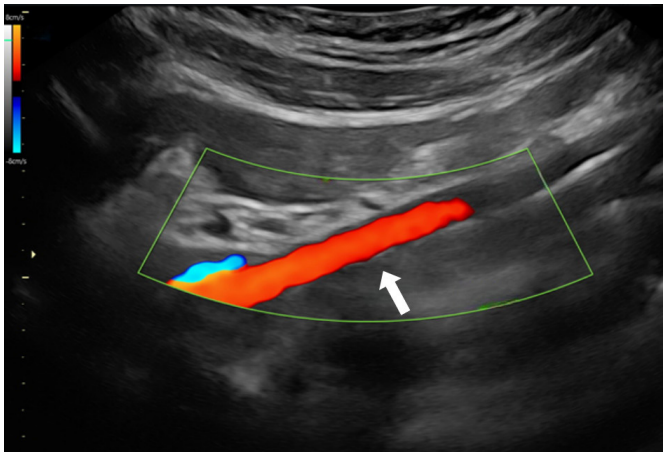

C

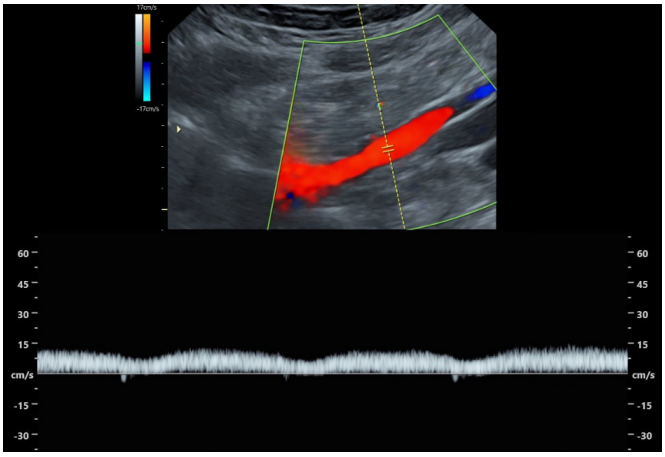

D

Supplementary Fig. 4. **Dilated left gonadal vein with reflux demonstrated on both transvaginal and transabdominal ultrasound.**
A. Color Doppler transvaginal ultrasound image shows a dilated distal segment of the left gonadal vein (arrows) with spontaneous venous flow. B. Spectral Doppler transvaginal ultrasound image confirms spontaneous retrograde flow in the distal segment of the left gonadal vein. C. Color Doppler transabdominal ultrasound image demonstrates a dilated proximal segment of the left gonadal vein (arrow) with spontaneous retrograde flow. D. Spectral Doppler transabdominal ultrasound image confirms retrograde flow in the proximal segment of the left gonadal vein.