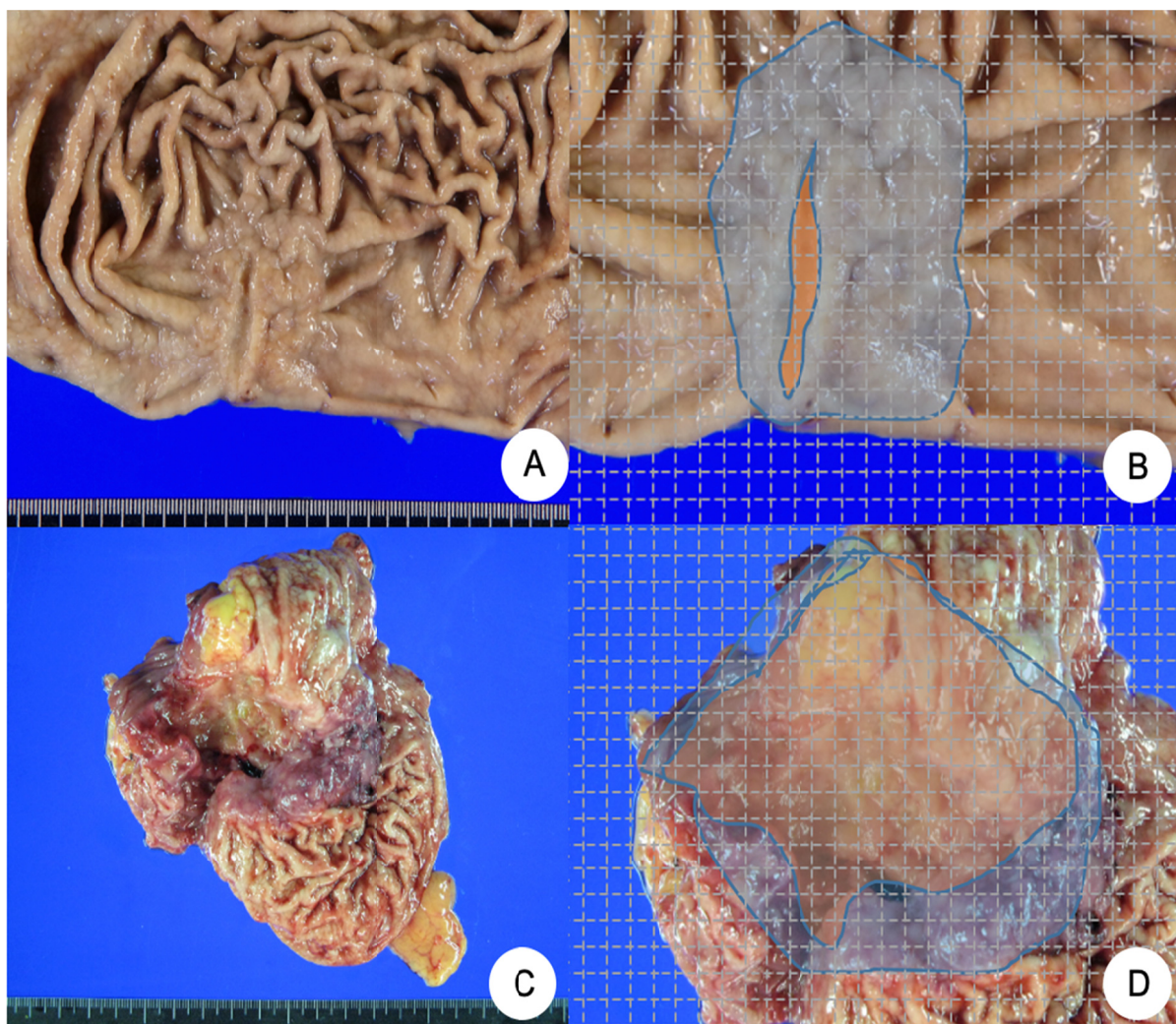


EXTREMELY WELL DIFFERENTIATED CARCINOMA



Supplementary Fig. S2. (A) A Borrmann type 3 extremely well-differentiated adenocarcinoma (EWDA) (case No. 10) is found in the body of the stomach. (B) A case of EWDA is quantified with 2-mm grid. Area of ulceration (orange) and area of tumor (blue) are delineated (case No. 10). (C) A Borrmann type 3 advanced gastric cancer is the antrum of stomach. (D) Both area of ulceration (orange) and area of tumor (blue).