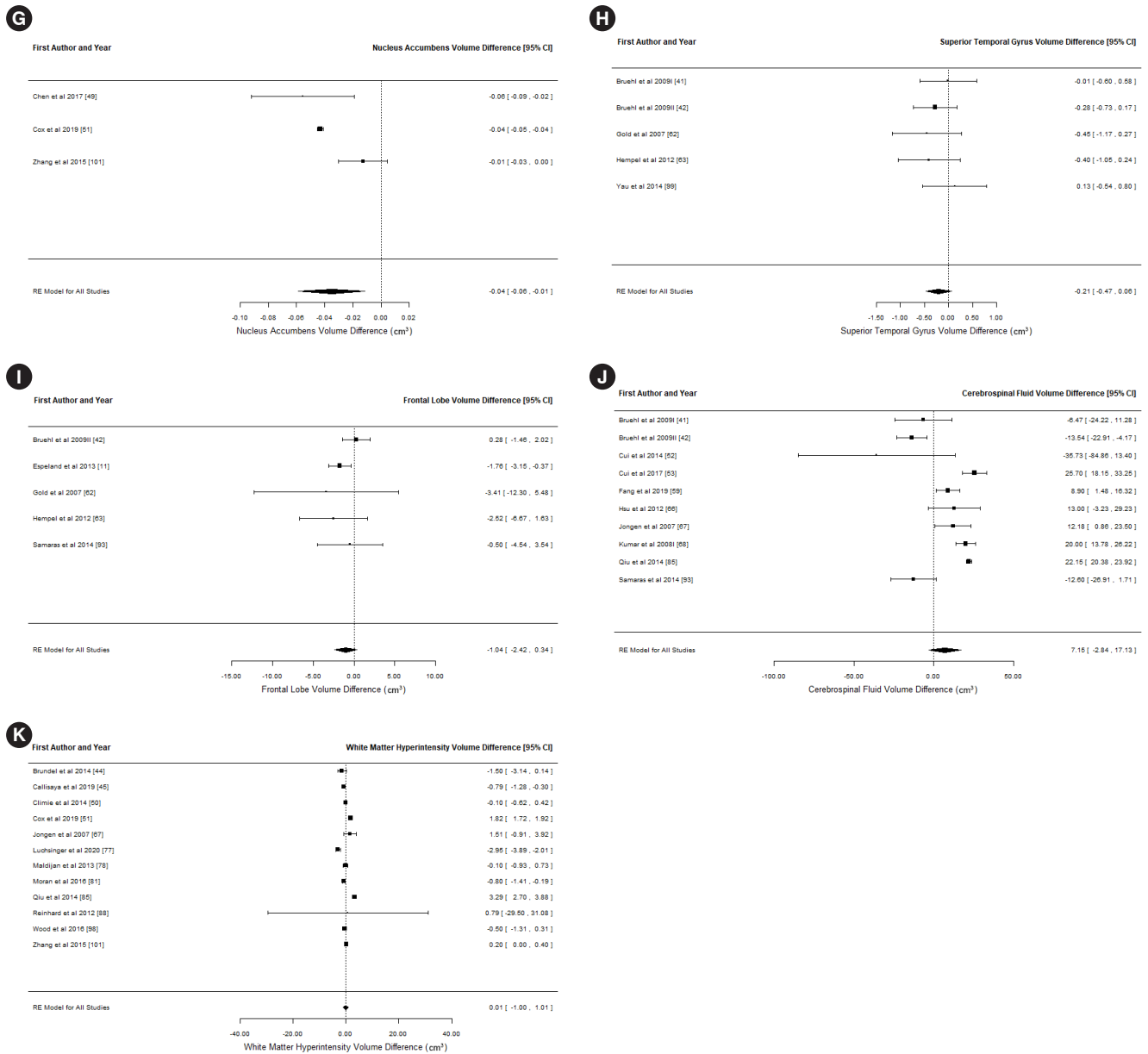


Supplementary Fig. 1. Forest plots of differences in local brain volumes between participants with and without type 2 diabetes mellitus. (A) Hippocampus, (B) caudate, (C) thalamus, (D) putamen, (E) globus pallidus, (F) amygdala, (G) nucleus accumbens, (H) superior temporal gyrus, (I) frontal lobe, (J) cerebrospinal fluid, and (K) white matter hyperintensity. CI, confidence interval. *(Continued to the next page)*



Supplementary Fig. 1. Continued.