



## Case Report

pISSN 2586-3290 · eISSN 2586-3533  
Arch Hand Microsurg 2020;25(3):201-206  
<https://doi.org/10.12790/ahm.20.0028>

Received: May 20, 2020

Revised: June 10, 2020

Accepted: June 11, 2020

### Corresponding author:

Si-Gyun Roh

Department of Plastic and  
Reconstructive Surgery, Jeonbuk  
National University Hospital, 20 Geonji-  
ro, Deokjin-gu, Jeonju 54907, Korea  
Tel: +82-63-250-1860

Fax: +82-63-250-1866

E-mail: [pssgroh@gmail.com](mailto:pssgroh@gmail.com)

ORCID:

<https://orcid.org/0000-0003-2865-0075>

## 정상적인 지질 수치를 보이는 환자의 사지에서 발생한 다발성 거대 건황색종

서두현<sup>1,2</sup>, 노시균<sup>1,2</sup>, 신진용<sup>1,2</sup>, 안문영<sup>1,2</sup>, 김종림<sup>1,2</sup>, 장석주<sup>1,2</sup>, 이내호<sup>1,2</sup>

<sup>1</sup>전북대학교 의과대학 성형외과학교실

<sup>2</sup>전북대학교 임상의학연구소-전북대학교병원 의생명연구원

## Multiple Huge Tendinous Xanthomas with Normal Lipid Profiles in All Extremities

Du-Heon Seo<sup>1,2</sup>, Si-Gyun Roh<sup>1,2</sup>, Jin Yong Shin<sup>1,2</sup>, Mun-Young An<sup>1,2</sup>,  
Jong-Lim Kim<sup>1,2</sup>, Suk Choo Chang<sup>1,2</sup>, Nae-Ho Lee<sup>1,2</sup>

<sup>1</sup>Department of Plastic and Reconstructive Surgery, Jeonbuk National University Medical School, Jeonju, Korea

<sup>2</sup>Research Institute of Clinical Medicine of Jeonbuk National University-Biomedical Research Institute of Jeonbuk National University Hospital, Jeonju, Korea

Xanthomas are grayish-yellow masses composed of lipid-filled foamy histiocytes and are usually accompanied by familial hypercholesterolemia or some other disease associated with dysfunctional lipid metabolism. Here, we report a case of multiple huge tendinous xanthomas with normal lipid profiles involving all extremities. These masses were large enough to cause pain, dysfunction of extremities, and cosmetic compromise and the condition was accompanied by cerebrotendinous xanthomatosis. Due to the presence of many masses in all extremities, a two-stage operation was planned with a time gap of several months. At 1-month follow-up visits after first and second surgeries, although extension of the left middle finger was poor as a result of sacrificing the 3rd extensor digitorum communis tendon, no problems such as wound dehiscence, hematoma formation, or infection at operative sites were noted.

**Keywords:** Cerebrotendinous xanthomatosis, Tendinous xanthoma, Hypercholesterolemia

## INTRODUCTION

Xanthomas are grayish-yellow masses composed of lipid-filled foamy histiocytes, extracellular cholesterol, giant cells, and inflammatory cells [1], and are usually caused by cholesterol accumulation in familial hypercholesterolemia or some other diseases and may be the mainstay of the clinical diagnoses of these lipid disorders [2]. Xanthomas usually involve skin and subcutaneous tissue, and sometimes involve tendon and bone deeply [3-5]. Tendinous xanthoma usually involves hand extensor tendons, but may also be found on elbow, patella, and Achilles tendons. Several tendinous xanthomas have been reported and are known to be associated with a clinical finding of hyperlipidemia [2,3].

A few case reports have been issued on xanthomas with a normal lipid profile, most concerned plane xanthoma [5] and others tendinous xanthoma of Achilles tendon [6]. Here, we report a rare case of huge multiple tendinous xanthomas in

all extremities with a normal lipid profile that were large enough to cause pain, motor disturbance, and poor cosmesis.

Written informed consents was received from the patient for this report.

## CASE REPORT

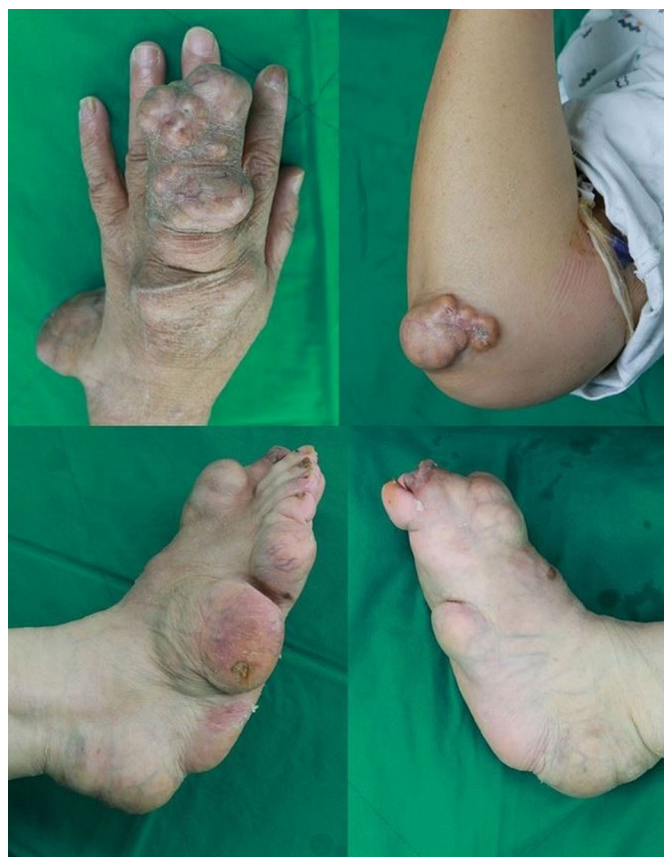A 68-year-old female patient visited our clinic with a 20-year history of progressively enlarging multiple masses on all extremities (Fig. 1). The patient complained of pain while walking due to multiple huge masses in both feet and motor dysfunction of left middle finger due to huge mass arising from the 3rd extensor digitorum communis (EDC) tendon. She had no systemic symptoms.

Magnetic resonance imaging (MRI) of the left hand showed masses with central necrosis infiltrating the tendon of flexor carpi ulnaris (FCU), flexor pollicis longus (FPL), and the 2nd~ to 4th EDC without definitive involvement of ulnar nerve or artery (Fig. 2). On her right foot, multiple large masses with central necrosis were scanned on the Achilles, peroneus, extensor hallucis

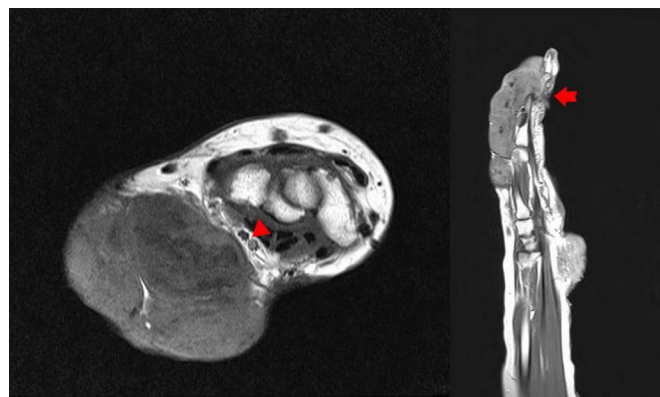
longus (EHL), tibialis posterior, and tibialis anterior tendons, and on the left foot, Achilles, flexor hallucis longus (FHL), and EHL tendons were infiltrated by masses. Incisional biopsy of some masses on the left hand and foot revealed they were composed of lipid, foam cells, histiocytes, and lymphocytes (Fig. 3).

Serum cholesterol and triglyceride levels were in normal ranges. Several additional tests were performed to determine the underlying cause.

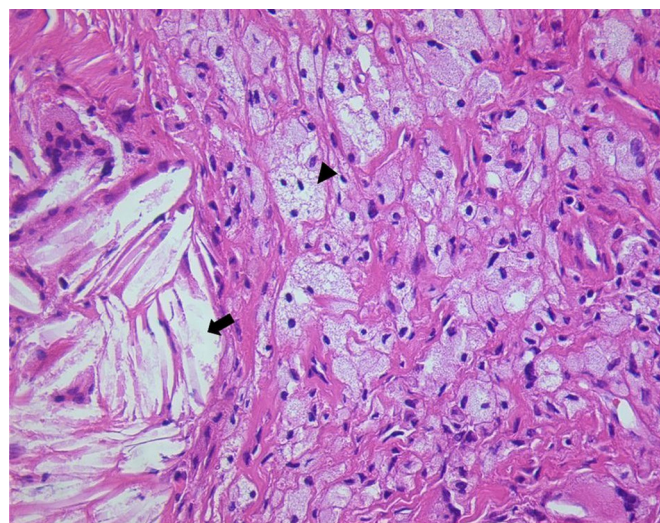
Laboratory testing revealed a serum cholestanol level of 10.11  $\mu\text{g/mL}$ , which confirmed a diagnosis of cerebrotendinous xanthomatosis (CTX) (Table 1). After CTX had been diagnosed, brain MRI was performed but there was no evidence of lipid accumulation in brain parenchyma.



**Fig. 1.** The large, firm nontender masses with ulceration were on tendons of left hand, right elbow, both ankles and feet.



**Fig. 2.** In T1-weighted image, xanthoma infiltrated into the tendon of flexor carpi ulnaris was seen in left wrist. There was no definitive involvement of ulnar nerve and artery (arrowhead). The 2nd to 4th extensor tendons were involved by the xanthoma on the left dorsum of hand (arrow).



**Fig. 3.** Histopathology finding showing lipid accumulation (arrow), foam cell (arrowhead), histiocytes, and lymphocytes (H&E,  $\times 400$ ).

Due to the presence of many disfiguring masses in all extremities, a two-stage operation was planned with a time gap of several months. The upper extremities were operated on first, and lower extremities were addressed during second surgery. Subtotal excision for the masses was done to preserve most tendons and normal function (Fig. 4). However, masses arising from 3rd EDC of the left hand and EHL of both feet (Fig. 5) were completely excised and tendons were sacrificed due to severe infiltration. Biopsy after surgery resulted in diagnoses of tuberous xanthoma for all masses.

No problems such as wound dehiscence, hematoma formation, or infection at operative sites were noted at 1-month follow-up visits after first and second surgeries, although exten-

sion of the left middle finger was poor as a result of sacrificing the 3rd EDC tendon (Fig. 6).

The written informed consent to publish these case details was obtained from the patient.

## DISCUSSION

Xanthomas are composed of cholesterol-rich materials and can occur anywhere. They usually accompany familial hypercholesterolemia, though some case reports have described xanthoma in patients with a normal plasma lipid profile [5,6]. Xanthomas usually occur in association with another diseases or syndromes such as CTX, beta sitosterolemia, or overproduction of apolipoprotein B [6-8].

Tendon xanthoma should always be considered in patients with multiple extensor tendon invasions and hypercholesterolemia. However, there is a high possibility of confusing xanthoma with lipoma, nodular tenosynovitis, rheumatoid nodule, or calcinosis cutis [3] when serum lipid profiles are normal, as was observed in our case. Accordingly, proper preoperative imaging, testing, and biopsy are required to determine disease extent and mass characteristics. In our case, xanthoma was confirmed by preoperative biopsy and by extensive invasions of Achilles and multiple extensor tendons of hands as visualized by MRI. Serum cholesterol and cholestanol levels confirmed CTX in our patient.

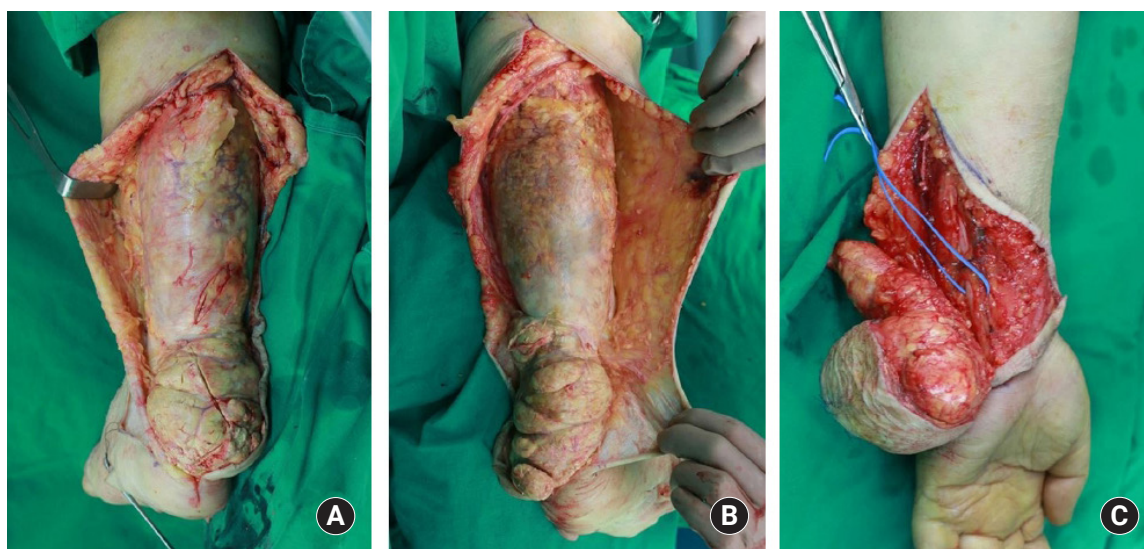
CTX is an autosomal recessive disorder of bile acid synthesis and was first described in 1937. Deficiency of mitochon-

**Table 1.** Lipid profile of patient<sup>a)</sup>

Variable	Value	Normal range
Cholesterol (mg/dL)		
Total	137	< 200
HDL	40	> 50 (female)
LDL	84	< 140
Triglycerides (mg/dL)	144	< 200
TC/HDL	3.425	
LDL/HDL	2.1	
Apoprotein A1 (g/L)	1.31	1.08–2.25
Apoprotein B (g/L)	0.76	0.60–1.17
Cholestanol (μg/mL)	10.11	< 5

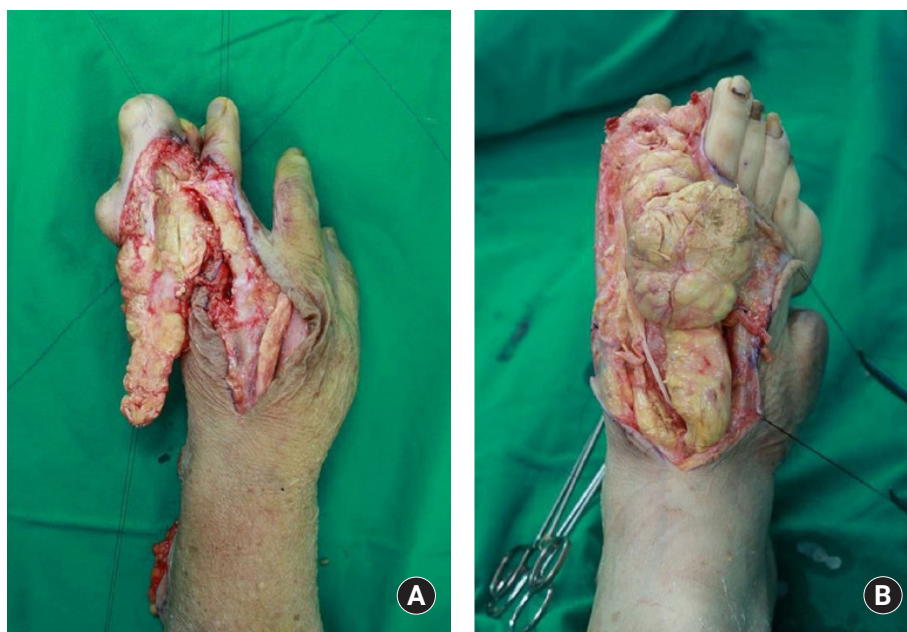HDL, high-density lipoprotein; LDL, low-density lipoprotein; TC, total cholesterol.

<sup>a)</sup>Body mass index of the patient: 30.81 kg/m<sup>2</sup>.



**Fig. 4.** During subtotal excision for mass on the left wrist, ulnar nerve and artery was not involved and preserved (A). (B, C) For the large masses were on both Achilles tendon, subtotal excision was done preserving Achilles tendon.



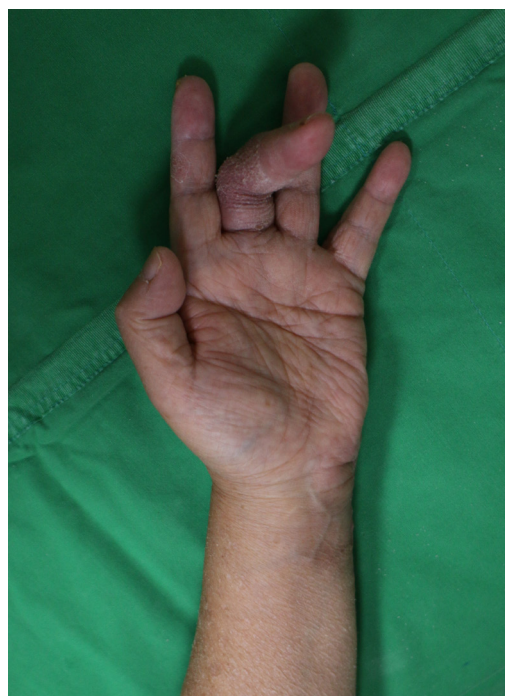

**Fig. 5.** The masses involved in 3rd extensor digitorum communis tendon (A) and both tendons of extensor hallucis longus (B) was completely excised and then tendons were sacrificed due to severe infiltration into the tendons.

drial enzyme sterol 27-hydroxylase leads to excessive cholesterol and cholesterol production and accumulations of these sterols in several tissues. CTX is characterized by intractable diarrhea, neurologic abnormalities, and tendinous xanthomas, especially in Achilles tendons. Sterol analysis or electroimmunoassay is required for the identification of this disease [7].

Several treatment options are available for tendon xanthoma, for example, it could be treated by tendon reconstruction with complete excision, subtotal excision, or amputation. Although Achilles tendon reconstruction or complete tendon removal or amputation have been reported for the treatment of large foot lesions [9], considerations of degree of invasion, functional outcomes, and patient willingness may favor subtotal excision with conservative treatment because total excision for masses with severe invasion on tendons may lead to motor dysfunction sequelae [3]. Of course, subtotal excision may be associated with recurrence, but appropriate medical treatment could prevent or delay this eventuality [10].

In conclusion, xanthoma can occur anywhere and usually accompanies familial hypercholesterolemia. Unlike previous reports, we describe an extremely rare case involving extensive invasion by multiple huge xanthomas in all extremities that caused motion disability and poor cosmesis in a patient with a normal lipid profile that responded satisfactorily to subtotal mass excision.



**Fig. 6.** Extension of the left middle finger was poor as a result of sacrificing the 3rd extensor digitorum communis tendon after surgery.

## CONFLICTS OF INTEREST

The authors have nothing to disclose.

## REFERENCES

1. Bude RO, Adler RS, Bassett DR. Diagnosis of Achilles tendon xanthoma in patients with heterozygous familial hypercholesterolemia: MR vs sonography. *AJR Am J Roentgenol.* 1994; 162:913-7.
2. Kruth HS. Lipid deposition in human tendon xanthoma. *Am J Pathol.* 1985;121:311-5.
3. Doyle JR. Tendon xanthoma: a physical manifestation of hyperlipidemia. *J Hand Surg Am.* 1988;13:238-41.
4. Wang Z, Lin ZW, Huang LL, et al. Primary non-hyperlipidemia xanthoma of bone: a case report with review of the literature. *Int J Clin Exp Med.* 2014;7:4503-8.
5. Lu YT, Chen TJ, Chung WH, Kuo TT, Hong HS. Cutaneous normolipemic plane xanthoma with supraglottic involvement in a patient with hand-Schüller-Christian disease a case report. *Am J Clin Dermatol.* 2009;10:189-92.
6. Fleischmajer R, Tint GS, Bennett HD. Normolipemic tendon and tuberous xanthomas. *J Am Acad Dermatol.* 1981;5:290-6.
7. Verrips A, van Engelen BG, Wevers RA, et al. Presence of diarrhea and absence of tendon xanthomas in patients with cerebrotendinous xanthomatosis. *Arch Neurol.* 2000;57:520-4.
8. Vega GL, Illingworth DR, Grundy SM, Lindgren FT, Connor WE. Normocholesterolemic tendon xanthomatosis with overproduction of apolipoprotein B. *Metabolism.* 1983;32:118-25.
9. Jones FE, Soule EH, Coventry MB. Fibrous xanthoma of synovium (giant-cell tumor of tendon sheath, pigmented nodular synovitis). A study of one hundred and eighteen cases. *J Bone Joint Surg Am.* 1969;51:76-86.
10. Wilkes LL. Tendon xanthoma in type IV hyperlipoproteinemia. *South Med J.* 1977;70:254-5.

## 정상적인 지질 수치를 보이는 환자의 사지에서 발생한 다발성 거대 건황색종

서두헌<sup>1,2</sup>, 노시균<sup>1,2</sup>, 신진용<sup>1,2</sup>, 안문영<sup>1,2</sup>, 김종림<sup>1,2</sup>, 장석주<sup>1,2</sup>, 이내호<sup>1,2</sup>

<sup>1</sup>전북대학교 의과대학 성형외과학교실, <sup>2</sup>전북대학교 임상의학연구소-전북대학교병원 의생명연구원

황색종은 지질이 쌓인 조직구를 포함하는 회-황색의 종양 조직으로 주로 가족성 고콜레스테롤혈증 또는 다른 이상지질혈증 등에서 주로 발생하게 된다. 그러나 우리는 정상적인 지질 수치를 보이는 환자의 모든 사지에 발생한 다발성 거대 건황색종을 희귀한 증례로서 보고하고자 한다. 이 황색종들은 수족의 기능 저하 및 통증을 동반했고 외관적으로 예후가 불량할 정도로 크기가 매우 컸는데, 뇌건성 황색종증과 함께 발생한 것으로 진단되었다. 사지에 많은 황색종들이 있어 수개월의 차이를 두고 단계적으로 수술을 계획하고 시행하였다. 수술 후 경과 관찰에서 좌측 세 번째 수지신근 완전 절제로 인한 좌측 중지의 신전 장애를 제외하고는 특이사항을 보이지 않았다.

**색인단어:** 뇌건성 황색종증, 건황색종, 고콜레스테롤혈증

**접수일** 2020년 5월 20일 **수정일** 2020년 6월 10일 **게재확정일** 2020년 6월 11일

**교신저자** 노시균

54907, 전주시 덕진구 건지로 20, 전북대학교병원 성형외과

**TEL** 063-250-1860 **FAX** 063-250-1866 **E-mail** pssroh@jbnu.ac.kr

**ORCID** <https://orcid.org/0000-0003-2865-0075>