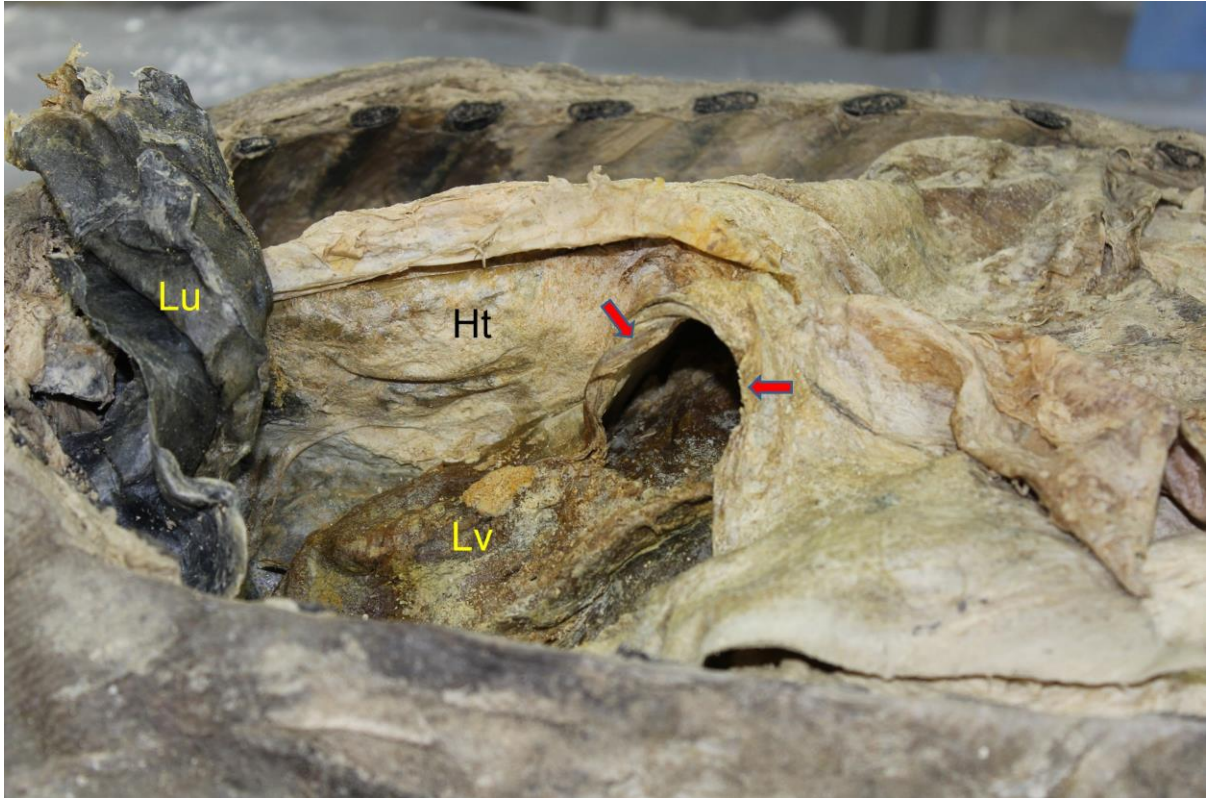


Supplementary Fig. 1. Autopsy view in 2013. A part of liver (Lv) protruded into right thoracic cavity through the posterolateral defect of the diaphragm (indicated by arrows). A view from right lateral side. Lu, lung; Ht, heart.



Supplementary Fig. 2. Autopsy view in 2013. Right thoracic cavity and heart (Ht). Liver (Lv) protruded into right thoracic cavity. A front view. Pc, pericardium; Lu, lung.