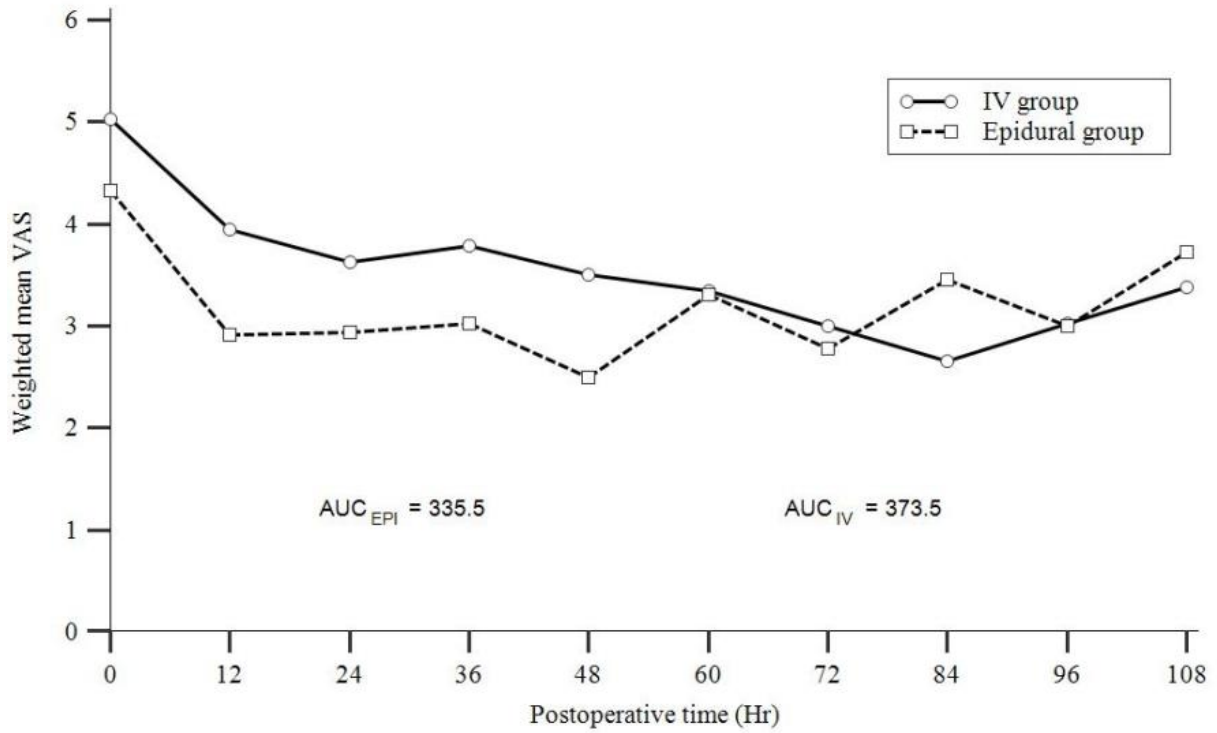


Supplementary Fig. 4. AUC graph of weighted mean VAS of epidural group and IV group including two retrospective studies which met our inclusion criteria except study type, and data could be retrieved[1,2].



VAS, visual analog scale; AUC, area under the curve; IV, intravenous; Hr, hour.

1. Reinoso-Barbero F, Fernández A, Durán P, Castro LE, Campo G, Melo MM. [Thoracic epidural analgesia vs patient-controlled analgesia with intravenous fentanyl in children treated for pectus excavatum with the Nuss procedure]. *Rev Esp Anesthesiol Reanim* 2010; 57:214-9.
2. Soliman IE, Apuya JS, Fertil KM, Simpson PM, Tobias JD. Intravenous versus epidural analgesia after surgical repair of pectus excavatum. *Am J Ther* 2009;16:398-403.