

# Effects of Magnoliae Cortex and Zizyphi Fructus Extract Mixtures on the Progression of Experimental Periodontitis in Beagle Dogs

Seung-Yun Shin<sup>1</sup> · Yong-Moo Lee<sup>1</sup> · Young-Ku<sup>1</sup> · In-Chul Rhyu<sup>1</sup>  
Soo-Boo Han<sup>1</sup> · Sang-Mook Choi<sup>1</sup> · Ki-Hwan Bae<sup>2</sup> and Chong-Pyoung Chung<sup>1</sup>

<sup>1</sup>Department of Periodontology, College of Dentistry, Seoul National University

<sup>2</sup>College of Pharmacy, Chungnam National University

## I. Introduction

Periodontal disease is an inflammatory process caused by periodontopathic microorganisms in dental plaque. Numerous studies have interested in the use of antimicrobial agents to eradicate or decrease number of putative periodontal pathogenic microorganisms. Another approach has focused on the use of chemotherapeutic agents to modulate the host response.

In the view of general reluctance to use antibiotics for the treatment of chronic infections with such a wide prevalence, interest has been directed largely towards the antiseptics. Most commonly used antiseptics in clinical periodontics are bisbiguanides, phenolic compounds, quaternary ammonium compounds, and etc. While these agents have been used for many years, they have exhibited many drawbacks such as tooth staining, development of resistant strains and desquamation of oral epithelium<sup>1-3</sup>.

Systemic non-steroidal anti-inflammatory drugs (NSAIDs) therapy have been shown to arrest

periodontal disease progression in animal models<sup>4-7</sup> and clinical trials<sup>8-11</sup>). Although relative low dose systemic NSAIDs therapy has been successfully used to slow the rate of periodontal disease progression, its use also involves side effects such as gastrointestinal trouble<sup>12</sup>).

In a previous study, it was suggested that magnolia and honokiol isolated from the stem bark of *Magnolia obovate* Thunb. have a significant antimicrobial activity against periodontopathic bacteria<sup>13</sup>). It was reported that *Zizyphi fructus* extract may prevent glucan production by cariogenic bacteria<sup>14</sup>) and prevent production of IL-1 $\beta$  and PGE<sub>2</sub><sup>15, 16</sup>).

This study focuses on the effect of oral administration of *Magnoliae cortex* and *Zizyphi fructus* extract mixtures on the disease progression in beagle dogs with ligature-induced experimental periodontitis.

## II. Material and Methods

### 1. Preparation of magnolia cortex and

## Zizyphi fructus extracts mixture

Magnoliae cortex(1kg) was extracted with ethanol 2500ml for 2hours on water bath. After filtration, the filter cake was extracted once again. The combined filtrates were concentrated to dried mass, and the ethanol extract(120g) was used for the experiment. Zizyphi fructus(2,5kg) was extracted with ethanol 5000ml for 3hrs on water bath. After filtration, the filter cake was extracted once again. The combined filtrates were concentrated to dried mass, and the ethanolic extract(1,2kg) was used for the experiment. Then the two extracts were mixed and capsuled in 500mg unit.

## 2. Animals

Six beagle dogs(3 males and 3 females) weighing about 13kg each were employed in this study. During the pretreatment phase, all dogs brought to optimal periodontal health with subgingival scaling and with daily toothbrushing with pumice. Plaque control continued over 14 days until all dogs exhibited no sites which showed bleeding on probing and pocket depths over 3mm.

## 3. Study design

Fourteen teeth from each animal were used for study: maxillary 2nd, 3rd premolars and 4th premolar and the mandibular 2nd, 3rd, 4th premolars and 1st molar. Pretreatment measures(-8 weeks) on these teeth included the Plaque index (PI)<sup>17</sup>, Gingival index(GI)<sup>18</sup>, clinical attachment level(CAL)(using Florida Probe<sup>®</sup>) and gingival crevicular fluid volume(GCF). Subgingival plaque sampling of all experimental teeth was also performed with paper points before all other clinical

indexes were taken. Clinical index scores were assessed at the mesiobuccal, midbuccal, distobuccal side of experimental teeth. GCF was also collected at the midbuccal side of maxillary 3rd premolars and mandibular 4th premolars using Periotron 8000 and periopapers. After all the data were collected, wire and silk braded ligatures were then tied around the experimental teeth on each animal, and the dogs were placed on a soft diet chow to induce artificial periodontitis through accumulation of plaque and calculus. Eight weeks after ligation(baseline measurements: 0 week), ligature wire and silk was removed and then plaque samples, PI, GI, CAL and GCF were again obtained. The animals with experimental periodontitis were then randomly divided into 2 groups: 1)As a test group(MZM), 3 beagles were administered Magnoliae cortex and Zizyphi fructus extract mixture; 2) The remaining 3 beagles were used as a negative control group(NC) and as such did not receive any drugs. 0.5g of Magnoliae cortex and Zizyphi fructus extract mixture was enclosed in a capsule and the drug and placebo for control groups were administered orally, two capsules twice a day. At 2, 4, 6 and 8 weeks after initiation of administration, plaque samples, PI, GI, CAL and GCF were obtained again.

## 4. Statistical analysis

The data analysis is based on repeated measures over weeks with the 2 groups. The comparisons between pretreatment and baseline measures and between baseline and each time point measures on PI, GI, PD and GCF were analyzed with Analysis of Variance(ANOVA). The effects of treatments with each drug on all measures at each time point were analyzed with t-test. Statistical differences were determined at the values of  $P < 0.05$ .

### III. Results

At pretreatment measurements, PI, GI, CAL and GCF were not statistically different among two groups. After 8 weeks with ligature in place and no oral hygiene, all clinical scores begin to increase quickly.

Changes in the mean PI scores over the course of

Table 1. Plaque index

Week	NC	MZM
-8	0,24±0,23	0,49±0,27
0	1,75±0,43*	1,91±0,52*
2	1,96±0,43	1,49±0,42
4	2,52±0,44	1,69±0,52
6	2,08±0,80	1,74±0,28
8	2,02±0,33	1,74±0,24

NC : Negative control, MZM : Magnoliae cortex and Zizyphi fructus extract mixture

\*:P<0,05, significant differences in -8 (before ligation) and 0 weeks(baseline)

No significant difference were found between each time point and baseline in all groups

No significant difference were found between two groups at each time point.

Table 2. Gingival index,

Week	NC	MZM
-8	0,40±0,07	0,52±0,22
0	1,20±0,25*	1,61±0,14*
2	1,67±0,33	1,63±0,28
4	2,51±0,31 <sup>#</sup>	1,88±0,21 <sup>#</sup>
6	2,48±0,32 <sup>#</sup>	1,47±0,27 <sup>#</sup>
8	2,63±0,35 <sup>#</sup>	1,36±0,18 <sup>#</sup>

NC : Negative control, MZM : Magnoliae cortex and Zizyphi fructus extract mixture

\*significant differences in -8 (before ligation) and 0 weeks (baseline) (P<0,05)

<sup>#</sup>significantly different from baseline at each time period (P<0,05)

<sup>#</sup>significantly different between two groups at each time point (P<0,05)

the study are shown in table 1 and figure 1. After ligatures were removed at baseline, mean PI scores were not reduced and remained high in both groups throughout all examined period. Because the beagle dogs did not receive any oral hygiene procedures, significant plaque and calculus were deposited. No statistically significant difference was found between two groups.

Table 3. Clinical attachment level(mm)

Week	NC	MZM
-8	1,61±0,33	1,78±0,39
0	2,42±0,46*	2,63±0,37*
2	2,75±0,74	2,22±0,14
4	2,79±0,75	2,18±0,29 <sup>#</sup>
6	3,32±0,36 <sup>#</sup>	1,84±0,24 <sup>#</sup>
8	3,41±0,47 <sup>#</sup>	1,67±0,32 <sup>#</sup>

NC : Negative control, MZM : Magnoliae cortex and Zizyphi fructus extract mixture

\*significant differences in -8 (before ligation) and 0 weeks (baseline) (P<0,05)

<sup>#</sup>significantly different from baseline at each time period (P<0,05)

<sup>#</sup>significantly different between two groups at each time point, (P<0,05)

Table 4. Gingival crevicular fluid

Week	NC	MZM
-8	41,50±12,34	57,43±18,31
0	78,88±10,01*	75,88±11,33*
2	73,25±16,58	76,00±15,32
4	84,25±20,34	64,38±13,52
6	81,00±28,23 <sup>#</sup>	52,50±17,48 <sup>#</sup>
8	80,00±25,45 <sup>#</sup>	50,88±18,64 <sup>#</sup>

NC : Negative control, MZM : Magnoliae cortex and Zizyphi fructus extract mixture

\*significant differences in -8 (before ligation) and 0 weeks (baseline) (P<0,05)

<sup>#</sup>significantly different from baseline at each time period (P<0,05)

<sup>#</sup>significantly different between two groups at each time point (P<0,05)

Changes in the mean GI scores throughout the period of study are demonstrated in table 2 and figure 2. While the mean GI scores of NC(negative control) group continuously increased throughout all examined period, those of MZM(Magnoliae cortex and Zyziphi frutus mixtures) group was dropped after 4 weeks and significantly lower than

control group at 6 and 8 weeks.

Table 3 and figure 3 demonstrate the CAL changes throughout all examined period. Over the 8 week medication period, MZM group showed 0.97 mm of mean gain in CAL respectively, while NC group showed 0.99 mm of loss. The mean CAL of MZM group was significantly lower than that of

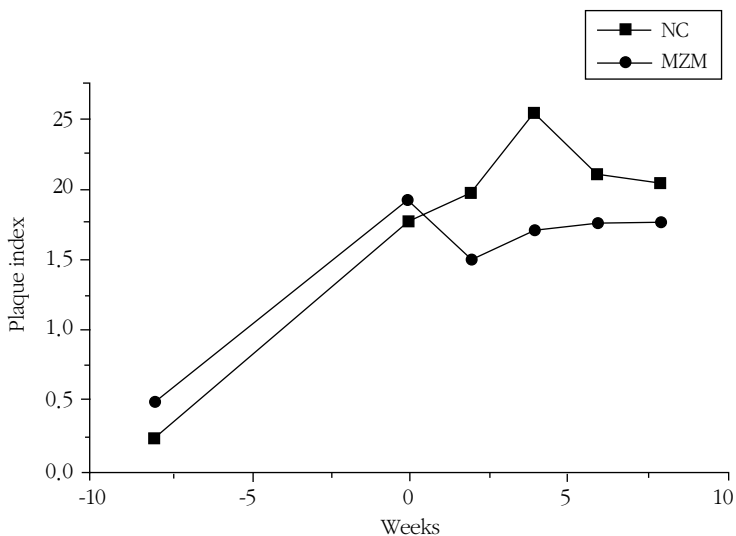


Figure 1. Plaque index

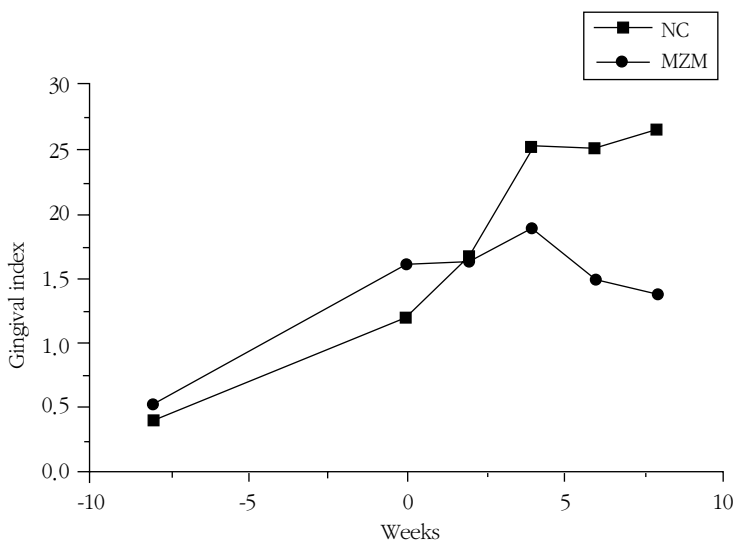


Figure 2. Gingival index

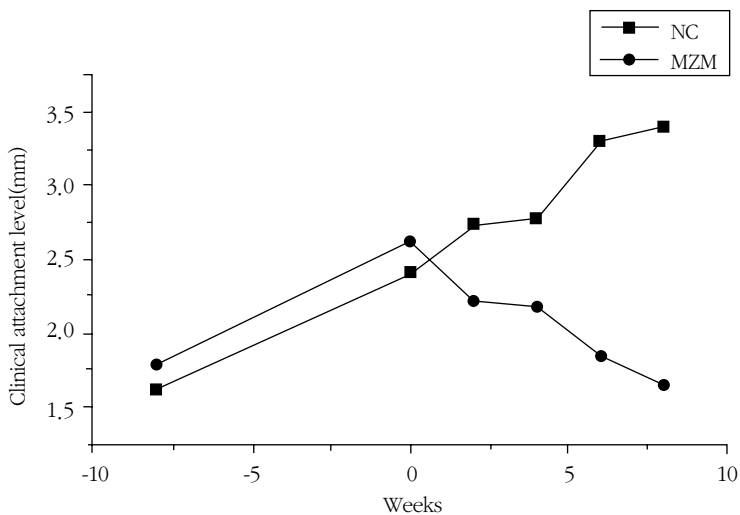


Figure 3. Clinical attachment level

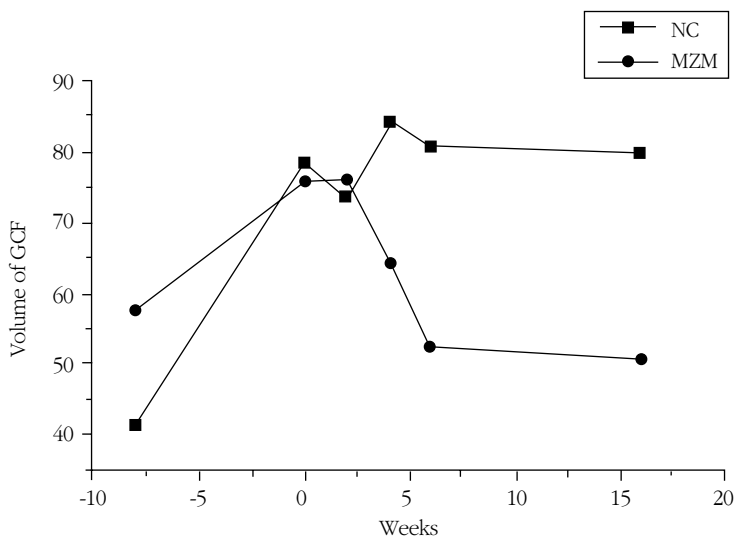


Figure 4. Volume of GCF

NC group at 4, 6 and 8 weeks.

The GCF levels are demonstrated in table 4 and figure 4. The mean volumes of GCF in NC group showed some fluctuation. However, the mean volumes of GCF in MZM group continuously decreased from baseline to 8 weeks. MZM group showed the significant lower values than NC group

at 6 and 8 weeks.

#### IV. Discussion

In a previous study, magnolol and honokiol, the main component of Magnoliae cortex, showed a significant antimicrobial activity against

periodontopathic microorganisms and a relatively low cytotoxic effect on human gingival cells<sup>13</sup>). It was also reported that Zizyphi fructus extract might have some antimicrobial and antiinflammatory effects<sup>14-16</sup>). The present study was designed to examine the effect of oral administration of Magnoliae cortex and Zizyphi fructus extract mixtures on the disease progression in beagle dogs with ligature-induced experimental periodontitis..

To inhibit alveolar bone loss resulting from periodontal disease progression in human, some kinds of NSAIDs have been introduced<sup>8-11</sup>). Waite et al.<sup>8</sup>) compared the periodontal status of a group of 22 subjects who had been taking a variety of NSAIDs for at least 1 year to that of an equal number of control subjects. Their observations showed that reduced gingival index scores and probing pocket depths were associated with NSAIDs therapy and there was also a trend towards a reduced loss of attachment. But, the side effect of NSAIDs use such as gastric disturbances has deterred with its wide use for treatment of only periodontitis.

Many investigators have sought some new drug from natural extracts that would replace the previously used agents, such as antibiotics and antiinflammatory drugs. Among them, sanguinaria-containing products have received extensive attention. Clinically meaningful and statistically lower gingival bleeding on probing scores were obtained with combined use of sanguinaria and zinc chloride containing tooth paste and oral rinse<sup>19</sup>). In this study, the mixture of Magnolia cortex and Zizyphi fructus extract showed significant effect on reducing gingival inflammation, clinical attachment level and gingival crevicular fluid level. These results might be due to the antimicrobial effect against periodontopathic microorganisms of magnolol and honokiol<sup>13</sup>) and anti-inflammatory

effect of Magnolia cortex and Zizyphi fructus extract by inhibition of PGE<sub>2</sub> production<sup>15,16</sup>).

Taken together, these results indicated that the oral administration of mixture of Magnolia cortex and Zizyphi fructus extracts would be highly effective to slowing the destruction of periodontal tissue in beagles with periodontitis, and that this mixture might be potentially useful as a drug for prevention and treatment of periodontitis.

## V. Conclusion

In this study, mixture of extracts of Magnoliae cortex and Zizyphi fructus was employed to test the effect of disease progression in beagle dogs with ligature induced experimental periodontitis. This study implied that the oral administration of mixture of Magnolia cortex and Zizyphi fructus extract mixture should be highly effective in slowing destruction of periodontal tissue in beagles with periodontitis, and that this mixture might be a potentially useful as a drug for prevention and treatment of periodontitis.

## VI. Reference

1. Greenstein G, Berman C, Jaffin R : An adjunct to periodontal therapy. *J. Periodontol.* 1986, 57, 370-377
2. Goldschmidt P., Cogen R., Taubman S. Cytopathologic effects of chlorhexidine on human cells. *J Periodontol* 1977 48:212-215
3. Gordon JM, Lamster IB, Seiger MC : Efficacy of Listerine antiseptic in inhibiting the development of plaque and gingivitis *J Clin Periodont* 1985 12:697-704
4. Nyman S, Schroeder HE, Lindhe J: Suppression of inflammation and bone resorption by indomethacin during

- experimental periodontitis in dogs, J. Periodontol, 1979, 50, 450-461
5. Williams RC, Jeaffcoat MK, Kaplan ML, Goldhaber P, Johnson HG, Wechter WJ Flurbiprofen: a potent inhibitor of alveolar bone resorption in beagles. Science, 1985, 227, 640-642
  6. Howell TH, Jeffcoat MK, Goldhaber P, Reddy MS, Kaplan ML, Johnson HG, Hall CM, Williams RC : Inhibition of alveolar bone loss in beagles with the NSAID naproxen. J Periodont Res 1991 26:498-501.
  7. Offenbacher S, Williams RC, Jeaffcoat MK, Howell TH, Odle BM, Smith MA, Hall CM, Johnson HG, Goldhaber P. Effects of NSAIDs on beagle crevicular cyclooxygenase metabolites and periodontal bone loss. J. Periodont. Res, 1992, 27, 207-213.
  8. Waite IM, Saxton CA, Young A, Wagg BJ and Corbett M: The periodontal status of subjects receiving non-steroidal anti-inflammatory drugs J Periodontal Res 1981, 16:100-108
  9. Williams RC, Jeaffcoat MK, Howell Th, Rolla A, Stubbs D, Teoh KW, Reddy MS, Goldhaber P : Altering the progression of human alveolar bone loss with the non-steroidal anti-inflammatory drug Flurbiprofen, J Periodontol 1989 60:485-490
  10. Heasman PA, Seymour RA. An association between long-term non-steroidal anti-inflammatory drug therapy and the severity of periodontal disease J. Clin. Periodontol, 1990, 17, 654-658.
  11. Taiyeb Ali TB, Waite IM. The effect of systemic ibuprofen on gingival inflammation in humans J. Clin. Periodontol. 1993, 20, 723-728.
  12. Arky R (ed) Physicians Desk Reference, Montvale NJ (1994) pp 2350, 2393, 1415, 1792, 1755, 2373
  13. Chang BS, Lee YM, Ku Y, Bae KH, Chung CP : The antibacterial activities of magnolol and honokiol against periodontopathic microorganism. Plan- ta Med 1998, 64:367-369
  14. Kohda H, Kozai K, Nagasaka N, Miyake Y, Suginaka H, Hidaka K, Yamasaka K Prevention of dental caries by Oriental folk medicines--active principles of Zizyphi Fructus for inhibition of insoluble glucan formation by cariogenic bacterium Streptococcus mutans, Plant, Med, 1986, 2, 119-120
  15. 양창호, 이용무, 조기영, 배기환, 정종평 : 대조 추출물이 치은섬유아세포의 생물학적 활성화에 미치는 영향. 대한치주과학회지 1994, 24:144-154
  16. 양창호, 류인철, 최상목, 정종평 : 치은섬유아 세포와 치주인대세포의 형태와 화학주성에 미치는 대조추출물의 효과에 관한 연구. 대한치주학회지 1995, 25:279-289
  17. Silness J, Løe H: Periodontal disease in pregnancy. II. Correlation between oral hygiene and periodontal condition. Acta Odontol Scand 1964, 22: 121-135
  18. Løe H, Silness J: Periodontal disease in pregnancy. I. Prevalence and severity. Acta Odontol Scand 1963, 21: 533-551
  19. Kopczyk RA, Abramas H, Brown AT, Mateny JL, Kaplan AL, Clinical and microbiological effects of a sanguinaria-containing mouthrinse and dentifrice with and without fluoride during 6 months of use. J. Periodontol, 1991, 62, 617-622

## 후박 및 대조 추출혼합물이 치주질환유발 성견의 치주질환억제에 미치는 효과

신승윤<sup>1</sup>, 이용무<sup>1</sup>, 구 영<sup>1</sup>, 류인철<sup>1</sup>, 한수부<sup>1</sup>, 최상묵<sup>1</sup>, 정종평<sup>1</sup>, 배기환<sup>2</sup>

<sup>1</sup>서울대학교 치과대학 치주과학교실

<sup>2</sup>충남대학교 약학대학

최근 생약 추출물의 항균, 항염효과에 관한 관심이 증대되고 있으며 이를 이용한 치주질환의 예방 및 억제효과에 관한 연구들이 진행되고 있다. 이 연구의 목적은 시험관 실험을 통하여 이미 밝혀진 후박 및 대조추출물의 치주질환 원인 균에 대한 항균, 항염효과를 성견에서 인위적으로 치주질환을 일으킨 후 실험 약제의 경구투여를 통하여 질환의 진행에 미치는 영향을 알아보는 것이다. 실험동물은 생후 18개월된 비글견 6마리를 이용하였다. 상악은 제2,3소구치 및 제4소구치에 하악은 제2, 3, 4 소구치 및 제1 대구치를 실험대상 치아로 하였으며 교정용 철사와 봉합사를 이용하여 치경부 주위에 결찰하여 인위적 치주질환을 일으켰다.

염증 유발 8주 후에 결찰을 풀고 실험동물을 아무 것도 투여하지 않은 군(음성대조군, 3마리), 후박 및 대조 추출혼합물 투여군(실험군, 3마리)으로 나누었다. 실험 시작 (-8주), 약제투여 시작(0주), 투여 후 2, 4, 6, 8주째에 치태지수, 치은지수, Florida Probe를 이용한 치주낭깊이 및 치은열구액 등의 임상지수를 측정하였다.

염증유발 8주동안에 치태지수, 치은지수, 치주낭깊이, 치은열구액은 급속히 증가하였다. 결찰을 제거하고, 약제를 투여한 이후 실험군에서 치은지수, 치주낭깊이, 치은열구액은 가장 높은 값을 나타내고 있었다. 실험군에서는 8주가 될 때까지 임상지수 수치가 낮아지고 있었으며, 8주째에는 대부분의 지수에서 음성대조군과 유의성 있는 차이를 보이고 있었다. 양성대조군에 비해서 실험군은 대부분의 경우에 임상지수가 나아지고 있었지만 6주 또는 8주째의 치은지수, 치주낭깊이 중 일부만을 제외하고는 유의성 있는 차이를 보이지는 않았다.

이 연구결과 후박 및 대조 추출혼합물이 in vitro뿐만 아니라 in vivo 상태에서도 치주염의 치료 및 골재생의 효과가 있음을 알 수 있었으며, 이와 같은 동물실험의 결과를 바탕으로 임상시험을 거쳐 향후 사람에게 유용한 치주염치료제로 개발, 사용될 수 있을 것으로 여겨진다.

---

주요어 : 후박추출물, 대조추출물, 항염효과, 비글견