

Blue Rubber Bleb Nevus Syndrome 1

† , ‡ , § * ,
* * † ‡ §

A Case of Blue Rubber Bleb Nevus Syndrome

Ki Soo Kang, M.D., Hyun Ju Oh, M.D., Jae Sung Ko, M.D.*, Jeong Kee Seo, M.D.*,
Kwi Won Park, M.D.†, Gyeong Hoon Kang, M.D.‡ and Woo Sun Kim, M.D.§

Department of Pediatrics, Cheju National University College of Medicine, Jeju,
Departments of *Pediatrics, † Surgery, ‡ Pathology, §Radiology, Seoul National University
College of Medicine, Seoul, Korea

We report a 10-year-old girl with the blue rubber bleb nevus syndrome (BRBNS) who had chronic severe anemia caused by chronic occult bleeding in the gastrointestinal (GI) tract. The patient was admitted to the hospital frequently for recurrent pallor and fatigue since the age of 7 years. Gastroduodenoscopy and capsule endoscopy revealed multiple venous malformations with blood oozing in the stomach, small bowel and colon. The patient was treated by aggressive surgical resection of the 23 vascular malformations in the GI tract. The patient is well without anemia 15 months post surgery. (Korean J Pediatr Gastroenterol Nutr 2008; 11: 198-203)

Key Words: Blue rubber bleb nevus syndrome, Gastrointestinal bleeding, Vascular malformation

Blue rubber bleb nevus syndrome (BRBNS)

23

1)

45)

36

2008 7 2 , 2008 9 9
, 110-769,

28

BRBNS

1995 Moon 7)

Tel.: 02-2072-3627 Fax: 02-743-3455
E.mail: jkseoo@snu.ac.kr

29

2000⁸,
 11 -MRI 4,300/mm³, 6.0 g/dL, 20.5%,
 487,000/mm³, 12.0 μg/Dl (50-180 μg/Dl), TIBC 404 ug/dL, Ferritin 2.5 ng/mL (7-150 ng/mL)
 BRBNS
 4 (Fig 1).
 10 blue
 rubber bleb nevus syndrome (Fig 2).



: , 10
 :
 : 3 MRI (Fig 3).

7 . 3 (Fig 4).
 (7) :
 (3.6-6.8 g/dL), 4 8.5 g/dL

:
 4 11.6 g/dL 12 8.7
 7 6.2 g/dL
 : 37.0 kg (50-75), 137 cm (25-50), 100/60 mmHg, 105 / , 22 / , 36.7C 18 , 2) 23 (3 , (Fig 5).

(3x5 cm) (intra-operative enteroscopy)

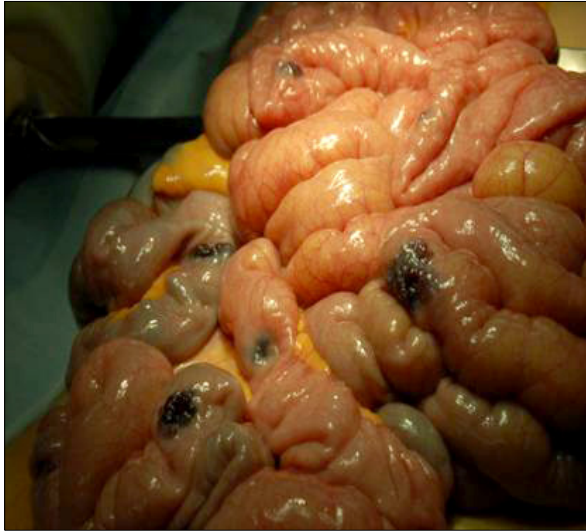

Fig. 5. Multiple transmural venous malformations were found in the small bowel during exploratory laparotomy.

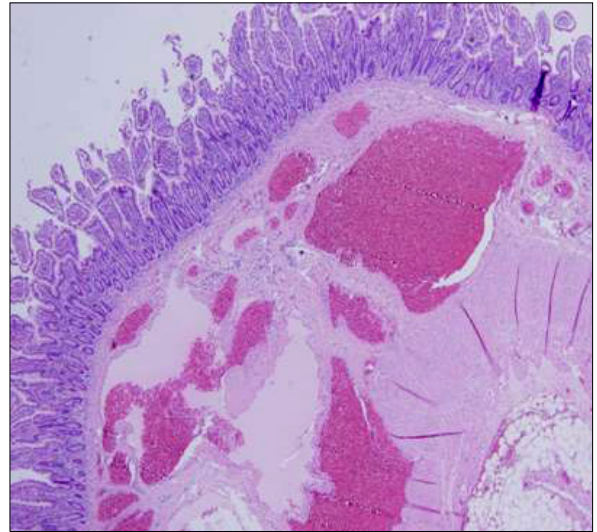


Fig. 6. The histology of resected lesions in the stomach, small bowel, and colon showed multiple dilated and congested vascular structures (H&E stain, × 400).

1) Blue rubber bleb nevus syndrome (BRBNS) 1958
William Bean 1)

4.5.13.14)

2
18

corticosteroid, interferon- 14
18, 19

octreotide 3, 16, 17)

3)

10, 8.11)

12)

12 push enteroscopy 45)

Fishman 3) 10

2)

Kopacova 14

BRBNS

10

blue rubber bleb
nevus syndrome

- 1) Bean WB. Blue rubber-bleb nevi of the skin and gastrointestinal tract. In: Bean WB editor. *Vascular spiders and related lesions of the skin*. Springfield, IL: Charles C Thomas, 1958:17-185.
- 2) Wong CH, Tan YM, Chow WC, Tan PH, Wong WK. Blue rubber bleb nevus syndrome: a clinical spectrum with correlation between cutaneous and gastrointestinal manifestations. *J Gastroenterol Hepatol* 2003;18:1000-2.
- 3) Fishman SJ, Smithers J, Folkman J, Lund DP, Burrows PE, Mulliken JB, et al. Blue rubber bleb nevus syndrome: surgical eradication of gastrointestinal bleeding. *Ann Surg* 2005;241:523-8.
- 4) Guillhon de Araujo Sant'Anna AM, Dubois J, Miron MC, Seidman EG. Wireless capsule endoscopy for obscure small-bowel disorders: final results of the first pediatric controlled trial. *Clin Gastroenterol Hepatol* 2005;3:264-

- 70.
- 5) El-Matary W. Wireless capsule endoscopy: indications, limitations, and future challenges. *J Pediatr Gastroenterol Nutr* 2008;46:4-12.
- 6) Badran A, Vahedi K, Berrebi D, Catana D, De Lagusie P, Drouet L, et al. Pediatric ampullar and small bowel blue rubber bleb nevus syndrome diagnosed by wireless capsule endoscopy. *J Pediatr Gastroenterol Nutr* 2007;44:283-6.
- 7) Moon YM, Kang JK, Park IS, Song SY, Park SW. A case of blue rubber bleb nevus syndrome. *Korean J Gastrointest Endosc* 1995;15:295-302.
- 8) Kim SJ. Blue rubber bleb nevus syndrome with central nervous system involvement. *Pediatr Neurol* 2000;22:410-2.
- 9) Mulliken JB, Glowacki J. Hemangiomas and vascular malformations of infants and children: a classification based on endothelial characteristics. *Plast Reconstr Surg* 1982;69:412-20.
- 10) Beluffi G, Romano P, Matteotti C, Minniti S, Ceffa F, Morbini P. Jejunal intussusception in a 10-year-old boy with blue rubber bleb nevus syndrome. *Pediatr Radiol* 2004;34:742-5.
- 11) den Heijer T, Boon AJ. Blue rubber bleb nevus syndrome. *Neurology* 2007;68:1075.
- 12) Gilbey LK, Girod CE. Blue rubber bleb nevus syndrome: endobronchial involvement presenting as chronic cough. *Chest* 2003;124:760-3.
- 13) De Bona M, Bellumat A, De Boni M. Capsule endoscopy for the diagnosis and follow-up of blue rubber bleb nevus syndrome. *Dig Liver Dis* 2005;37:451-3.
- 14) Kopacova M, Tacheci I, Koudelka J, Kralova M, Rejcht S, Bures J, et al. A new approach to blue rubber bleb nevus syndrome: the role of capsule endoscopy and intra-operative enteroscopy. *Pediatr Surg Int* 2007;23:693-7.
- 15) Gonzalez D, Elizondo BJ, Haslag S, Buchanan G, Burdick JS, Guzzetta PC, et al. Chronic subcutaneous octreotide decreases gastrointestinal blood loss in blue rubber-bleb nevus syndrome. *J Pediatr Gastroenterol Nutr* 2001;33:183-8.
- 16) Shimada S, Namikawa K, Maeda K, Obata S, Ikei S, Mizutani J, et al. Endoscopic polypectomy under laparotomy throughout the elementary tract for a patient with blue rubber bleb nevus syndrome. *Gastrointest Endosc* 1997;45:423-7.
- 17) Ertem D, Acar Y, Kotiloglu E, Yucelten D, Pehlivanoglu E. Blue rubber bleb nevus syndrome. *Pediatrics* 2001;107:418-21.

18) Dwivedi M, Misra SP. Blue rubber bleb nevus syndrome causing upper GI hemorrhage: a novel management approach and review. *Gastrointest Endosc* 2002;55:943-6

19) Ng WT, Kong KC. Argon plasma coagulation for blue rubber bleb nevus syndrome in a female infant. *Eur J Pediatr Surg* 2003;13:137-9.
