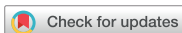

Case Report
Pediatrics



Two Cases of Chloromethylisothiazolinone and Methylisothiazolinone-associated Toxic Lung Injury

Eun Lee ,¹ Seung Kook Son ,² Jisun Yoon ,³ Hyun-Ju Cho ,³ Song-I Yang ,⁴ Sungsu Jung ,³ Kyung-Hyun Do ,⁵ Young Ah Cho ,⁵ So-Yeon Lee ,³ Dong-Uk Park ,⁶ and Soo-Jong Hong

OPEN ACCESS

Received: Aug 6, 2017
Accepted: Oct 10, 2017

Address for Correspondence:

Soo-Jong Hong, MD, PhD

Department of Pediatrics, Childhood Asthma Atopy Center, Environmental Health Center, University of Ulsan College of Medicine, Asan Medical Center, 88 Olympic-ro 43-gil, Songpa-gu, Seoul 05505, Korea.
E-mail: sjhong@amc.seoul.kr

© 2018 The Korean Academy of Medical Sciences.

This is an Open Access article distributed under the terms of the Creative Commons Attribution Non-Commercial License (<https://creativecommons.org/licenses/by-nc/4.0/>) which permits unrestricted non-commercial use, distribution, and reproduction in any medium, provided the original work is properly cited.

ORCID iDs

Eun Lee
<https://orcid.org/0000-0002-7462-0144>
Seung Kook Son
<https://orcid.org/0000-0002-4902-5351>
Jisun Yoon
<https://orcid.org/0000-0002-4904-9118>
Hyun-Ju Cho
<https://orcid.org/0000-0003-4282-4000>
Song-I Yang
<https://orcid.org/0000-0002-9648-4585>
Sungsu Jung
<https://orcid.org/0000-0002-0559-4982>
Kyung-Hyun Do
<https://orcid.org/0000-0003-1922-4680>
Young Ah Cho
<https://orcid.org/0000-0002-3474-8653>
So-Yeon Lee
<https://orcid.org/0000-0002-2499-0702>

¹Department of Pediatrics, Chonnam National University Hospital, Gwangju, Korea

²Department of Pediatrics, Pusan National University Children's Hospital, Yangsan, Korea

³Department of Pediatrics, Childhood Asthma and Atopy Center, Environmental Health Center, University of Ulsan College of Medicine, Asan Medical Center, Seoul, Korea

⁴Department of Pediatrics, Hallym University Sacred Heart Hospital, Hallym University College of Medicine, Anyang, Korea

⁵Department of Radiology, University of Ulsan College of Medicine, Asan Medical Center, Seoul, Korea

⁶Department of Environmental Health, Korea National Open University, Seoul, Korea

ABSTRACT

Previous animal studies have not conclusively determined the association between exposure to humidifier disinfectants (HDs) containing 5-chloro-2-methyl-4-isothiazolin-3-one (CMIT) and/or 2-methyl-4-isothiazolin-3-one (MIT) and development of HD-associated lung injuries. Nonetheless, patients exposed to HDs containing only CMIT and/or MIT showed clinically similar lung injuries to those exposed to HDs containing polyhexamethylene guanidine (PHMG) or oligo (2-[2-ethoxy]ethoxyethyl) guanidinium chloride (PGH). Here, we report twin sisters with lung injuries associated with exposure to CMIT/MIT-containing HDs. At 6 months of age, a younger twin sister presented with the 3-day history of cough, sputum, and respiratory difficulty. Chest radiography revealed multiple patchy consolidation and ground-glass opacities with pneumothorax and pneumomediastinum. Thoracostomy was performed due to pneumothorax at admission and she was discharged at 11 days of hospitalization. At 5 years of age, multiple tiny nodules and faint centrilobular ground-glass opacities were observed with the small pneumatocele. The elder sister visited a tertiary hospital due to dyspnea at 12 months of age. Chest radiography showed consolidation, pneumomediastinum, and pulmonary interstitial emphysema. There was no response to the administration of immunosuppressant drugs and antifibrotic agents. At 5 years of age, chest CT revealed ground-glass opacity and multiple tiny centrilobular ground-glass opacities nodules in both lungs with exercise intolerance.

Keywords: Humidifier Disinfectant; CMIT; MIT; Lung Injury

INTRODUCTION

In 2006, an undifferentiated type of fatal children's interstitial lung disease was observed in Korea.¹⁻³ Subsequent nationwide epidemiologic and animal studies linked toxic chemicals in humidifier disinfectants (HDs) to the development of serious lung injury (LI).⁴⁻⁹

Dong-Uk Park 
<https://orcid.org/0000-0003-3847-7392>
 Soo-Jong Hong 
<https://orcid.org/0000-0003-1409-2113>

Funding

This study was funded by the Korea Ministry of Environment (MOE) as the Environmental Health Action Program (2016001360006).

Disclosure

The authors have no potential conflicts of interest to disclose.

Author Contributions

Conceptualization: Lee E, Do KH, Cho YA, Lee SY, Park DU, Hong SJ. Data curation: Lee E, Son SK, Do KH, Cho YA, Hong SJ. Validation: Lee E, Son SK, Do KH, Cho YA, Hong SJ. Writing - original draft: Lee E, Do KH, Cho YA, Park DU, Hong SJ. Writing - review & editing: Lee E, Do KH, Cho YA, Park DU, Hong SJ.

HDs contain polyhexamethylene guanidine (PHMG), oligo (2-[2-ethoxy]ethoxyethyl) guanidinium chloride (PGH), 5-chloro-2-methyl-4-isothiazolin-3-one (CMIT), or 2-methyl-4-isothiazolin-3-one (MIT).¹⁰ In previous experimental studies,^{4,11} it was reported that PHMG and PGH could cause lung injuries, which are defined as HD-associated lung injuries (HDLIs).¹² However, animal studies have not established definitive links between exposure to HDs containing CMIT and/or MIT and the development of HDLI, even though patients exposed to HDs containing only CMIT and/or MIT showed clinically similar LIs to those seen after exposure of individuals to HDs containing PHMG and/or PGH. Due to the lack of evidence on the inhalational toxicity of CMIT and/or MIT in animal and human studies, victims with CMIT/MIT exposure-associated LIs were not legally protected.

Victims with HDLIs were most commonly exposed to HDs containing PHMG (76.5%), followed by HDs containing PGH (8.8%) and those containing a mixture of other components with CMIT/MIT (7.2%).^{13,14} However, only two of the HDLI victims were exposed to HDs containing only CMIT/MIT.

Generally, HDLIs are characterized by rapid progression of respiratory difficulty without causative factors and the presence of ground-glass opacities, spontaneous air leak syndrome, and consolidation with later diffuse centrilobular nodular opacity on chest computed tomography (CT).^{8,15,16} On lung biopsy, bronchiolar destruction and centrilobular distribution of alveolar destruction with subpleural sparing were predominant in these patients.^{8,17} Here, we report two cases of HDLIs after exposure to HDs containing only CMIT/MIT that developed in twin sisters. The twin sisters were exposed to only one kind of HD product featuring only CMIT/MIT mixtures.

CASE DESCRIPTION

Case 1

The patient is the younger twin sister of case 2. She was previously healthy. She had been exposed to HDs containing CMIT/MIT alone from 4 months of age to 6 months of age. Exposure assessment was performed by experienced experts using a questionnaire and supporting evidence of the purchase of HD.^{5,6,14} Investigation methods for usage of HD are described elsewhere in detail.¹³

At 6 months of age, she presented with a 3-day history of cough, sputum, and respiratory difficulty on April 11th, 2012. She showed an acutely ill-looking appearance. On physical examination, she was afebrile and tachypneic and lung sounds were decreased with chest retraction. Chest radiography and chest CT revealed multiple patchy consolidation and ground-glass opacities in both lungs with pneumothorax and pneumomediastinum (**Fig. 1A and B**). Arterial blood gas analysis (ABGA) showed no hypoxemia or hypercapnia. Her total white blood cell count was 11,040/ μ L with 64.1% neutrophil and 29.1% lymphocytes. Multiplex reverse transcription polymerase chain reaction (RT-PCR) of nasopharyngeal aspirates revealed the presence of influenza B infection. A lung biopsy was not done. Thoracostomy was performed due to pneumothorax at admission and she was discharged at 11 days of hospitalization.

At 8 months of age, she was hospitalized with acute bronchiolitis. During the hospitalization, she presented with chest retraction, tachypnea, and desaturation. However, there was no air

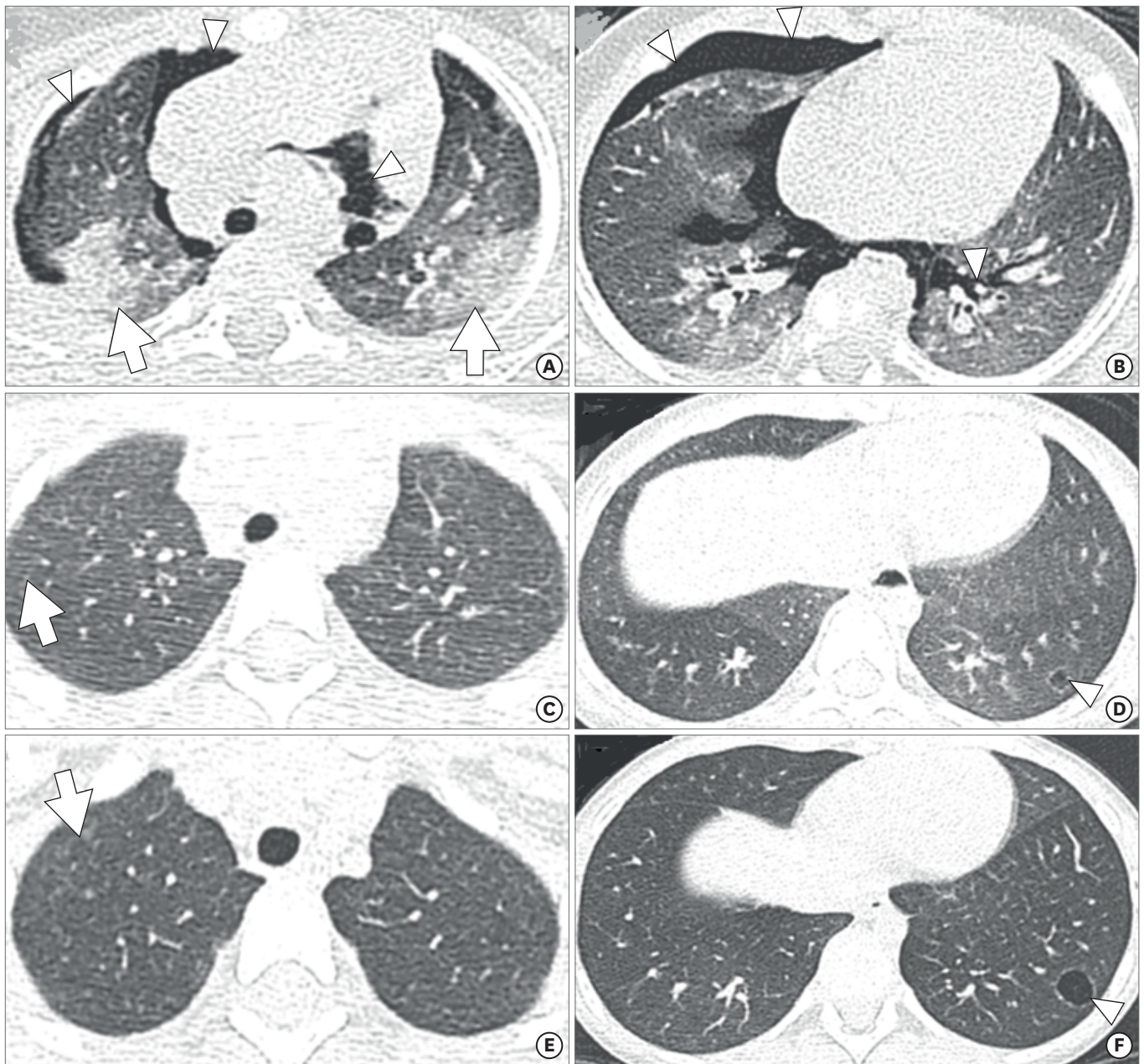


Fig. 1. Chest radiography and computed tomography (CT) of case 1. **(A, B)** At 6 months of age, initial chest CT (1-mm-thick axial images) showed extensive air leakage (arrowheads) indicating pneumothorax, pneumomediastinum, and pulmonary interstitial emphysema. Patchy consolidations (arrows) and ill-defined ground-glass opacities are also noted. **(C, D)** After 3 years, larger, subtle ground-glass opacities with air trapping, suspicious ill-defined centrilobular nodules (arrow), and a small air cyst (arrowhead) remained. **(E, F)** At 5 years of age, multiple tiny and faint centrilobular nodules (arrow) in both lungs and a small air cyst (arrowhead), possibly a pneumatocele, remained in the basal segment of the left lower lobe.

leak syndrome on chest radiography. Follow-up chest CT scan, performed at 3 years of age, showed tiny ground-glass opacities in both lungs (**Fig. 1C and D**). At 5 years of age, multiple tiny nodules and faint centrilobular ground-glass opacities in both lungs were observed with the presence of small pneumatocele on chest CT (**Fig. 1E and F**). She is healthy but reports intermittent wheezing after exercise.

Case 2

This patient is a previous healthy 12-month-old girl who visited a tertiary hospital due to dyspnea on November 3rd, 2012. She had cough, rhinorrhea, and mild fever for 7 days before the hospital visit. She had been exposed to HD containing only CMIT/MIT in the same concentration during the same period with her sister (case 1). According to her aunts' statement, she was kept away from HDs after her elder sister's hospitalization at 6 months of age. The cumulative exposure dose was 19.56 g/m³.¹³ Her respiratory difficulty had aggravated 2 days before hospitalization. At admission, saturation was 93% and recovered with application of 0.5 L/min oxygen via a nasal prong. She showed an acute ill appearance at admission. On physical examination, a coarse breathing sound was auscultated without definite rales or wheezes. In her family history, her younger twin sister experienced sudden onset of dyspnea, cough, and mild sputum at 6 months old. When her sister visited a tertiary hospital, extensive pneumothorax and pneumomediastinum without identified causes of the air leak syndrome was observed. During her younger sister's hospitalization, an aunt raised this girl.

ABGA showed mild hypoxemia with no hypercapnia. Her white blood cell count was 4,630/ μ L with 44.5% neutrophil and 43.0% lymphocytes. Respiratory RT-PCR using sputum samples revealed the presence of respiratory syncytial virus at admission. Her chest radiography and CT revealed consolidation in both lung fields and pneumomediastinum, air trapping, and pulmonary interstitial emphysema in the right lung field (Fig. 2A and B).

On the 6th day of hospitalization, pneumomediastinum was observed in the left lung on chest radiography. The patient required mechanical ventilation for a total of 50 days. Even with the administration of five cycles of high-dose methylprednisolone (20 mg/kg, 3 consecutive days) and high-dose immunoglobulin during ventilator care, extubation failed with three attempts. On the 55th day of hospitalization, after the third failed extubation, a tracheostomy was performed. On follow-up chest CT on the 60th day of hospitalization, a patchy consolidation along the bronchovascular bundles was observed with air bronchogram and multiple lung cysts (Fig. 2C and D). At 5 years of age, chest CT revealed ground-glass opacity and multiple tiny centrilobular ground-glass opacities nodules in both lungs (Fig. 2E and F).

The patient reports dyspnea and tachypnea during exercise. Decannulation was attempted when she was 5 years of age. A pulmonary function test was not performed due to the tracheostomy. Her height and weight are at the 25th percentile for her age.

DISCUSSION

We report two cases of HDLI after exposure to HDs containing CMIT/MIT alone in twin sisters. Although the evidence for the development of HDLI after exposure to HD containing CMIT/MIT alone in animal studies is lacking, these case reports support the belief that CMIT/MIT can cause HDLIs in those exposed to HDs containing these chemicals, similar to HDLIs caused by exposure to PHMG or PGH.⁸

Cases of HDLI are typically characterized by rapid progression of respiratory difficulty, starting from mild cough or tachypnea, without any definitely identified causes,^{3,8} which is consistent with the features of the present two cases. On chest CT, chronological changes include consolidation to centrilobular opacities with subsequent faint centrilobular nodules.^{8,15} Spontaneous air leak syndromes, observed in 26%–44% of HDLI patients

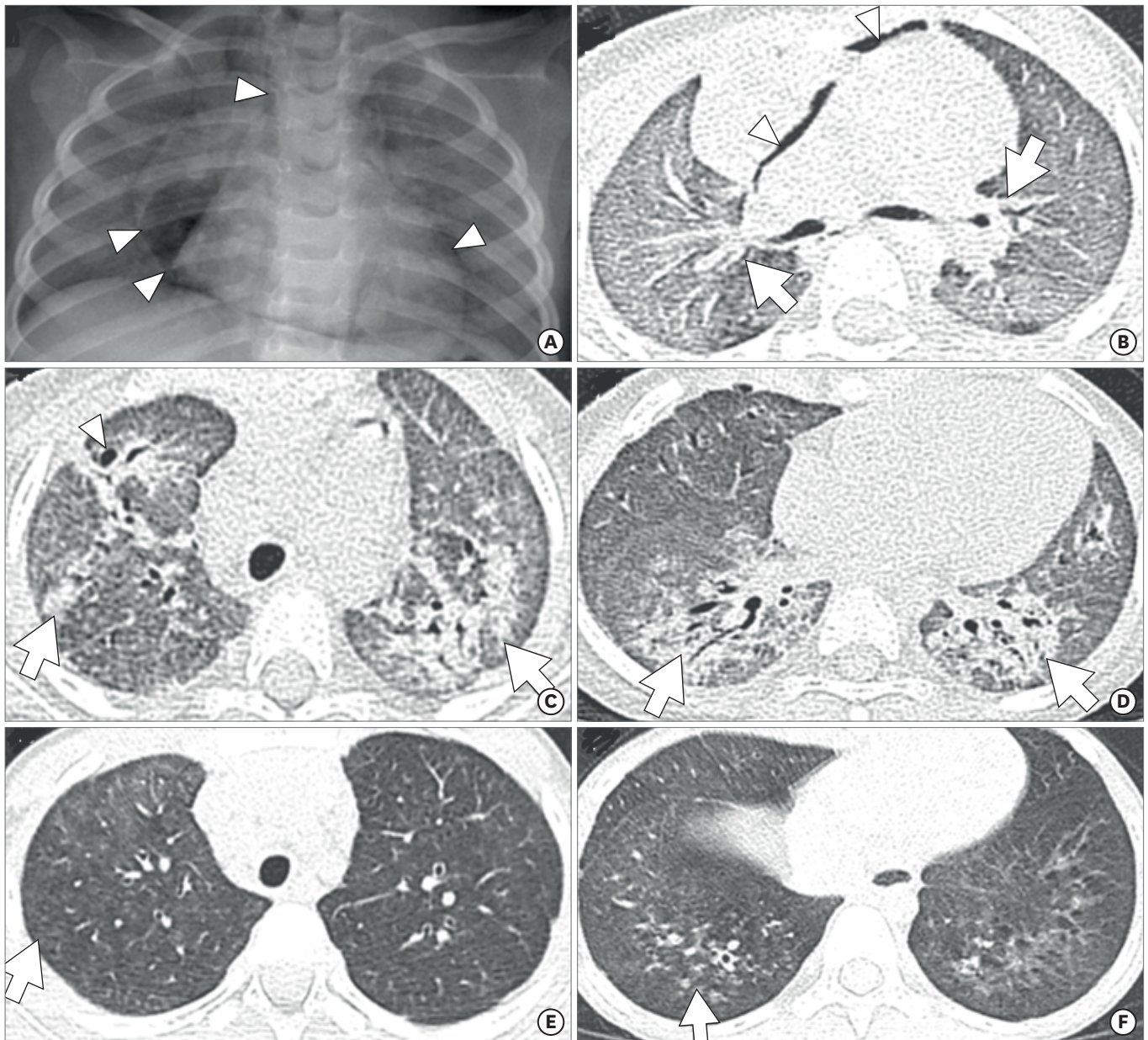


Fig. 2. Chest radiography and computed tomography (CT) of case 2. At 12 months of age, (A) initial chest radiography and (B) a 1-mm-thick axial CT image revealed diffuse ground-glass opacities and suspicious pulmonary interstitial emphysema (arrows) in both lungs and pneumomediastinum (arrowheads). (C, D) After 2 months, diffuse ground-glass opacities and patchy consolidations (arrows) along the bronchovascular bundles were noted, and several air cysts are visible (arrowhead). (E, F) After 5 years, subtle ground-glass opacities and multiple tiny ill-defined centrilobular nodules (arrows) were still evident in both lungs.

according to the disease course,^{15,17} were seen in both of the patients in the present report. However, the interval between HDLI development in the two sisters might be associated with reduced attention paid to case 2 due to the hospitalization of case 1 and subsequent aggravation of respiratory symptoms combined with respiratory syncytial virus infection in case 2. Respiratory viral infection was itself not the direct cause of the LIs in the present study considering the unusually rapidly progressing respiratory failure and only partial detection of respiratory viral infection in a cluster of other HDLIs.^{3,17} A time-lag between exposure to HDs and onset of HDLIs in case 2 might be associated with lack of additional information on exposure to HDs due to remote memory on the periods of HD usage or a viral infection as

a triggering factor of the expression of HDLIs with underlying unidentified or indistinctive symptoms. The possibility of HD usage after 6 months of age could not be completely ruled out in case 2.

The isothiazolinones in CMIT/MIT have biocidal properties and are therefore usually found in perfume, air conditioning systems, and HDs.¹⁸ In previous studies,^{19,20} CMIT/MIT in paint and cosmetics were found to cause airborne allergic contact dermatitis. However, there are no studies of the respiratory health effects of CMIT/MIT inhalation in either animals or humans. A 53-year-old chemical operator was reported to develop asthma 5 months after beginning work in an isothiazolinone manufacturing plant.²¹ Unpublished experimental data showed that exposure to HDs containing a mixture of CMIT and MIT was not associated with LIs,²² despite the presence of cases of HD containing CMIT/MIT-associated LI, as in the present cases.

Aside from the previous studies on the effect of cutaneous exposure to CMIT/MIT, one previous study found harmful effects of CMIT/MIT inhalation in the respiratory system in humans,²³ demonstrating that exposure to HDs containing CMIT/MIT causes peripheral airway dysfunction without bronchial hyperreactivity, especially in children who inhale high levels of CMIT/MIT. The results of that study suggested the possible mechanisms of the peripheral airway dysfunction, namely, bronchiolar destruction with alveolar damage, in response to inhalational exposure to CMIT/MIT.²³ One other published experimental study on CMIT toxicity using rat alveolar macrophages and NR8383 cell lines reported that treatment with CMIT markedly inhibited phagocytic oxidative bursts and cellular cytokine secretion, causing toxic respiratory effects.²⁴ The production of oxidative stress and changes in the expression of oxidative stress-related genes after exposure to toxic chemicals in HD, such as PHMG/PGH and CMIT/MIT, might be a common pathway in the development of HDLIs.^{12,25,26}

The estimated exposure intensity to HDs in cases of CMIT/MIT-associated LIs in the present study (mean, 82 $\mu\text{g}/\text{m}^3$) were far lower than that of PHMG or PGH exposure associated LI cases (mean, 900 $\mu\text{g}/\text{m}^3$).¹³ This may explain the lower prevalence of HDLIs in victims exposed to HDs containing CMIT/MIT alone, as well as the differences in toxicity levels by types of HD. In addition, the health effects of CMIT/MIT might differ according to species, susceptibility, receptor, exposure dose, and duration.²⁷ More sophisticated and elaborate experimental studies are currently underway, because further studies of the respiratory health effects of CMIT/MIT inhalation are needed to limit their harmful effects.

In summary, we report two cases of LIs linked to HDs containing CMIT/MIT alone, although experimental evidence and mechanisms explaining the harmful respiratory effects of CMIT/MIT are still lacking. This issue requires attention to prevent the occurrence of additional harmful respiratory diseases caused by CMIT/MIT inhalation.

REFERENCES

1. Cheon CK, Jin HS, Kang EK, Kim HB, Kim BJ, Yu J, et al. Epidemic acute interstitial pneumonia in children occurred during the early 2000s. *Korean J Pediatr* 2008;51(4):383-90.
[CROSSREF](#)
2. Kim BJ, Kim HA, Song YH, Yu J, Kim S, Park SJ, et al. Nationwide surveillance of acute interstitial pneumonia in Korea. *Korean J Pediatr* 2009;52(3):324-9.
[CROSSREF](#)

3. Kim KW, Ahn K, Yang HJ, Lee S, Park JD, Kim WK, et al. Humidifier disinfectant-associated children's interstitial lung disease. *Am J Respir Crit Care Med* 2014;189(1):48-56.
[PUBMED](#) | [CROSSREF](#)
4. Kim JY, Kim HH, Cho KH. Acute cardiovascular toxicity of sterilizers, PHMG, and PGH: severe inflammation in human cells and heart failure in zebrafish. *Cardiovasc Toxicol* 2013;13(2):148-60.
[PUBMED](#) | [CROSSREF](#)
5. Paek D, Koh Y, Park DU, Cheong HK, Do KH, Lim CM, et al. Nationwide study of humidifier disinfectant lung injury in South Korea, 1994–2011. Incidence and dose-response relationships. *Ann Am Thorac Soc* 2015;12(12):1813-21.
[PUBMED](#) | [CROSSREF](#)
6. Park DU, Choi YY, Ahn JJ, Lim HK, Kim SK, Roh HS, et al. Relationship between exposure to household humidifier disinfectants and risk of lung injury: a family-based study. *PLoS One* 2015;10(5):e0124610.
[PUBMED](#) | [CROSSREF](#)
7. Yang HJ, Kim HJ, Yu J, Lee E, Jung YH, Kim HY, et al. Inhalation toxicity of humidifier disinfectants as a risk factor of children's interstitial lung disease in Korea: a case-control study. *PLoS One* 2013;8(6):e64430.
[PUBMED](#) | [CROSSREF](#)
8. Lee E, Seo JH, Kim HY, Yu J, Jhang WK, Park SJ, et al. Toxic inhalational injury-associated interstitial lung disease in children. *J Korean Med Sci* 2013;28(6):915-23.
[PUBMED](#) | [CROSSREF](#)
9. Kim HJ, Lee MS, Hong SB, Huh JW, Do KH, Jang SJ, et al. A cluster of lung injury cases associated with home humidifier use: an epidemiological investigation. *Thorax* 2014;69(8):703-8.
[PUBMED](#) | [CROSSREF](#)
10. Lee JH, Kim YH, Kwon JH. Fatal misuse of humidifier disinfectants in Korea: importance of screening risk assessment and implications for management of chemicals in consumer products. *Environ Sci Technol* 2012;46(5):2498-500.
[PUBMED](#) | [CROSSREF](#)
11. Park S, Lee K, Lee EJ, Lee SY, In KH, Kim HK, et al. Humidifier disinfectant-associated interstitial lung disease in an animal model induced by polyhexamethylene guanidine aerosol. *Am J Respir Crit Care Med* 2014;190(6):706-8.
[PUBMED](#) | [CROSSREF](#)
12. Kim HR, Hwang GW, Naganuma A, Chung KH. Adverse health effects of humidifier disinfectants in Korea: lung toxicity of polyhexamethylene guanidine phosphate. *J Toxicol Sci* 2016;41(6):711-7.
[PUBMED](#) | [CROSSREF](#)
13. Park DU, Friesen MC, Roh HS, Choi YY, Ahn JJ, Lim HK, et al. Estimating retrospective exposure of household humidifier disinfectants. *Indoor Air* 2015;25(6):631-40.
[PUBMED](#) | [CROSSREF](#)
14. Park DU, Ryu SH, Lim HK, Kim SK, Choi YY, Ahn JJ, et al. Types of household humidifier disinfectant and associated risk of lung injury (HDLI) in South Korea. *Sci Total Environ* 2017;596-597:53-60.
[PUBMED](#) | [CROSSREF](#)
15. Yoon HM, Lee E, Lee JS, Do KH, Jung AY, Yoon CH, et al. Humidifier disinfectant-associated children's interstitial lung disease: computed tomographic features, histopathologic correlation and comparison between survivors and non-survivors. *Eur Radiol* 2016;26(1):235-43.
[PUBMED](#) | [CROSSREF](#)
16. Hong SB, Kim HJ, Huh JW, Do KH, Jang SJ, Song JS, et al. A cluster of lung injury associated with home humidifier use: clinical, radiological and pathological description of a new syndrome. *Thorax* 2014;69(8):694-702.
[PUBMED](#) | [CROSSREF](#)
17. Lee E, Seo JH, Kim HY, Yu J, Song JW, Park YS, et al. Two series of familial cases with unclassified interstitial pneumonia with fibrosis. *Allergy Asthma Immunol Res* 2012;4(4):240-4.
[PUBMED](#) | [CROSSREF](#)
18. Nagorka R, Gleue C, Scheller C, Moriske HJ, Straff W. Isothiazolone emissions from building products. *Indoor Air* 2015;25(1):68-78.
[PUBMED](#) | [CROSSREF](#)
19. Lundov MD, Mosbech H, Thyssen JP, Menné T, Zachariae C. Two cases of airborne allergic contact dermatitis caused by methylisothiazolinone in paint. *Contact Dermatitis* 2011;65(3):176-9.
[PUBMED](#) | [CROSSREF](#)
20. Geier J, Lessmann H, Schnuch A, Uter W. Recent increase in allergic reactions to methylchloroisothiazolinone/methylisothiazolinone: is methylisothiazolinone the culprit? *Contact Dermatitis* 2012;67(6):334-41.
[PUBMED](#) | [CROSSREF](#)

21. Bourke SJ, Convery RP, Stenton SC, Malcolm RM, Hendrick DJ. Occupational asthma in an isothiazolinone manufacturing plant. *Thorax* 1997;52(8):746-8.
[PUBMED](#) | [CROSSREF](#)
22. Study on the health effect of harmful chemical substance in household items. <http://webbook.me.go.kr/DLi-File/NIER/06/021/5591231.pdf>. Updated 2014. Accessed July 20, 2017.
23. Cho HJ, Park DU, Yoon J, Lee E, Yang SI, Kim YH, et al. Effects of a mixture of chloromethylisothiazolinone and methylisothiazolinone on peripheral airway dysfunction in children. *PLoS One* 2017;12(4):e0176083.
[PUBMED](#) | [CROSSREF](#)
24. Poon R, Rigden M, Edmonds N, Charman N, Lamy S. Effects of 5-chloro-2-methyl-4-isothiazolin-3-one and other candidate biodiesel biocides on rat alveolar macrophages and NR8383 cells. *Arch Toxicol* 2011;85(11):1419-27.
[PUBMED](#) | [CROSSREF](#)
25. Jung HN, Zerlin T, Podder B, Song HY, Kim YS. Cytotoxicity and gene expression profiling of polyhexamethylene guanidine hydrochloride in human alveolar A549 cells. *Toxicol In Vitro* 2014;28(4):684-92.
[PUBMED](#) | [CROSSREF](#)
26. Kim MS, Jeong SW, Choi SJ, Han JY, Kim SH, Yoon S, et al. Analysis of genomic responses in a rat lung model treated with a humidifier sterilizer containing polyhexamethyleneguanidine phosphate. *Toxicol Lett* 2017;268:36-43.
[PUBMED](#) | [CROSSREF](#)
27. Brent RL. Utilization of animal studies to determine the effects and human risks of environmental toxicants (drugs, chemicals, and physical agents). *Pediatrics* 2004;113(4 Suppl):984-95.
[PUBMED](#)