

## Does cone-beam CT alter treatment plans? Comparison of preoperative implant planning using panoramic versus cone-beam CT images

Maria Eugenia Guerrero<sup>1,2</sup>, Jorge Noriega<sup>3</sup>, Carmen Castro<sup>3</sup>, Reinhilde Jacobs<sup>1,2,\*</sup>

<sup>1</sup>OIC, OMFS IMPATH Research Group, Department of Imaging and Pathology, Faculty of Medicine, University of Leuven, Leuven, Belgium

<sup>2</sup>Department of Oral and Maxillofacial Surgery, University Hospitals, Leuven, Belgium

<sup>3</sup>Master of Periodontology, Universidad San Martín de Porres, Lima, Peru

### ABSTRACT

**Purpose:** The present study was performed to compare the planning of implant placement based on panoramic radiography (PAN) and cone-beam computed tomography (CBCT) images, and to study the impact of the image dataset on the treatment planning.

**Materials and Methods:** One hundred five partially edentulous patients (77 males, 28 females, mean age: 46 years, range: 26-67 years) seeking oral implant rehabilitation were referred for presurgical imaging. Imaging consisted of PAN and CBCT imaging. Four observers planned implant treatment based on the two-dimensional (2D) image datasets and at least one month later on the three-dimensional (3D) image dataset. Apart from presurgical diagnostic and dimensional measurement tasks, the observers needed to indicate the surgical confidence levels and assess the image quality in relation to the presurgical needs.

**Results:** All observers confirmed that both imaging modalities (PAN and CBCT) gave similar values when planning implant diameter. Also, the results showed no differences between both imaging modalities for the length of implants with an anterior location. However, significant differences were found in the length of implants with a posterior location. For implant dimensions, longer lengths of the implants were planned with PAN, as confirmed by two observers. CBCT provided images with improved scores for subjective image quality and surgical confidence levels.

**Conclusion:** Within the limitations of this study, there was a trend toward PAN-based preoperative planning of implant placement leading towards the use of longer implants within the posterior jaw bone. (*Imaging Sci Dent* 2014; 44: 121-8)

**KEY WORDS:** Cone-Beam Computed Tomography; Dental Implants; Radiography, Panoramic

### Introduction

The outcomes of implant therapy have become highly predictable in recent decades.<sup>1,2</sup> Yet, the relationship of implants to important anatomical structures such as nerves, vessels, dental roots, the nasal floor, and sinus cavities can significantly affect the morbidity of the surgical pro-

cedure and influence the outcome. In partially edentulous patients, it is claimed that in preoperative diagnosis and planning based on two-dimensional (2D) imaging, such implants may be placed in areas with a potential risk of damage to vital structures. Thus, restricting preoperative diagnosis to 2D images in dental implant practice can potentially cause implant failures.<sup>3,4</sup>

Meanwhile, cone-beam computed tomography (CBCT) has developed rapidly and is now being routinely used for preoperative planning by some implant surgeons. It provides a high spatial resolution and accurate three-dimensional (3D) images.<sup>5</sup> Today, evidence-based guidelines are being established dealing with the justification, optimiza-

\*This study was accomplished by a doctoral scholarship in the framework of the Interfaculty Council for Development Co-operation (IRO).

Received January 20, 2014; Revised February 21, 2014; Accepted February 27, 2014

\*Correspondence to : Prof. Reinhilde Jacobs

Department of Imaging and Pathology, Faculty of Medicine, University of Leuven, Kapucijnenvoer 7, Leuven 3000, Belgium

Tel) 32-16-3-32410, Fax) 32-16-3-32410, E-mail) reinhilde.jacobs@uzleuven.be

tion, and referral criteria of CBCT for clinical use.<sup>6,7</sup> If it appears that implants are needed in areas with a potential risk of damage to vital structures, the clinician may choose to add 3D imaging.

There has been a lively debate in the literature on which imaging methods should be included in treatment planning.<sup>8,9</sup> A strong clinical indication and a low radiation dose should be the main guidelines for selecting the appropriate technique (ALARA principle: as low as reasonably achievable).

The overall goal of the present study was to evaluate whether the location and the size of an implant planned on panoramic images differed from that planned on CBCT. Secondly, a subjective observer evaluation of image quality and surgical confidence was investigated in both modalities.

## Materials and Methods

This study was approved by the Institutional Ethics Review Boards of the KU Leuven, Leuven, Belgium, under the number B32220083749 and San Martin de Porres University, Lima, Peru (protocol #012/2009). It was conducted from July 2009 to June 2010. Informed consent was obtained from patients to use their anonymized X-ray images and photographs. Consent for involvement in the study had no further implications on their treatment.

### Image acquisition and patient confidentiality

With the approval of the abovementioned Institutional Review Boards, anonymous CBCT image datasets were prospectively analyzed. Patients were recruited prospectively from referrals to the Master of Periodontology, School of Dentistry, Universidad San Martin de Porres, Lima, Peru, and the Oral Imaging Center KU Leuven, Leuven, Belgium, between January 2009 and June 2010. The criteria for potential inclusion in the study were as follows: 1) partially dentate, 2) referred for one or more implants, 3) PAN and CBCT images available, 4) images with high technical standards (i.e., appropriate sharpness, density, and contrast), and 5) clinical photographs available. The exclusion criteria were edentulous patients or presence of some sort of pathology.

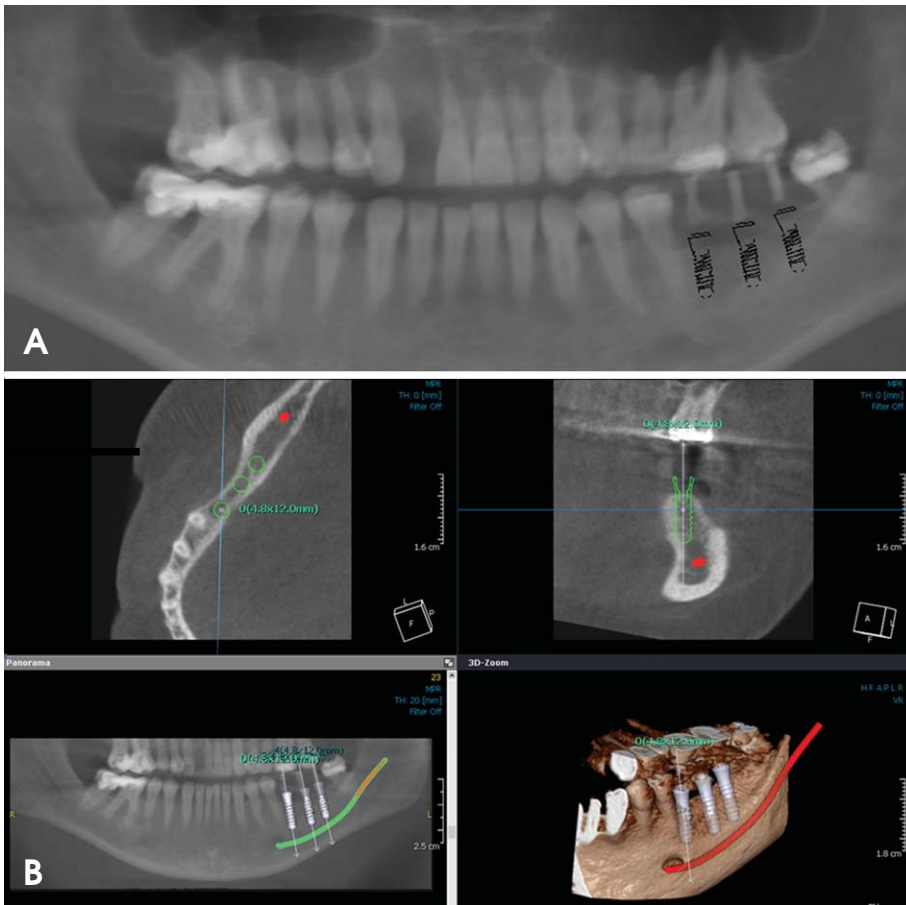
A total of 105 patients were recruited to the study. The distribution of the implant sites and edentulous areas is described in Table 1. All CBCT images were acquired using either SCANORA<sup>®</sup>3D (Soredex, Tuusula, Finland) or i-CAT<sup>®</sup> (Imaging Sciences International, Hatfield, PA,

**Table 1.** Sample distribution of implant sites (n=619)

Variable	n	%
Location of implant sites		
Anterior	74	12.0
Posterior	545	88.0
Number of implants per patient		
1-2	25	23.8
3-4	26	24.8
5-6	22	21.0
7+	32	30.5
Position of implants		
Incisive	47	7.6
Canine	27	4.4
Premolar	265	42.8
Molar	280	45.2
Quadrant		
1	170	27.5
2	168	27.1
3	142	22.9
4	139	22.5

USA). For the first machine, the field of view was 16 cm × 6 cm. The operating parameters were set at 85 kVp and 10 mA, and the scan time was 10 s. For the second machine, the images were obtained at 120 kV and 24 mAs with a typical voxel size of 0.5 mm. A list with the codes and corresponding names was created and saved in an encrypted file so that patient confidentiality was protected and yet the data were retrievable if needed. For PAN radiography, an Orthopantomograph<sup>®</sup> OP100 (Instrumentarium Corp., Tuusula, Finland) or a Cranex<sup>®</sup> Tome multifunctional unit (Soredex, Tuusula, Finland) was used. Both panoramic units were operated at 70 kV and 8 mA. The Orthopantomograph was a direct digital device. The second panoramic unit used photo-stimulated phosphor plates. The plates were processed with an ADC Solo Digitizer<sup>®</sup> (Agfa Corporation, Mortsel, Belgium). In order to obtain meaningful measurements from the PAN images, the magnification factors of both PAN units were measured using an object of known dimensions. Prior to the full implementation of the study, a pilot study was conducted to evaluate the magnification factor; six reference balls having a diameter of 5 mm were fixed by a piece of wax in the maxillary and mandibular anterior, premolar, and molar regions of partial edentulous patients. The Orthopantomograph unit reported a mean calculated magnification factor of  $1.27 \pm 0.02$  (range: 1.23-1.31), and a value of  $1.28 \pm 0.01$  (range 1.23-1.30) was obtained for the Cranex<sup>®</sup> Tome unit.

For visualizing the CBCT images, an Ondemand 3D<sup>®</sup> (Cybermed Co., Seoul, Korea) or i-CATVision<sup>™</sup> (Imaging Sciences International, Hatfield, PA, USA) was used



**Fig. 1.** The implant planning process is performed using panoramic radiography (PAN) (A) and cone-beam computed tomography (CBCT). (B) Images of a 32-year-old woman. After careful evaluation of the 3D data, an appropriate treatment plan is developed, as seen in the cross-sectional images. The bone width is not evident on the PAN image, whereas a possible fenestration can be predicted thanks to the availability of CBCT.

to visualize the cases, as appropriate to the scanner used to acquire the images. The slice thickness was 0.25 mm.

For observing the PAN images, the Digora<sup>®</sup> for Windows 2.7 software (Digora, Soredex, Tuusula, Finland) was used for implant planning. The values were corrected for the “true” magnification factors of the panoramic radiographs (Fig. 1).

#### Observer assessments

Four experienced calibrated implant surgeons evaluated the PAN images, CBCT examinations, clinical data, and photographs under standardized conditions. All images were viewed on a Dell Precision<sup>®</sup> Display (1920 × 1200 pixels) (Dell Inc., Round Rock, TX, USA) monitor in a dimmed room at a distance of 60 cm from the diagnostic viewing screen. Two training sessions were organized prior to the final observations for the calibration of the observers.

Each observer undertook two viewing sessions, separated by a minimum time interval of four weeks. On one occasion, only PAN images were available, while on the other occasion, only CBCT images were available. The

order of patients was randomized per session, as was the order of sessions (PAN only or CBCT only) for each rater.

Each practitioner had to select an implant for each prospective implant site on each patient. The choice of implants was restricted to the implants available in the Straumann Standard<sup>®</sup> implants library (Straumann AG, Basel, Switzerland), giving a choice of 20 sizes with combinations of three widths (3.3, 4.1, and 4.8 mm) and six lengths (6, 8, 10, 12, 14, and 16 mm). In selecting implants, the observers were required to use a safety margin of 1.5 mm below the maxillary sinus or nasal floor and above the mandibular canal.

Each observer provided information by using a pro forma to answer three categories of questions: 1) overall image quality with respect to the visualization and delineation of anatomical structures such as maxillary sinus and mandibular canal and the bone morphology; 2) surgical confidence levels; and 3) implant properties: location, length, and diameter. A four-point rating scale (1=very poor/very doubtful; 2=poor/doubtful, unsure; 3=acceptable/confident; 4=excellent/very confident) was used for the first two categories.

### Statistical methods

All statistical analyses were performed using Stata version 12 for Windows (StataCorp LP, College Station, TX, USA). The normality assumption was not satisfied according to the Shapiro-Wilk test. Differences in the implant length and diameter between CBCT and PAN planning were compared by using the Mann-Whitney U test. To compare the agreement among the four observers on PAN versus CBCT, kappa statistics were selected. A kappa value of <0.40 was considered to be poor; 0.40-0.59, fair; 0.60-0.74, good; and 0.75-1.00, excellent agreement. As a complement, a Bland-Altman plot was used for comparing the inter- and intraobserver agreements. The limits of agreement for this analysis were determined with the 95<sup>th</sup> percentile of the absolute difference in the length and diameter of the implants planned in both modalities due to the non-normal distribution of the differences. The overall image quality and the surgeons' confidence levels relating to the surgery were analyzed using the Mann-Whitney U test for the four observers. Statistical significance was set at  $p < 0.05$  for all the tests.

### Results

The number of patients observed and scored was 105. A total of 619 potential implants were planned by the observers; 12% of the selected implants were planned in the anterior area and 88% in the posterior area (Table 1).

#### Implant properties

Table 2 showed presurgical planning variations with PAN and CBCT. The implant length and width remained unchanged in 92.1% and 88.5% of the cases, respectively. No differences were found between both imaging modalities for the length and the diameter on implants with an anterior location. However, only significant differences were found for the length of implants with a posterior location.

For the length of the implant, two of the four independent observers reported greater lengths with PAN than with CBCT. However, implants planned on the anterior site reported the same lengths when planned with CBCT or PAN ( $p > 0.05$ ). Regarding implant diameter, there were no significant differences between PAN and CBCT ( $p > 0.05$ ). Based on the results, we could assume that the longer lengths of implants were planned with PAN; this was confirmed by two observers. All the observers confirmed that both modalities (PAN and CBCT) gave similar values

**Table 2.** Variation on presurgical planning with panoramic radiography (PAN) and cone-beam computed tomography (CBCT) (n=619)

Variable	n (%)	Anterior	Posterior
Length of implants			
PAN < CBCT	5 (0.8%)	0	5
PAN = CBCT	570 (92.1%)	68	502
PAN > CBCT	44 (7.1%)	6	38
p-value			
Observer 1	0.125	0.576	0.089
Observer 2	0.000*	0.454	0.000*
Observer 3	0.006*	0.855	0.002*
Observer 4	0.761	0.312	0.779
Diameter of implants			
PAN < CBCT	10 (1.6%)	4	6
PAN = CBCT	548 (88.5%)	68	480
PAN > CBCT	61 (9.9%)	2	59
p-value			
Observer 1	0.113	0.469	0.100
Observer 2	0.209	0.698	0.230
Observer 3	0.874	0.543	0.830
Observer 4	0.497	0.321	0.615

\*Statistically significant difference ( $p < 0.05$ )

**Table 3.** Inter-observer confidence and quality (n=619)

	Confidence		Quality	
	Kappa	Kappa*	Kappa	Kappa*
General	0.317	0.954	0.311	0.954
Location of implant sites				
Anterior	0.311	0.955	0.291	0.955
Posterior	0.317	0.953	0.314	0.953
Quadrant				
1	0.304	0.929	0.321	0.929
2	0.322	0.982	0.295	0.982
3	0.300	0.946	0.299	0.946
4	0.338	0.957	0.329	0.957

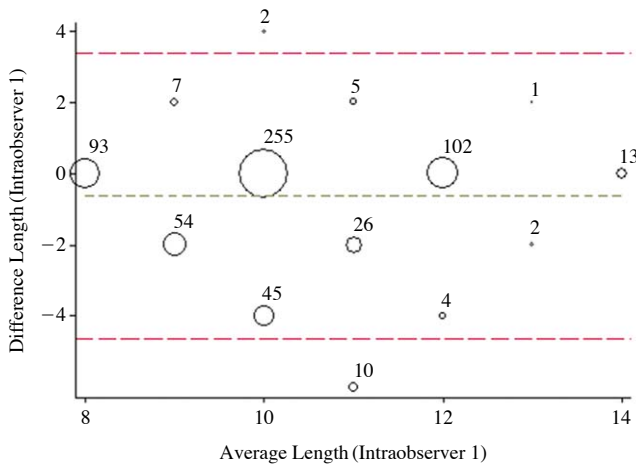
\*outcome 1+2, 3+4

of the implant diameter.

#### Inter- and intra-observer agreements

Image quality and surgical confidence levels were measured on a scale of 1 to 4 by four observers. A poor but significant inter-observer agreement (kappa=0.30-0.34) ( $p < 0.001$ ) was found for the general implant locations and quadrant agreements. However, when dichotomizing the scores into poor/doubtful (1-2) or good/confident (3-4), the inter-observer agreement increased to an excellent kappa value of 0.92 (Table 3).

Intra-observer variability of each observer ranged from fair to good (weighted kappa=0.46-0.74). The limits of agreement for the intra-observer differences ranged from



**Fig. 2.** A graph shows the intra-observer concordance of implant lengths (Bland-Altman).

**Table 4.** Inter-observer pairwise agreement (k) (n=619)

	Observer 2	Observer 3	Observer 4
<b>Confidence</b>			
Observer 1	0.295	0.334	0.321
Observer 2		0.313	0.313
Observer 3			0.327
<b>Quality</b>			
Observer 1	0.308	0.353	0.305
Observer 2		0.317	0.292
Observer 3			0.294
<b>Length</b>			
Observer 1	0.623	0.640	0.616
Observer 2		0.577	0.565
Observer 3			0.851
<b>Diameter</b>			
Observer 1	0.642	0.694	0.712
Observer 2		0.621	0.611
Observer 3			0.885

−4.62 to 3.38 with an average difference of −0.62. The number of disagreements between the two measurements was 12 (1.9%). There was no systematic error because the differences (vertical axis) were distributed consistently along the averages (horizontal axis) (Fig. 2).

Kappa values representing the inter-observer agreement for each observer pair are given in Table 4. Higher agreements were obtained for implant length and diameter with a kappa value between 0.57 and 0.89. For quality and confidence, observers 1 and 3 had higher agreements, but for implant length and diameter, observers 3 and 4 scored higher agreements.

#### Overall image quality and surgical confidence levels

With the Mann-Whitney U test, we tested the differences

**Table 5.** Confidence and quality between panoramic radiography (PAN) and cone-beam computed tomography (CBCT) (n=619)

	Median	IQR	P
Confidence			
PAN	1.50	1.25-1.75	0.000
CBCT	3.50	3.25-3.75	
Quality			
PAN	1.50	1.25-1.75	0.000
CBCT	3.50	3.25-3.75	

in the overall image quality and confidence levels ( $p=0.000$ ; Table 5). The mean of the four observer scores was used for this analysis.

## Discussion

Advances in medical imaging bring new challenges for implant surgeons. Suitable treatment planning is a basic step of implant therapy for the selection of an implant with the appropriate size, dimensions, and location. Indeed, with the PAN view, the practitioner cannot evaluate the complexity of the bone volume because the data are presented in a 2D format that superimposes the different structures. Neither small bone volume nor their particular orientation can be properly assessed by the surgeon. Jacobs et al<sup>10</sup> have demonstrated that the main advantage of a 3D image is the full integration of various treatment factors overlapping the anatomical model with a virtual treatment. This study does not address a key issue where CBCT may be of advantage, that is, in the 3D implant position. Our study did not give any information on angulation in any direction or bucco-lingual position. A study to address this could only be conducted as a laboratory design by using jaw models.

Several factors have a negative impact on the reliability of panoramic radiographs. They are the 2D projection of a 3D volume, with inherent distortion and magnification, particularly in the upper premolar region. This might make planning more haphazard and less reliable. Oblique projection geometry also hampers good visualization. On the other hand, other studies have reported that digital panoramic radiographs with 1 : 1 adjusted images are sufficiently accurate and reliable for evaluating the available bone height above the mandibular canal. Vazquez et al<sup>11</sup> found that the implant length measurement was sufficiently reliable for evaluating the vertical magnification factor even when the patient's head position was not strictly standardized before exposure and when measurements were taken by observers with different skill levels and experi-



ence. The same author found similar results in another study on digital panoramic radiographs.<sup>12</sup>

The aim of our study was to produce a realistic treatment plan for implant placement. Therefore, the observers were experienced implant surgeons instead of oral maxillofacial radiologists. Considering oral radiologists as observers was discarded due to their specific training on looking at the anatomy and diagnosis. In this context, Algerban et al<sup>13</sup> reported that radiologists' evaluations of image quality and detection of root resorption scored higher than the observational scoring by orthodontic instructors and post-graduate residents because radiologists had more experience and training in assessing resorption on root surfaces. A recent article on the accuracy of vertical height measurements on direct digital panoramic radiographs reported that an observer's experience had no clinically significant influence on the measurements even though, interestingly, a less-experienced observer had a lower distortion ratio than a more-experienced observer.<sup>12</sup> Reporting all observers' data was very important: If two observers generally chose longer implants with CBCT and two generally chose shorter, in the overall combined results they could seem to cancel each other. In our study, we reported the four observers' results. Based on our results, we could recommend choosing a vertical safety margin in the posterior mandible in all cases. Similarly, Gerlach et al<sup>14</sup> suggested a vertical safety margin of at least 1.7 mm when CBCT images are used to select implants for the posterior mandible. This is close to the reported recommendations for PAN.<sup>15</sup> This safety margin can avoid iatrogenic inferior alveolar nerve injuries following dental implant placement. However, Renton et al<sup>16</sup> found that a majority of idiopathic trigeminal neuropathies were found in patients who had undergone presurgical 2D radiographs (90%), while only 10% of the cases presented such neuropathies after presurgical CBCT had been taken.

Additionally, the clinical procedure of combining radiographic information of different types of images (for example, PAN plus CBCT) often used for the planning of an implant site was followed in this study. An adequate determination of the bone height is recommended for avoiding the potential risks of intrusion of implants into vital anatomical structures including nerves, blood vessels, and impacted or supernumerary teeth.<sup>17</sup> The buccolingual width and angulation of the available bone are the most important criteria for implant selection and success. According to Alsaadi et al<sup>18</sup> the implant diameter and location significantly affected the implant loss.

Schropp et al<sup>19</sup> compared PAN and conventional cross-

sectional tomography with regard to the preoperative selection of implant size for three implant systems. They found that in the maxillary and mandibular anterior regions, approximately 50% of the selected implants were narrower on tomograms, while this was <10% in the posterior regions. Their result was not in agreement with the results of the present study. The reason for this disagreement could be that they only used one observer. As decision making could be very subjective, it could easily explain the difference.

Renouard and Nisand<sup>20</sup> conducted a review to evaluate the survival rate of dental implants related to their length and diameter. Concerning implant length, a relatively high number of published studies<sup>21,22</sup> indicated an increased failure rate with short implants, which was associated with the surgeons' learning curves, routine surgical preparation (independent of the bone density), use of machined-surface implants, and placement in sites with poor bone density. Other publications<sup>23,24</sup> reported that an adapted surgical preparation and the use of textured-surface implants have produced survival rates of short implants comparable with those obtained with longer ones. Considering the implant diameter, a few publications on wide-diameter implants have reported an increased failure rate. These publications have demonstrated that the implant survival rate and diameter showed no relationship.<sup>23,24</sup>

Our results showed that when planning implant location, both PAN and CBCT planning agreed. Further, in 1999, Jacobs et al<sup>25</sup> reported that both 2D and 2D+3D planning on multi-slice computed tomography (MSCT) images had a good predictability for the number and site of the implants.

Our study revealed that CBCT had little influence on the presurgical determination of implant width because a majority of the cases remained unchanged after using CBCT and the changes were equally distributed between the increase and the decrease in the length and the width. This means that the examiners performed highly reproducible presurgical planning under the two different diagnostic conditions, suggesting that no additional information is provided by tomograms regarding implant width. However, in comparing CBCT and PAN, the implant lengths were different for the two observers in our study, with a trend towards the selection of longer implants using PAN.

Other studies have reported on the variation in the presurgical treatment planning after using conventional spiral tomography in addition to conventional radiographic exams. Frei et al<sup>26</sup> showed that conventional spiral tomography had a minor impact on the treatment planning of implant dimensions in posterior mandible cases. In their

study, treatment plans with and without spiral tomograms were identical in 74 of 77 (96.1%) implant sites. In only 3.9% of these cases, implant diameters had changed, while no changes occurred in the implant length after the use of tomograms. In another study, the variation in implant dimension was not affected by the location of edentulous areas after using conventional spiral tomography.<sup>27</sup>

It is reasonable to question the impact of CT and CBCT on implant treatment planning and the final outcome because only a few studies have evaluated this. Jacobs et al<sup>10</sup> demonstrated that reformatted 2D CT is reliable for treatment planning, but only to a certain extent, whereas Reddy et al<sup>28</sup> demonstrated an advantage of CT in predicting the implant length before implant surgery.

Although decisions to change the actual dimensions of implants during surgical placement are likely to occur, new imaging techniques might improve the surgeon's capacity to variations in the clinical scenario. Subjective image quality grading is widely used as an alternative to objective assessment, as it better reflects the clinical value of an image. Image quality assessment of cross-sectional imaging methods has been widely studied.<sup>29,30</sup> Loubele et al<sup>31</sup> reported the first publication on this field; the subjective image quality of CBCT images was significantly better than for MSCT with respect to the visualization and delineation of the lamina dura and the periodontal ligament space. However, the image quality of cross-sectional imaging methods and PAN radiographs in relation to implant surgery has not been studied.

Little has been published regarding the confidence levels gained in treatment decisions when using CBCT as an adjunct imaging technique for implant planning. This was the first study that stressed this issue and provided new insight into the therapeutic efficacy of CBCT in a larger sample. Recently, Baciut et al<sup>32</sup> reported that CBCT increased surgical confidence in treatment planning over that by means of PAN imaging. There is a question, however, about the value of the surgeons' confidence. Unless this manifests as an improved experience for patients, for example, by a shortened operating time or by improved outcomes, the impact of "confidence" can be questioned. Indeed, it could be argued that excessive confidence may lead to a less meticulous surgical technique. This underlines the need for the future emphasis of research to be focused on measurable patient outcomes.

All these differences should be carefully interpreted in the absence of a true gold standard for implant success. The comparison of implant planning based on PAN and CBCT images is complicated, as a randomized controlled

trial is difficult to establish, considering that there are few matching cases. The treatment outcome not only depends on the anatomical requirements and surgical challenges, but also on the actual needs (fixed, removable), the existing therapeutic options, and the aesthetic demands and antagonistic relations. A remark along the same lines could be made with respect to a bone structural analysis in order to avoid regions with remnant lesions or structurally inferior bone sites.

Finally, the measurements had acceptable accuracy and reproducibility when a software-based calibrated measurement tool was used, confirming that either PAN or CBCT can be reliably utilized to determine the preoperative implant width. However, care should be taken when using PAN-based preoperative planning of implants with a predisposition to select longer implant lengths in a posterior area and therefore, a more risky location. In addition, CBCT can allow observers to plan implant surgery with an improved subjective image quality and higher surgical confidence.

## References

1. Belser UC, Schmid B, Higginbottom F, Buser D. Outcome analysis of implant restorations located in the anterior maxilla: a review of the recent literature. *Int J Oral Maxillofac Implants* 2004; 19 Suppl: 30-42.
2. Lindquist LW, Carlsson GE, Jemt T. A prospective 15-year follow-up study of mandibular fixed prostheses supported by osseointegrated implants. Clinical results and marginal bone loss. *Clin Oral Implants Res* 1996; 7: 329-36.
3. Flanagan D. Important arterial supply of the mandible, control of an arterial hemorrhage, and report of a hemorrhagic incident. *J Oral Implantol* 2003; 29: 165-73.
4. Greenstein G, Cavallaro J, Romanos G, Tarnow D. Clinical recommendations for avoiding and managing surgical complications associated with implant dentistry: a review. *J Periodontol* 2008; 79: 1317-29.
5. Van Assche N, van Steenberghe D, Guerrero ME, Hirsch E, Schutyser F, Quirynen M, et al. Accuracy of implant placement based on pre-surgical planning of three-dimensional cone-beam images: a pilot study. *J Clin Periodontol* 2007; 34: 816-21.
6. SEDENTEXCT Guideline Development Panel. Radiation protection No 172. Cone beam CT for dental and maxillofacial radiology. Evidence based guidelines. Luxembourg: European Commission Directorate-General for Energy; 2012.
7. Harris D, Horner K, Gröndahl K, Jacobs R, Helmrot E, Benic GI, et al. E.A.O. guidelines for the use of diagnostic imaging in implant dentistry 2011. A consensus workshop organized by the European Association for Osseointegration at the Medical University of Warsaw. *Clin Oral Implants Res* 2012; 23: 1243-53.
8. Jacobs R, Quirynen M. Dental cone beam CT and its justified use for planning oral implant placement. *Periodontol* 2000 (in

- press).
9. Bornstein MM, Scarfe WC, Vaughn VM, Jacobs R. Cone beam computed tomography in implant dentistry: a systematic review focusing on guidelines, indications, and radiation dose risks. *Int J Oral Maxillofac Implants* 2014; 29 Suppl: 55-77.
10. Jacobs R, Adriansens A, Naert I, Quirynen M, Hermans R, Van Steenberghe D. Predictability of reformatted computed tomography for pre-operative planning of endosseous implants. *Dentomaxillofac Radiol* 1999; 28: 37-41.
11. Vazquez L, Nizam Al Din Y, Christoph Belser U, Combescure C, Bernard JP. Reliability of the vertical magnification factor on panoramic radiographs: clinical implications for posterior mandibular implants. *Clin Oral Implants Res* 2011; 22: 1420-5.
12. Vazquez L, Nizamaldin Y, Combescure C, Nedir R, Bischof M, Dohan Ehrenfest DM, et al. Accuracy of vertical height measurements on direct digital panoramic radiographs using posterior mandibular implants and metal balls as reference objects. *Dentomaxillofac Radiol* 2013; 42: 20110429.
13. Algerban A, Jacobs R, Fieuws S, Willems G. Comparison of two cone beam computed tomographic systems versus panoramic imaging for localization of impacted maxillary canines and detection of root resorption. *Eur J Orthod* 2011; 33: 93-102.
14. Gerlach NL, Meijer GJ, Maal TJ, Mulder J, Rangel FA, Borstlap WA, et al. Reproducibility of 3 different tracing methods based on cone beam computed tomography in determining the anatomical position of the mandibular canal. *J Oral Maxillofac Surg* 2010; 68: 811-7.
15. Vazquez L, Saulacic N, Belser U, Bernard JP. Efficacy of panoramic radiographs in the preoperative planning of posterior mandibular implants: a prospective clinical study of 1527 consecutively treated patients. *Clin Oral Implants Res* 2008; 19: 81-5.
16. Renton T, Dawood A, Shah A, Searson L, Yilmaz Z. Post-implant neuropathy of the trigeminal nerve. A case series. *Br Dent J* 2012; 212: E17.
17. Benavides E, Rios HF, Ganz SD, An CH, Resnik R, Reardon GT, et al. Use of cone beam computed tomography in implant dentistry: the International Congress of Oral Implantologists consensus report. *Implant Dent* 2012; 21: 78-86.
18. Alsaadi G, Quirynen M, Michiles K, Teughels W, Komárek A, van Steenberghe D. Impact of local and systemic factors on the incidence of failures up to abutment connection with modified surface oral implants. *J Clin Periodontol* 2008; 35: 51-7.
19. Schropp L, Stavropoulos A, Gotfredsen E, Wenzel A. Comparison of panoramic and conventional cross-sectional tomography for preoperative selection of implant size. *Clin Oral Implants Res* 2011; 22: 424-9.
20. Renouard F, Nisand D. Impact of implant length and diameter on survival rates. *Clin Oral Implants Res* 2006; 17 Suppl 2: 35-51.
21. Herrmann I, Lekholm U, Holm S, Kultje C. Evaluation of patient and implant characteristics as potential prognostic factors for oral implant failures. *Int J Oral Maxillofac Implants* 2005; 20: 220-30.
22. Weng D, Jacobson Z, Tarnow D, Hürzeler MB, Faehn O, Sanavi F, et al. A prospective multicenter clinical trial of 3i machined-surface implants: results after 6 years of follow-up. *Int J Oral Maxillofac Implants* 2003; 18: 417-23.
23. Lemmerman KJ, Lemmerman NE. Osseointegrated dental implants in private practice: a long-term case series study. *J Periodontol* 2005; 76: 310-9.
24. Romeo E, Lops D, Margutti E, Ghisolfi M, Chiapasco M, Vogel G. Long-term survival and success of oral implants in the treatment of full and partial arches: a 7-year prospective study with the ITI dental implant system. *Int J Oral Maxillofac Implants* 2004; 19: 247-59.
25. Jacobs R, Adriansens A, Verstreken K, Suetens P, van Steenberghe D. Predictability of a three-dimensional planning system for oral implant surgery. *Dentomaxillofac Radiol* 1999; 28: 105-11.
26. Frei C, Buser D, Dula K. Study on the necessity for cross-section imaging of the posterior mandible for treatment planning of standard cases in implant dentistry. *Clin Oral Implants Res* 2004; 15: 490-7.
27. Diniz AF, Mendonça EF, Leles CR, Guilherme AS, Cavalcante MP, Silva MA. Changes in the pre-surgical treatment planning using conventional spiral tomography. *Clin Oral Implants Res* 2008; 19: 249-53.
28. Reddy MS, Mayfield-Donahoo T, Vandervan FJ, Jeffcoat MK. A comparison of the diagnostic advantages of panoramic radiography and computed tomography scanning for placement of root form dental implants. *Clin Oral Implants Res* 1994; 5: 229-38.
29. Liang X, Jacobs R, Hassan B, Li L, Pauwels R, Corpas L, et al. A comparative evaluation of cone beam computed tomography (CBCT) and multi-slice CT (MSCT) Part I. On subjective image quality. *Eur J Radiol* 2010; 75: 265-9.
30. Shelley AM, Brunton P, Horner K. Subjective image quality assessment of cross sectional imaging methods for the symphyseal region of the mandible prior to dental implant placement. *J Dent* 2011; 39: 764-70.
31. Loubele M, Guerrero ME, Jacobs R, Suetens P, van Steenberghe D. A comparison of jaw dimensional and quality assessments of bone characteristics with cone-beam CT, spiral tomography, and multi-slice spiral CT. *Int J Oral Maxillofac Implants* 2007; 22: 446-54.
32. Baciut M, Hedesiu M, Bran S, Jacobs R, Nackaerts O, Baciut G. Pre- and postoperative assessment of sinus grafting procedures using cone-beam computed tomography compared with panoramic radiographs. *Clin Oral Implants Res* 2013; 24: 512-6.