

## A Case of Asymptomatic Giant Cystic Pheochromocytoma

Sang-Hoon Lee<sup>1</sup>, Seungkoo Lee<sup>2</sup>, Sang-Wook Kim<sup>1</sup>, Eun-Hee Cho<sup>1</sup>

Departments of Internal Medicine<sup>1</sup> and Anatomic Pathology<sup>2</sup>, Kangwon National University School of Medicine, Chuncheon, Korea

A 28-year-old woman presented with adrenal incidentaloma, discovered by abdominal ultrasonography during a routine checkup for chronic hepatitis B. The physical examination showed a height of 168 cm and weight of 49 kg (body mass index, 17.4 kg/m<sup>2</sup>). The patient's systolic/diastolic blood pressure was 123/69 mmHg and her heart rate was 64 beats/min. Her medical history and a review of her systems were unremarkable, except for chronic hepatitis B. Laboratory examinations revealed the following: white blood cells, 3,800/mm<sup>3</sup> (neutrophils, 56.0%; lymphocytes, 33.0%; monocytes, 9.0%; eosinocytes, 1.0%); hemoglobin, 13.7 g/dL; hematocrit, 37.6%; platelets, 183,000/mm<sup>3</sup>; blood sugar, 86 mg/dL; sodium, 140 mmol/L; potassium, 3.6 mmol/L; and chlorine, 105 mmol/L. Serum biochemical tests yielded the following values: aspartate aminotransferase, 32 IU/L; alanine aminotransferase, 37 IU/L; alkaline phosphatase, 28 IU/L; total bilirubin, 0.90 mg/dL; blood urea nitrogen, 4.2 mg/dL; creatinine, 0.5 mg/dL; total protein, 7.3 g/dL; and albumin, 4.2 g/dL. Abdominal computed tomography (CT) revealed a 6.7-cm adrenal cystic tumor with an internal enhancing septum that occupied the right upper quadrant (Fig. 1). There were no clinical symptoms or signs suggesting pheochromocytoma. Biochemical studies of the adrenal incidentaloma showed normal values, although the 24-hour urinary vanillylmandelic acid (VMA) and metanephrine levels were in their respective upper normal ranges. According to the literature, pheochromocytoma could not be ruled out because the VMA and metanephrine levels were in their respective upper normal ranges; patients with cystic pheochromocytoma may not display typical symptoms or biochemical laboratory data. Treatment with low-dose alpha-1 adrenergic antagonist (terazosin HCl, 2 mg/day) for 2 weeks was initiated before surgical resection because of the patient's relatively low blood pressure and the suspicion of cystic pheochromocytoma. The patient tolerated low-dose alpha blockers. Laparoscopic

right adrenalectomy was performed. The surgical specimen was a pinkish yellowish white cystic mass measuring 9.5 × 4 × 1.2 cm. A high-power photomicrograph showed that the tumor cells were arranged in a solid and diffuse pattern. The results of immunohistochemical analysis showed that the specimen was positive for chromogranin and synaptophysin, but negative for S100 protein (Fig. 2). The final pathologic diagnosis was cystic pheochromocytoma. During 3 months of follow-up after surgery, the patient remained stable and biochemical tests showed that her 24-hour urinary VMA and metanephrine decreased to 3.11 mg/day and 0.21 mg/day, respectively. Genetic tests for RET and von Hippel-Lindau mutations failed to reveal any abnormalities.

Pheochromocytoma is a surgically curable disease that causes hypertension. While cystic adrenal tumors are uncommon, pheochromocytoma with cyst formation is extremely rare [1].

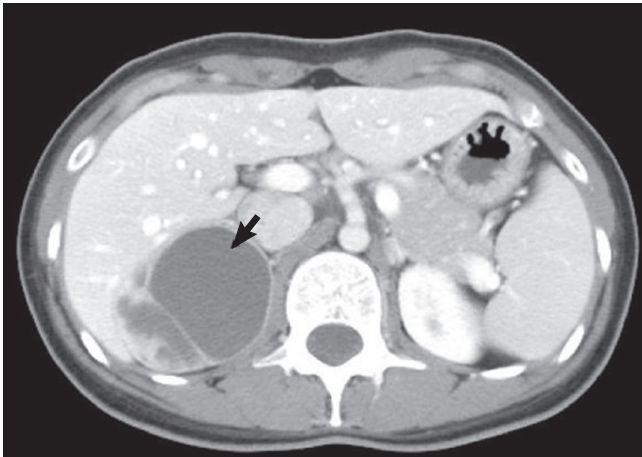
Most cystic adrenal tumors are adrenal real cysts (endothelial and epithelial), pseudocysts, and parasitic cysts, which are benign. Adrenal carcinoma or pheochromocytoma is rare cystic adrenal tumors [2]. Pheochromocytomas vary in size and weight and have highly variable clinical features. Cystic pheochromocytomas are unilateral in 90% of cases, and the sizes of cystic tumors vary on average 9.5-50 cm [3,4]. Unlike patients with solid pheochromocytomas, patients with cystic pheochromocytomas may not show typical clinical manifestations or elevated urine and serum levels of catecholamine metabolites. In cases of cystic adrenal tumors, investigation of functional adrenal tumors including pheochromocytoma is mandatory because of the possibility of pheochromocytoma without suggestive clinical or laboratory findings. To the best of our knowledge, the presented case of asymptomatic adrenal cystic pheochromocytoma is the first in Korea. There has been one report of a 50-year-old woman with adrenal cystic pheochromocytoma.

Corresponding author: Eun-Hee Cho

Department of Internal Medicine, Kangwon National University Hospital,  
Kangwon National University School of Medicine, 156 Baengnyeong-ro, Chuncheon  
200-722, Korea  
Tel: +82-33-258-9167, Fax: +82-33-256-2146, E-mail: ehcho@kangwon.ac.kr

Copyright © 2012 Korean Endocrine Society

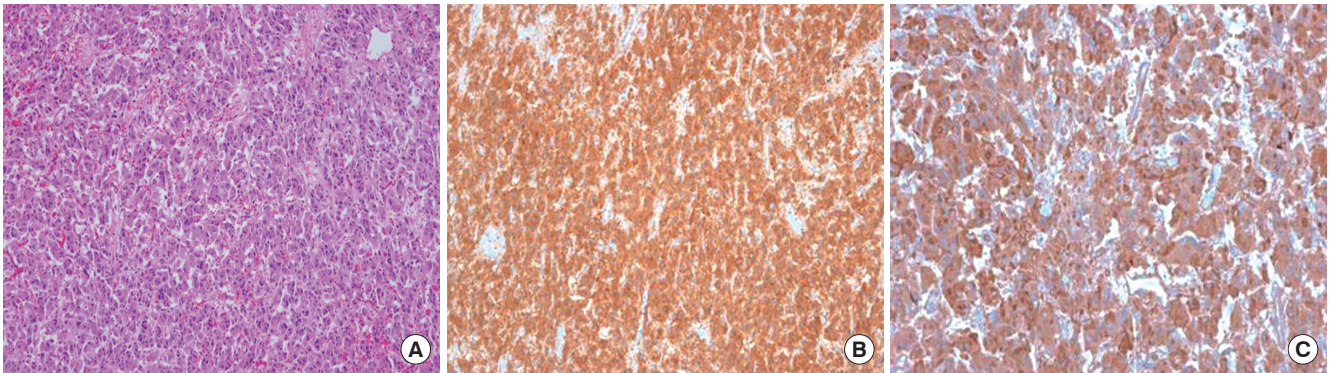
This is an Open Access article distributed under the terms of the Creative Commons Attribution Non-Commercial License (<http://creativecommons.org/licenses/by-nc/3.0/>) which permits unrestricted non-commercial use, distribution, and reproduction in any medium, provided the original work is properly cited.



**Fig. 1.** Contrast-enhanced computed tomography scan shows about 6.7 cm sized round low density lesion with internal enhancing septum and a tiny calcification in the right suprarenal region (arrow).

toma accompanied by sepsis, elevation of 24-hour urinary VMA and metanephrine levels, and clinically uncontrolled hypertension [5].

Our patient showed no clinical symptoms or signs suggesting pheochromocytomas, although her 24-hour VMA and metanephrine levels were in their respective upper reference ranges. However, after reviewing the literature, we suspected asymptomatic pheochromocytoma without definite evidence of catecholamine excess. Cystic pheochromocytomas are extremely rare lesions, and they are often not accurately diagnosed during clinical and biochemical evaluations before surgical resection. When faced with an adrenal cystic lesion, the physician should consider with high suspicion cystic pheochromocytoma because failure to recognize this condition before surgery may lead to a high operative risk.



**Fig. 2.** A. Microscopic findings of tumor cells (H&E stain,  $\times 200$ ). B, C. Immunohistochemistry stain of pheochromocytoma ( $\times 200$ ). The tumor cells are strongly positive for synaptophysin (B) and chromogranin (C).

## REFERENCES

1. Erickson LA, Lloyd RV, Hartman R, Thompson G: Cystic adrenal neoplasms. *Cancer* 101:1537-1544, 2004
2. Foster DG: Adrenal cysts. Review of literature and report of case. *Arch Surg* 92:131-143, 1966
3. Scheible W, Coel M, Siemers PT, Siegel H: Percutaneous aspiration of adrenal cysts. *AJR Am J Roentgenol* 128:1013-1016, 1977
4. Esquivel E Jr, Grabstald H: Giant adrenal cyst. *J Urol* 94:635-638, 1965
5. Oh MM, Jung CS, Myoung SC, Moon WC: A case of cystic pheochromocytoma. *Korean J Urol* 31:772-776, 1990