

Spinal Cord Injury Caused by a Stab Wound

—A Case Report—

Hwan Mo Lee¹, Nam Hyun Kim¹ and Chang Il Park²

The authors present a case of incomplete spinal cord injury (Brown Sequard syndrome) after a stab wound. A direct history and examination revealed that the patient was stabbed in the back while fighting with his friends. He immediately lost motor and sensory function in the lower extremities and collapsed to the ground. The patient was given primary closure after wound toilet and was treated with antibiotics. With rehabilitation he became ambulatory with a cane and long leg brace two months after the stabbing.

Key Words: Spinal cord injury, stab wound, Brown-Sequard injury

Stab wounds of the spinal cord in the civilian population are relatively rare, and none have been reported in Korean literature to the best of our knowledge. They can present difficult problems with regard to diagnosis and treatment, particularly if there are multiple entrance wounds. Even with a single entrance wound, the site of injury to the cord may be at a different level from the skin entrance wound, and the prevention of CNS infection is very important. We report a patient who presented Brown-Sequard syndrome after stabbing and became ambulatory with rehabilitation treatment.

CASE PRESENTATION

A 20-year-old man was brought to the emergency room by stretcher car after he was stabbed during a fight with his friends. He stated that while he was fighting, he felt a burning pain in his back and then he lost motor power in his right leg. He denied syncope, dizziness, aura or chest pain.

Vital signs were as follows: blood pressure, 130/80 mmHg; pulse, 86; respiration, 20; and temperature, 36.5°C. On physical examination, the back had a 2cm oblique laceration in the mid back to the right of the

midline, the lungs were clear, and the abdomen was soft and nontender.

On neurologic examination, the right lower extremity had no motor strength and lacked position and vibration sense below the T12 level. The left lower extremity had no pain and temperature sense below the L1 level. Deep tendon reflexes were hyperactive in the right lower extremity and slightly increased in the left side. The perianal pinprick test was positive and bulbocavernosus reflex and rectal tone were absent.

The following tests were normal: CBC, urinalysis, electrolytes, and blood chemistry. A chest radiograph showed no pneumothorax, and spine radiographs showed no fracture of vertebrae or abnormal findings (Fig. 1 A and B).

Lumbar puncture revealed blood-retained CSF and myelography was performed using 10ml of iopamidol 300 (Niopam; E. Merck Ltd.). Screening in the prone position showed no leakage of radiopaque dye (Fig. 2), but when supine screening was performed, contrast medium was shown passing through a tear in the dura (Fig. 3). Two hours after myelography, a computerized axial tomogram was performed. It revealed retained dye in the probable path of the knife through the cord (Fig. 4), and extravasation of contrast medium in the epidural space (Fig. 5). On coronal and sagittal reconstruction, extravasation of contrast medium was noted between the T9 and T10 level (Fig. 6 A and B).

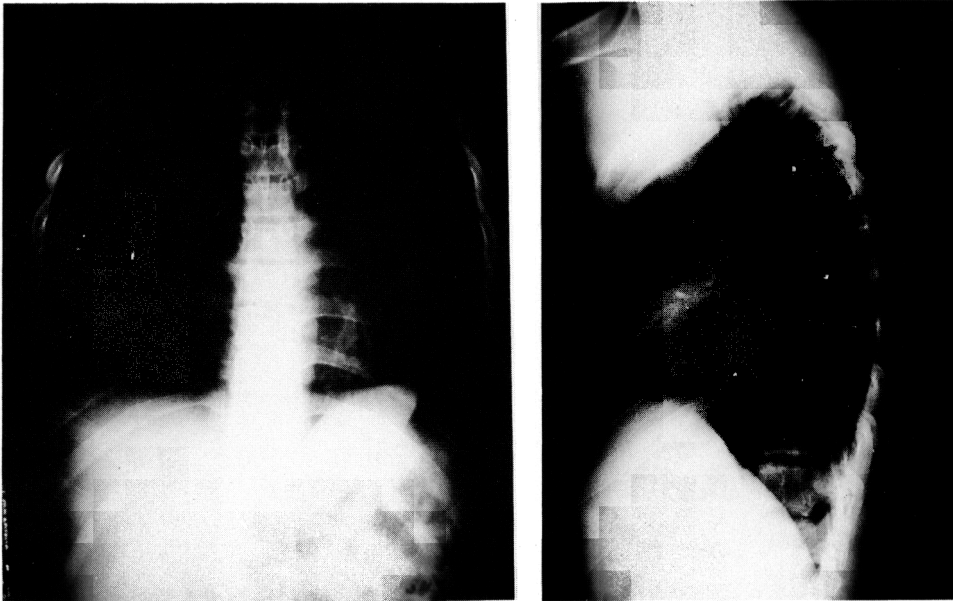
The patient was diagnosed as having a right hemisection of the spinal cord at the T9-10 level. Primary closure of the laceration was done after

Received April 2, 1990

Accepted May 7, 1990

Departments of Orthopaedic Surgery¹ and Rehabilitation Medicine², Yonsei University College of Medicine, Seoul, Korea

Address reprint requests to Dr. H M Lee, Department of Orthopaedic Surgery, Yonsei University College of Medicine, C.P.O. Box 8044, Seoul, Korea, 120-752



*Fig. 1-A,B. A) A-P view of the thoracolumbar spine.
B) Lateral view of the thoracolumbar spine. No evidence of vertebral fracture is noted.*

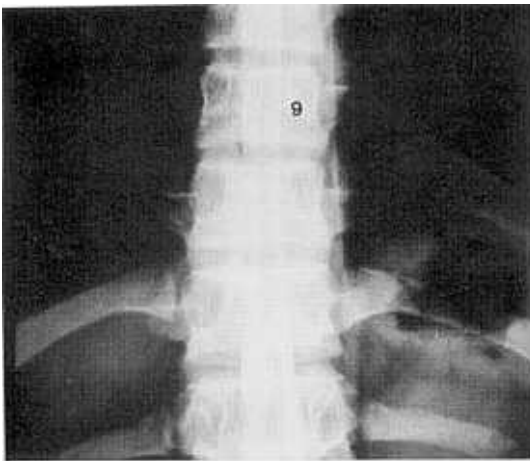


Fig. 2. Myelography with prone position. No leakage of contrast medium is noted.

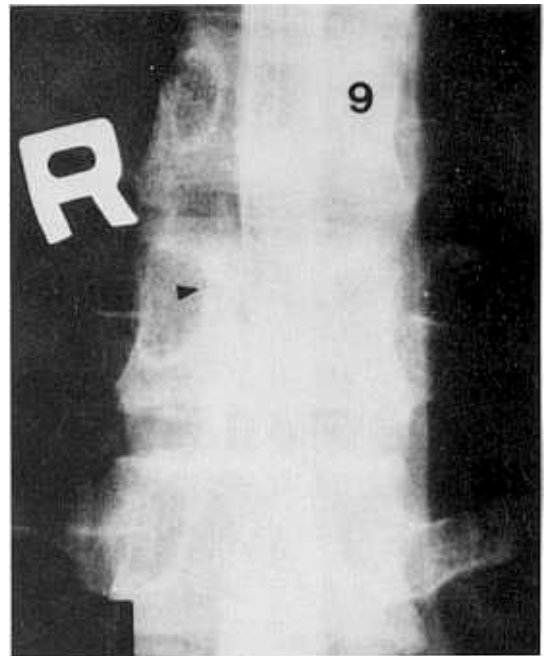


Fig. 3. Myelography with supine position. Extravasation of contrast medium through the tear of dura is seen (arrowhead).

wound toilet , and intravenous antibiotics were administered. Intermittent Nelaton catheterization was begun and voiding by the Valsalva method was tried on the 10th day after admission. On the 14th day, the sutures were removed and he was transferred to the

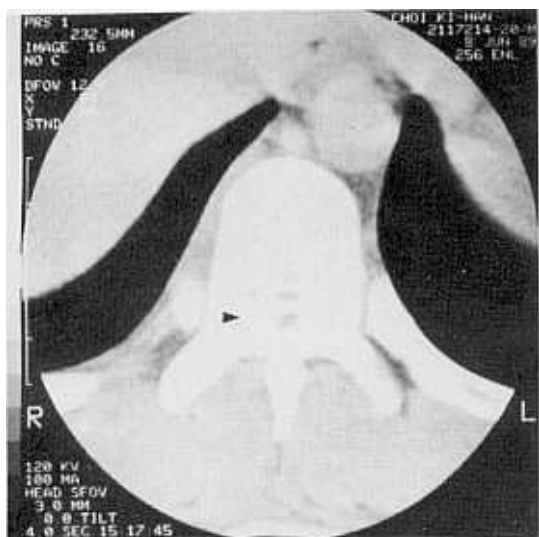


Fig. 4. CTMM finding at T9 level. Arrowhead indicates the probable path of the knife through the cord.

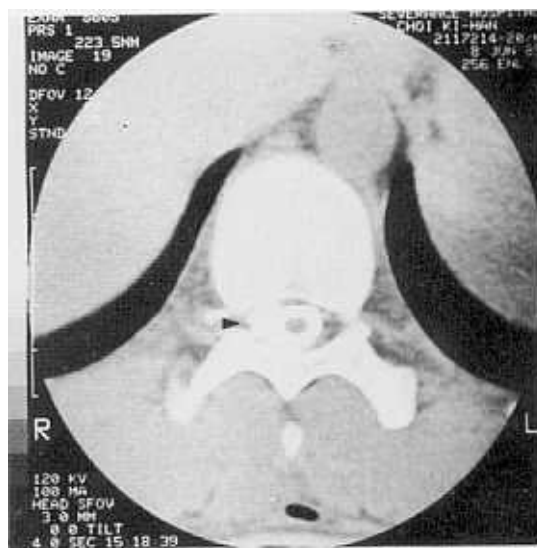

Fig. 5. CTMM finding at T9-10 level. Extravasation of dye in the epidural space is noted.


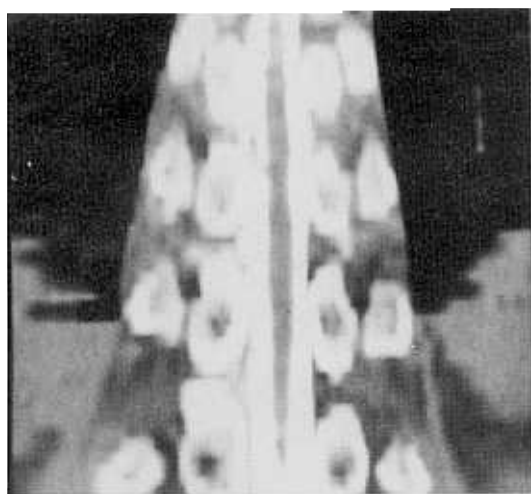


Fig. 6-A,B. A) Coronal reconstruction B) Sagittal reconstruction. Contrast medium in the posterior and right side of the epidural space is observed.

Department of Rehabilitation Medicine.

One month later, he started the parallel bar walking exercise with a right long leg brace. At this time he obtained an improved sensory level of L4 in the left leg. Two months later, he was discharged with mild recovery of motor function of his right leg. Now he can walk with a mono cane and right long leg brace.

DISCUSSION

Stab wounds to the spinal cord are relatively infrequent, especially recently (Gentleman and Harrington 1984; Herr and Barrett 1983). The largest reported series came from South Africa. Lipschitz and Block (1962) reported 130 cases of stab wounds to

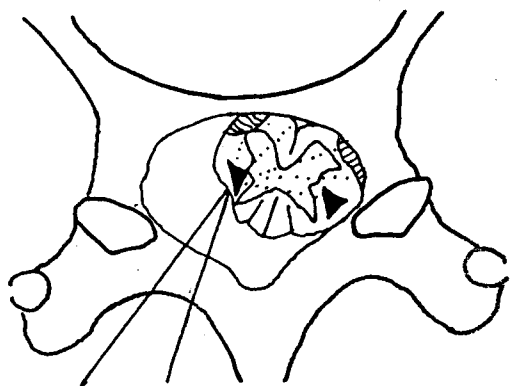


Fig. 7. Spinal cord concussion and contusion which are associated with some stab wounds.

the spine and Lipschitz (1967) reported 252 cases over a 12 1/2-year period. Peacock *et al.* (1977) reported 450 patients with stab wounds to the spinal cord in 13 years, representing over 1/4 of the patients admitted with spinal cord injury. In their series, 63% of the wounds were in the thoracic region, 30% in the cervical region, and 7% in the lumbar region. Knives accounted for 84% of the weapons used, followed by axes, screwdrivers, bicycle spokes, and scissors. This patient was attacked by a knife.

Fifty-five percent of the patients had incomplete Brown-Sequard syndrome. Peacock *et al.* (1977) attributed the high incidence of damage to only half the cord by the anatomy of the vertebral column: the transverse processes extend laterally and backwards, and with the spinous process in the midline, produce a gutter along which the knife blade would run before entering the space between the laminae. Because of the gutter, the blade would tend not to cross the midline, and it is prevented from deviating laterally by the backward projection of the transverse process.

The original description of Brown-Sequard syndrome in 1849 emphasized a contralateral distal loss of pinprick sensation and ipsilateral distal limb paralysis. Upper motor neuron paralysis stems from disruption of the descending corticospinal tracts containing the 90% of the motor neurons axons from the cerebral cortex that have already crossed in the lower medulla and will exit without crossing again. Of the ascending sensory fibers, those conveying position and vibration enter through the dorsal root ganglion. They ascend ipsilaterally, perhaps in the spinocerebellar tract, and a lesion causes ipsilateral loss of proprioception and

vibration up to the level of the lesion (Ross *et al.* 1977).

In contrast, pain and temperature fibers, while entering through the dorsal root ganglion, ascend in Lissauer's tract for one or two segments before synapsing and crossing to ascend in the lateral spinothalamic tract. Hemisection, therefore, produced contralateral pain and temperature deficit beginning one or two segments below the lesion (Herr and Barrett 1987). In this patient, position and vibration sense were impaired below the T12 level in the right side but pain and temperature sense were absent below the L1 level in the left lower extremity.

Lipschitz and Block (1962) postulated three mechanisms whereby the spinal cord may be injured: (1) the weapon may damage the cord directly, or indriven bone fragments may produce spinal cord damage, (2) the vascular supply of the spinal cord may be damaged with resulting edema, and (3) counter-coup spinal cord concussion or contusion may injure the cord. The penetrating knife blade causes local damage to the cord at the site of impact, and in addition, the force of the blow carries the cord forward to impinge on the walls of the bony spinal canal (Fig. 7). In all probability the neurologic disability is dependent to some extent on all three of the above mentioned mechanisms.

An important aspect of the water-soluble contrast medium myelogram was that the patient was screened in the supine position. Water-soluble contrast medium is heavier than CSF and will not enter the track of the dorsal wound in the prone position, which is the position normally used for myelography (Sutton and DeSilva 1984). And our case demonstrated this point. Recently the MR imaging of the incisional spinal cord injury has been reported (Mayer and Kulkarni 1987).

The initial treatments of the spinal cord injury caused by a stab wound were local debridement, primary closure of the wound, and intravenous administration of antibiotics to prevent CNS infection. Indications for operative intervention were retained foreign body, persistent CSF leakage, and sepsis (e.g., epidural abscess or granuloma) (Adornato and Collis 1972). In this patient, the stab wound was healed primarily without serious complications.

The general management of the paraplegic, including prevention and treatment of bedsores and bladder complications, should be done immediately after admission. It is important to point out that since the mechanics and weight-bearing functions of the spinal column are not impaired, early mobilization may be permitted, provided there are no severe associated injuries.

The best management continues to be based on accurate clinical diagnosis, limited investigations and effective prophylaxis against CNS infection, with operative intervention playing only a very small role. Violence in Korean cities is increasing, and it is important that surgeons be aware of this uncommon and serious complication of stab injuries.

REFERENCES

- Adornato DC Jr, Collis JS Jr: Stab wounds of the spinal cord. *Int Surg* 57:147, 1972
- Gentleman D, Harrington M: Penetrating injury of the spinal cord. *Injury* 16:7, 1984
- Herr RD, Barrett J: An unusual presentation of Brown-Sequard syndrome. *Ann Emerg Med* 12:581, 1983
- Lipschitz R: Associated injuries and complications of stab wounds of the spinal cord. *Paraplegia* 5:75, 1967
- Lipschitz R, Block J: Stab wounds of the spinal cord. *Lancet* July 28:169, 1962
- Mayer JR, Kulkarni MV: MR imaging of incisional spinal cord injury. *AJNR* 8:925, 1987
- Peacock WJ, Shrosbree RD, Key AG: A review of 450 stab wounds of the spinal cord. *S Afr Med J* 51:961, 1977
- Ross ED, Kirkpatrick JB, Lastimosa ACB: Position and vibration sensations: Functions of the dorsal spinocerebellar tracts? *Ann Neurol* 5:171, 1977
- Sutton D, DeSilva RDD: Water-soluble contrast medium in the localization of cord and dural stab wound. *Clin Radiol* 34:483, 1984
-