

# Ruptured Corpus Luteal Cyst: CT Findings

Hyuck Jae Choi, MD  
Seung Hyup Kim, MD  
Sun Ho Kim, MD  
Hyo-Cheol Kim, MD  
Chang Min Park, MD  
Hak Jong Lee, MD  
Min Hoan Moon, MD  
Jun Yong Jeong, MD

## Index terms:

Computed tomography (CT)  
Cysts  
Hemorrhage  
Ovary

**Korean J Radiol 2003;4:42-45**

Received March 28, 2002; accepted  
after revision January 4, 2003.

All Authors; Department of Radiology,  
Seoul National University College of  
Medicine Institute of Radiation Medicine;  
Seoul National University Medical  
Research Center, Clinical Research  
Institute, Seoul National University  
Hospital, Seoul, Korea

## Address reprint requests to:

Seung Hyup Kim, MD, Department of  
Radiology, Seoul National University  
College of Medicine, 28 Yongon-dong,  
Chongno-gu, Seoul 110-744, Korea.  
Telephone: (822) 760-2584  
Fax: (822) 743-6385  
e-mail: kimsh@radcom.snu.ac.kr

**Objective:** To evaluate the CT findings of ruptured corpus luteal cysts.

**Materials and Methods:** Six patients with a surgically proven ruptured corpus luteal cyst were included in this series. The prospective CT findings were retrospectively analyzed in terms of the size and shape of the cyst, the thickness and enhancement pattern of its wall, the attenuation of its contents, and peritoneal fluid.

**Results:** The mean diameter of the cysts was 2.8 (range, 1.5–4.8) cm; three were round and three were oval. The mean thickness of the cyst wall was 4.7 (range, 1–10) mm; in all six cases it showed strong enhancement, and in three was discontinuous. In five of six cases, the cystic contents showed high attenuation. Peritoneal fluid was present in all cases, and its attenuation was higher, especially around the uterus and adnexa, than that of urine present in the bladder.

**Conclusion:** In a woman in whom CT reveals the presence of an ovarian cyst with an enhancing rim and highly attenuated contents, as well as highly attenuated peritoneal fluid, a ruptured corpus luteal cyst should be suspected. Other possible evidence of this is focal interruption of the cyst wall and the presence of peritoneal fluid around the adnexa.

Ovarian cysts are the most common cause of adnexal masses, and hemorrhage into the cyst is a frequent and well-known complication. If accompanied by significant bleeding, its rupture is potentially catastrophic (1–4). Among hemorrhagic ovarian cysts, functional cysts such as the follicular or corpus luteal type are most common (5–7). The latter, in particular, have hypervascular walls, and this may cause significant bleeding. Although the ultrasound, computed tomography (CT), and magnetic resonance (MR) imaging findings of hemorrhagic ovarian cyst have been extensively described, less attention has been given to the imaging findings of ruptured corpus luteal cyst (5–9).

The purpose of this study is to describe the spectrum of CT findings of ruptured corpus luteal cyst, thereby facilitating the preoperative diagnosis of this potentially catastrophic condition.

## MATERIALS AND METHODS

Through a review of medical records at Seoul National University Hospital, we retrospectively evaluated 251 cases of hemorrhagic ovarian cyst clinically diagnosed during a recent 5-year period. Pertinent gynecologic histories were obtained in all cases, 93 (37%) of which were proven as ruptured corpus luteal cysts. In six of the patients,

aged 19–34 (mean, 27) years, CT was performed; specimens obtained within two days of this permitted pathological correlation with its findings. These patients subsequently undergone laparoscopic laparotomy (n=4) or open oophorectomy (n=2).

For CT, a Somatom plus-4 scanner (Siemens Medical System®, Erlangen, Germany) was used. Both non-enhanced and contrast-enhanced scan were obtained in all patients except one, who underwent only contrast-enhanced scanning. In all cases this was initiated 60 secs after intravenous injection of 120 mL of contrast material containing 300 mg I/mL (Ultravist 370®, Schering, Berlin, Germany) at a rate of 3 mL/sec. The scanning parameters included 7 mm/sec table speed, 1:1 pitch, and 7–8 mm thickness.

Two radiologists (HJC, SHK) retrospectively reviewed the CT images, reaching their conclusions by consensus and focusing on the size and shape of the cyst, the thickness and enhancement pattern of its wall, the attenuation of the cystic contents, and peritoneal fluid. If wall thickness was not uniform, this was measured at its thickest point. The attenuation of cystic content and peritoneal fluid was considered high if higher than that of fluid contained in the gall bladder or urinary bladder.

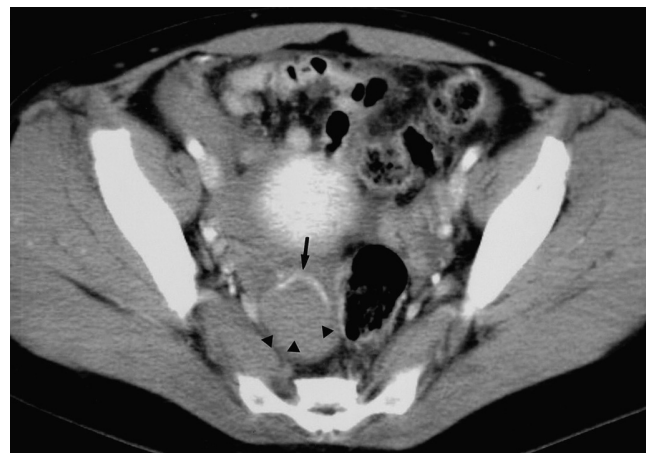
## RESULTS

The mean diameter of the cysts was 2.8 (range, 1.5–4.8) cm; three were oval and three were round, and there was no septation. Mean maximum thickness of the cyst wall was 4.7 (range, 1–10) mm; in all six cases it showed strong enhancement (Figs. 1, 2B, 3B, 4), with interruption or discontinuity in three (50%) (Figs. 1, 2B, 3B). In five of the

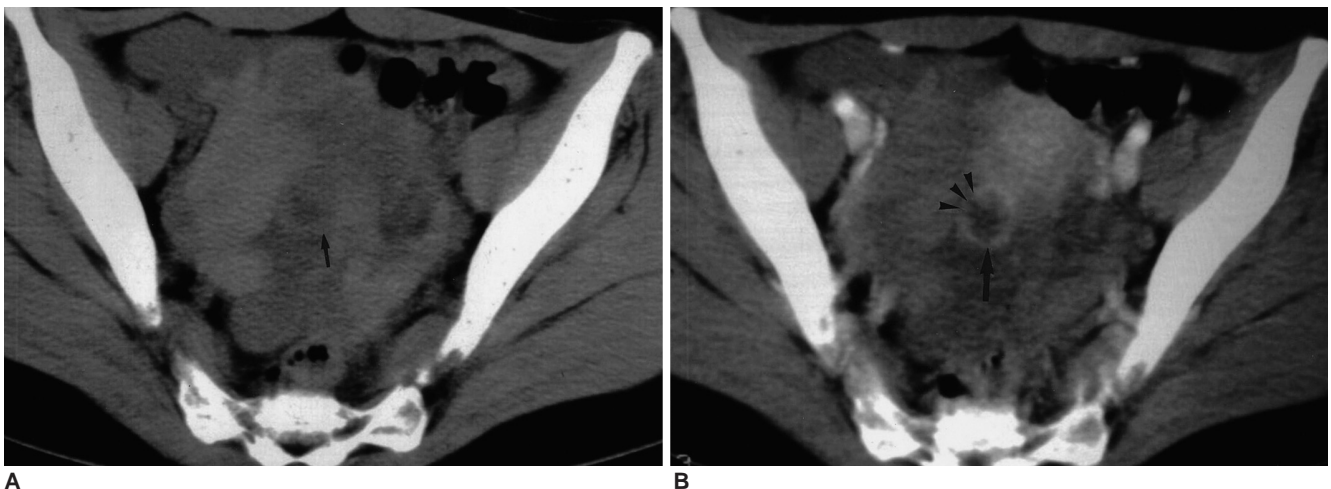
six cases (83%), the cystic content was highly attenuated, representing intracystic hemorrhage (Figs. 1, 2A, 3A, 4). In all cases, high attenuation, due to ascites, was present, especially around the uterus and adnexa, and at surgery this was shown to be due to hemoperitoneum with clot formation (Figs. 2A, 3A, 4).

## DISCUSSION

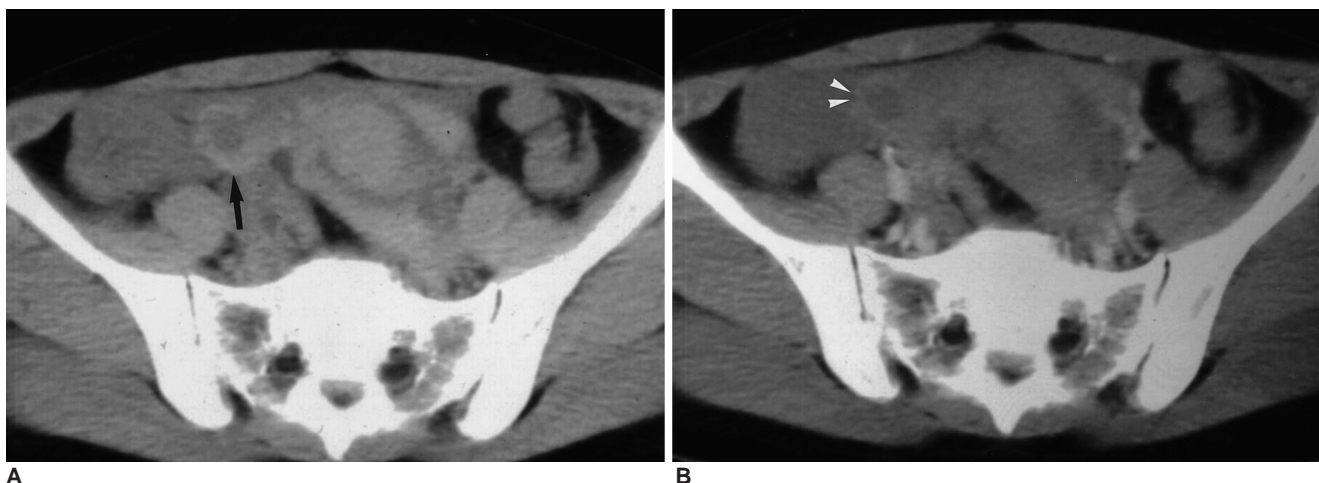The majority of ovarian cysts, whether functional or neoplastic, are usually asymptomatic and discovered fortuitously at pelvic ultrasonography. A hemorrhagic ovarian cyst is a frequent cause of acute pelvic pain in a woman of child-bearing age (7, 10). When a pregnancy test is negative, the



**Fig. 1.** A 32-year-old woman with severe pelvic pain and a negative pregnancy test. Contrast-enhanced CT scan at the level of the pelvis shows a cystic mass in the right adnexa, with wall enhancement (arrow). There is interruption of the enhancing wall, suggesting rupture of cyst (arrowheads). Note the presence of high-attenuated peritoneal fluid and cystic content.



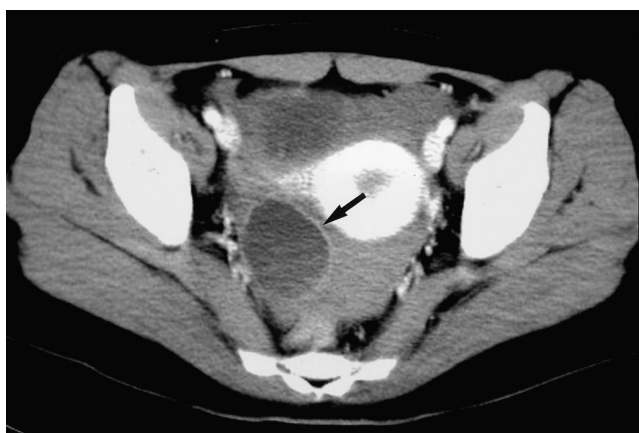**Fig. 2.** A 32-year-old woman with severe pelvic pain and a negative pregnancy test.  
**A.** Non-enhanced CT scan of the pelvis reveals the presence of high-attenuated peritoneal fluid in the pelvic cavity, due to hemoperitoneum. There is a cystic lesion in the right adnexa (arrow).  
**B.** Contrast-enhanced CT shows that the thick wall of the cystic mass (arrow) is well enhanced, interruption is apparent (arrowheads).



**Fig. 3.** A 34-year-old woman with lower abdominal pain and anemia.

**A.** Non-enhanced CT scan of the pelvis shows high-attenuated pelvic fluid, suggesting hemoperitoneum. The right adnexa contains a cystic lesion (arrow).

**B.** Contrast-enhanced CT shows that the wall of the right adnexal lesion is well enhanced. In the cystic wall, suspicious interruptions (arrowheads) are apparent.



**Fig. 4.** A 19-year-old woman with severe pelvic pain and a negative pregnancy test. At contrast-enhanced CT, the wall of the cystic mass (arrow) is well enhanced. Note the presence of high-attenuated fluid in the cul-de sac and dependent portion of the cyst.

differential diagnosis of such pain in a premenopausal woman includes hemorrhage and/or rupture of an ovarian cyst, ovarian torsion, appendicitis, endometriosis, pelvic inflammatory disease, and neoplasm.

The most common underlying etiology of hemorrhagic ovarian cyst is a corpus luteal cyst (5–7), which may result from continuing hemorrhage within a corpus luteum and usually has a thicker wall than a follicular cyst (11). At ultrasonography, hemorrhagic ovarian cysts are seen as complex masses with internal echoes and enhanced through-transmission. The cyst wall may be irregular in contour due to a clot that adheres to it. Occasionally, mildly echogenic interfaces can be seen within a hemorrhagic cyst, most

likely representing a partially solid clot (6, 12). Previously reported CT findings of ruptured ovarian cysts, observed at delayed imaging, include the presence in the pelvis of more highly attenuated peritoneal fluid (suggesting hemoperitoneum with hematoma), an attenuated portion and fluid-fluid level within an ovarian cystic mass, and a small collection of contrast material within the peritoneal cavity (8, 13).

Although the CT features of hemorrhagic ovarian cyst have been reported (8, 13, 14), those of ruptured corpus luteal cyst have not been a focus of attention. In our six cases, CT revealed wall enhancement, suggesting increased vascularity of that area. Three of the six masses showed interruption or discontinuity of the enhancing wall, a finding that suggested cystic rupture and can provide direct evidence of rupture of an ovarian cyst. The cyst wall was relatively thick in our series, in contrast to that of an unruptured corpus luteal cyst, in which it is barely perceptible (15). In all six masses, high attenuation within the cyst was observed, indicating hemorrhage, and highly attenuated fluid was present in the pelvic cavity, suggesting hemoperitoneum. Because of recent bleeding, highly attenuated fluid surrounded the uterus and adnexa, but delayed imaging revealed no pooling of contrast material.

Although this study involved only six cases, the findings suggest that in a woman in whom CT reveals an ovarian cyst with a thick enhancing rim and the presence of highly attenuated peritoneal fluid, a ruptured corpus luteal cyst should be suspected. Other findings that suggest this diagnosis are focal interruption of the cyst wall and the presence of highly attenuated peritoneal fluid around the ad-

nexa.

## Acknowledgements

This study was supported in part by the BK21 Project for Medicine, Dentistry and Pharmacy.

## References

1. Raziel A, Ron-El R, Pansky M, Arieli S, Bukovsky I, Caspi E. Current management of ruptured corpus luteum. *Eur J Obstet Gynecol Reprod Biol* 1993;50:77-81
2. Freistadt H. Ruptured corpus luteum with hemoperitoneum. *Am J Obstet Gynecol* 1985;151:420-421
3. Fraley DS, Johnston JR, Bruns FJ, Adler S, Segel DP. Rupture of ovarian cyst: massive hemoperitoneum in continuous ambulatory peritoneal dialysis patients: diagnosis and treatment. *Am J Kidney Dis* 1988;12:69-71
4. Sarihan H, Unal M, Ozoran Y. Massive haemoperitoneum due to spontaneous rupture of ovarian cyst in children. A report of two cases. *S Afr J Sur* 1996;34:44-46
5. Nyberg DA, Porter BA, Olds MO, et al. MR imaging of hemorrhagic adnexal masses. *J Comput Assist Tomogr* 1987; 11:664-669
6. Baltarowich OH, Kurtz AB, Pasto ME, Rifkin MD, Needleman L, Goldberg BB. The spectrum of sonographic findings in hemorrhagic ovarian cysts. *AJR Am J Roentgenol* 1987;148:901-905
7. Bass IS, Haller JO, Friedman AP, Twersky J, Balsam D, Gottesman R. The sonographic appearance of the hemorrhagic ovarian cyst in adolescents. *J Ultrasound Med* 1984;3:509-513
8. Hertzberg BS, Kliwer MA, Paulson EK. Ovarian cyst rupture causing hemoperitoneum: imaging features and the potential for misdiagnosis. *Abdom Imaging* 1999;24:304-308
9. Wilbur AC, Goldstein LD, Prywitch BA. Hemorrhagic ovarian cysts in patients on anticoagulation therapy: CT findings. *J Comput Assist Tomogr* 1993;17:623-625
10. Droegemueller W. *Benign gynecologic lesions: Comprehensive gynecology*. St. Louis: Mosby Year Book, 1992:521-526
11. Fleischer AC, Javitt MC, Jefferey RB. Jr., Jones HW, III. *Clinical gynecologic imaging*. Philadelphia: Lippincott-Raven Publishers, 1997:51-52
12. Reynolds T, Hill MC, Glassman LM. Sonography of hemorrhagic ovarian cysts. *J Clin Ultrasound* 1986;14:449-453
13. Occhipinti KA, Frankel SD, Hricak H. The ovary: computed tomography and magnetic resonance imaging. *Radiol Clin North Am* 1993;31:1115-1132
14. Mitchell DG, Mintz MC, Spritzer CE, et al. Adnexal masses: MR imaging observations at 1.5 T, with US and CT correlation. *Radiology* 1987;162:319-324
15. Fleischer AC, Javitt MC, Jefferey RB. Jr., Jones HW, III. *Clinical gynecologic imaging*. Philadelphia: Lippincott-Raven Publishers, 1997:104