

Herpes Zoster Ophthalmicus Presenting as Acute Orbital Myositis Preceding a Skin Rash: A Case Report¹

안부대상포진에서 피부발진을 선행하는 안와근염: 증례 보고¹

Ha Yeun Oh, MD¹, Seong Whi Cho, MD¹, Sung Hun Kim, MD²

Departments of ¹Radiology, ²Neurology, Kangwon National University Hospital, Chuncheon, Korea

Herpes zoster ophthalmicus, in which orbital symptoms and signs appear before the onset of a skin rash, is very rare. We experienced such a case and therefore report on it via magnetic resonance imaging. A 48-year-old man with pain and swelling of left eye and headache presented 2 days before onset of a zoster skin rash. On orbital MRI, edematous thickening of the left lateral rectus muscle with high signal intensity was revealed. After contrast injection, the lateral rectus muscle demonstrated heterogenous enhancement. Also, diffuse contrast enhancement was noted at left preseptal space, lacrimal gland and periorbital soft tissue. The man was treated with antiviral agents and prednisolone. Two weeks later, he recovered from the skin manifestations and most of the orbital manifestations except for the diplopia and restricted lateral movement.

Index terms

Orbital Myositis
Herpes Zoster Ophthalmicus
Magnetic Resonance Imaging

Received December 12, 2011;

Accepted January 10, 2012

Corresponding author: Seong Whi Cho, MD
Department of Radiology, Kangwon National University
Hospital, 156 Baengnyeong-ro, Chuncheon 200-722,
Korea.
Tel. 82-33-258-2329 Fax. 82-33-258-2221
E-mail: chosw@kangwon.ac.kr

Copyrights © 2012 The Korean Society of Radiology

INTRODUCTION

Herpes zoster ophthalmicus represents approximately 10 to 25 percent of all cases of herpes zoster (1). Ocular manifestations of zoster ophthalmicus include keratitis, conjunctivitis, external ocular muscle palsies, acute retinal necrosis, optic neuritis, orbital pseudotumor, and central retinal artery occlusion (2).

In most cases, it is not difficult to make a diagnosis because its onset varies from few days to weeks after the eruption of a vesicular rash (3).

However, we experienced a rare case of orbital myositis, which developed before the appearance of a zoster rash (up to date, 3 cases have been presented in Pubmed) and hereby report on this case via magnetic resonance imaging.

CASE REPORT

A 48-year-old man presented at the emergency department with a history of pain and swelling of left eye and a headache that persisted for 3 days. Upon ophthalmic examination, pupil

reaction was normal but swelling of the eye lid and chemosis were noted. Conjunctivitis was suspected and eyedrops were given to the patient.

After 2 days, he revisited with a febrile sensation and different stages of skin rashes on the whole body. Despite the prescribed medication, the left eyelid swelling worsened. Exophthalmus, diplopia and restricted lateral movement of the left eye newly appeared.

Serologic examination revealed elevated Varicella-zoster-immunoglobulin-G and excluded the possibility of thyroid disease or auto-immune diseases. A cerebrospinal fluid analysis was performed to exclude central nervous system infection. Additionally, an elevated white blood cells and protein level were noted.

Orbital magnetic resonance imaging (MRI) was performed 7 days after the appearance of the orbital symptom and revealed edematous thickening of the left lateral rectus muscle with high signal intensity (Fig. 1A-C). After gadolinium injection, the lateral rectus muscle demonstrated heterogenous enhancement. Also, diffuse contrast enhancement of preseptal space of left orbit, left lacrimal gland, and left lateral rectus muscle were noted

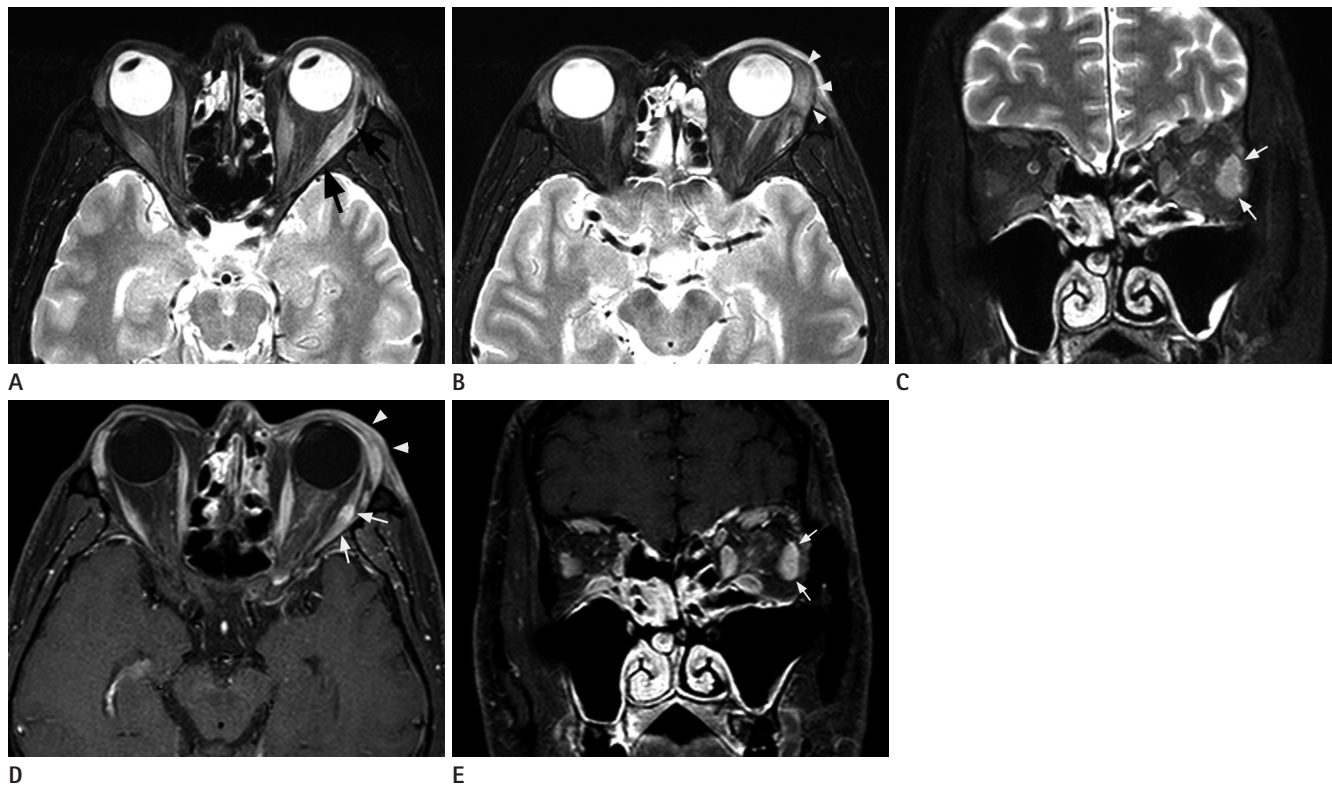


Fig. 1. A 48-year-old man with herpes zoster ophthalmicus presenting as orbital myositis preceding a skin rash. **A-C.** Axial (**A, B**) and fat suppressed coronal (**C**) T2-weighted MRI images of the orbits show mild swelling and high signal intensity of the left lateral rectus muscle (arrows) and enlargement of the lacrimal gland (arrowheads). **D, E.** Axial (**D**) and coronal (**E**) gadolinium-enhanced T1-weighted MRI show heterogenous enhancement of the left lateral rectus muscle (arrows). Diffuse enhancement of the preseptal space of the left orbit and periorbital tissue are also noted (arrowheads).

with exophthalmus. Additionally, there was mild swelling and diffuse enhancement of left periorbital soft tissue (Fig. 1D, E). On brain MRI, no significant abnormal finding was noted.

The patient was treated by intravenous administration of 750 mg acyclovir, and 65 mg methylprednisone for 7 days. On the 8th day, the acyclovir treatment was changed to 1000 mg valaciclovir for 7 days.

Within 2 weeks, the cutaneous manifestations were regressive with crust formation. The patient fully recovered from eyelid swelling, chemosis and exophthalmus, but still complained of restricted lateral movement of the left eye and diplopia. Oral prednisone treatment was administered for diplopia and restricted movement, the sine infectivity of herpes zoster subsided, and an out-patient department follow-up was recommended.

DISCUSSION

Herpes zoster ophthalmicus occurs when reactivation of latent herpes zoster involves the ophthalmic division of the tri-

geminal nerve (4). In most cases, onset of ophthalmic symptoms appear after the appearance of skin lesions. Vardy and Rose documented that orbital inflammatory diseases occurred 5 to 14 days following the skin eruption (3).

However, there are three reports in which orbital manifestations precede skin rashes (5-7). All of them have been confirmed radiologically (i.e., by computed tomography or magnetic resonance imaging). From what we have gathered, the occurrence of orbital manifestations preceding skin rashes was first published in 1994 by Volpe and Shore. They have shown enlargement of extraocular muscles with tendon sparing on CT scan, which appeared one day before the appearance of the skin rashes (5). The other two cases demonstrated MRI findings which mimic inflammatory pseudotumor. They showed fusiform enlargement of the extraocular muscles with tendon sparing and after the contrast injection, diffuse enhancement of the extraocular muscles, orbital fat, and periorbital soft tissues (6, 7). Our patient shared similar MRI findings to their patients, except for the tendinous portion of the lateral rectus muscle

showed mild enhancement.

To date, orbital myositis associated with herpes zoster ophthalmicus has only been confirmed radiologically and no histopathologic studies were performed. In most of the presented cases, extraocular muscles were involved with tendon sparing, and rectus muscles were the common site of involvement. However, there was a report, in which superior and inferior oblique muscle involvement was revealed on an orbital CT scan (8).

Based on the reported cases, herpes zoster induced acute myositis is characterized by the acute, painful onset of extraocular muscle enlargement and swelling of the periorbital soft tissue.

Symptoms of orbital myositis may mimic other orbital diseases such as orbital cellulitis, local infection, orbital neoplasm, optic neuritis and extraorbital diseases such as thyroid associated orbitopathy, cranial nerve palsy, sinus thrombosis, myasthenia gravis and auto-immune diseases (9).

One of the most noticeable extraocular manifestation is Hutchinson's sign (involvement of the tip of the nose). Classically, positive Hutchinson's sign was considered as a clinical predictor of ocular involvement because when it appears, twice the incidence of ocular involvement occurs (4). Our case is unusual in that the skin rashes appeared on the whole body, except for the face.

In our case, the patient recovered from the ocular manifestations except for restricted abduction and diplopia. It was reported that the duration of diplopia varies from 2 months to 23 months and about 87.5% of diplopia cases were recovered within one year (10).

In conclusion, physicians should be aware of the possibility of herpes zoster in patients with orbital myositis since orbital symptoms and signs can appear before the skin lesions and it

may help the early diagnosis.

REFERENCES

1. Womack LW, Liesegang TJ. Complications of herpes zoster ophthalmicus. *Arch Ophthalmol* 1983;101:42-45
2. Marsh RJ, Cooper M. Ophthalmic herpes zoster. *Eye (Lond)* 1993;7:350-370
3. Vardy SJ, Rose GE. Orbital disease in herpes zoster ophthalmicus. *Eye (Lond)* 1994;8:577-579
4. Shaikh S, Ta CN. Evaluation and management of herpes zoster ophthalmicus. *Am Fam Physician* 2002;66:1723-1730
5. Volpe NJ, Shore JW. Orbital myositis associated with herpes zoster. *Arch Ophthalmol* 1991;109:471-472
6. Kawasaki A, Borruat FX. An unusual presentation of herpes zoster ophthalmicus: orbital myositis preceding vesicular eruption. *Am J Ophthalmol* 2003;136:574-575
7. Tseng YH. Acute orbital myositis heralding herpes zoster ophthalmicus: report of a case. *Acta Neurol Taiwan* 2008; 17:47-49
8. Badilla J, Dolman PJ. Orbital myositis involving the oblique muscles associated with herpes zoster ophthalmicus. *Ophthalmol Plast Reconstr Surg* 2007;23:411-413
9. Yuen SJ, Rubin PA. Idiopathic orbital inflammation: distribution, clinical features, and treatment outcome. *Arch Ophthalmol* 2003;121:491-499
10. Shin HM, Lew H, Yun YS. A case of complete ophthalmoplegia in herpes zoster ophthalmicus. *Korean J Ophthalmol* 2005;19:302-304

안부대상포진에서 피부발진을 선행하는 안와근염: 증례 보고¹

오하연¹ · 조성휘¹ · 김성현²

안부대상포진(herpes zoster ophthalmicus) 환자에서 피부 발진 이전에 눈의 증상 또는 징후가 먼저 나타나는 경우는 매우 드물다. 저자들은 이런 증례를 경험하였기에 자기공명영상 소견과 함께 이에 대해 보고하고자 한다. 48세 남자가 대상포진발진이 나타나기 2일 전부터 발생한 왼쪽 눈의 통증과 부종을 주소로 내원하였다. 안와 자기공명영상에서 좌측 가쪽곧은근이 부종성 팽창과 고신호 강도를 보였다. 조영증강 후 가쪽곧은근은 비균질 조영증강 소견을 보였으며, 좌측 전중격 공간, 눈물샘 그리고 안와주위 연조직에 광범위 조영증강 소견이 관찰됐다. 환자는 항바이러스제제와 프레드니솔론으로 치료 받았으며, 약 2주 후 복시와 외전운동제한을 제외한 안구 증상과 피부병변에서 회복되었다.

강원대학교병원 ¹영상의학과, ²신경과