

Rhabdomyoma of Inferior Rectus Muscle Manifesting as Vertical Eye Movement Limitation

Dear Editor,

Rhabdomyoma is a benign tumor of the striated muscle. We report a case of rhabdomyoma in the inferior rectus muscle of a young girl who presented with unilateral vertical eye movement limitation without exophthalmos.

A 32-month-old female patient visited our clinic with limitation of elevation and depression of her right eye from 20 months of age. The patient had no abnormal birth or past medical history. On physical examination, 20 prism diopters (PD) of exotropia and 30 PD of right hypertropia in primary gaze were noted, and ocular movements of the right eye were decreased on elevation (-2) and depression (-2) (Fig. 1A). Exophthalmos was not observed, and slit lamp examination and fundus examination were normal. Cycloplegic refractive error was +1.00 D Sph -4.50 D Cyl \times 180° in the right eye and emmetropia in the left eye, and best-corrected visual acuity was 4 / 20 in the right eye and 10 / 20 in the left eye. Therefore, glasses and left occlusion therapy were prescribed for astigmatism and amblyopia of the right eye. Orbital magnetic resonance imaging revealed a well-circumscribed mass in the right retrobulbar intraconal area that involved the inferior rectus muscle and abutted the medial rectus muscle. Additionally, the mass measured 1.2 \times 1.4 \times 0.9 cm and was isointense with the muscle in the T1-weighted image and hypointense in the T2-weighted image (Fig. 1B). Because of the patient's age, a capillary hemangioma was suspected, and two intralesional steroid injections were performed with the patient under general anesthesia. After the steroid injections, there was no change in the mass on orbital computed tomography, so the possibility of hemangioma was low. Since the size of the mass did not increase and there was no evidence of malignancy, we decided to observe the mass and treat the amblyopia.

Over the course of 5 years, the amblyopia improved, and the corrected visual acuity improved to 20 / 20 in both eyes,

although the exotropia and right hypertropia persisted. There was no change in the mass on radiologic studies. Additional eyeball sonography with color Doppler showed a hypoechoic mass without increased vascularity in the right inferior intraconal space (Fig. 1C).

Under suspicion of mass other than hemangioma, endoscopic transnasal mass excision was performed with the patient under general anesthesia. The mass was approached through the medial wall of the right orbit. Biopsy of the mass revealed skeletal and fibroskeletal tissue without mitoses, nuclear hyperchromasia, nuclear pleomorphism, and necrosis, leading to diagnosis of rhabdomyoma (Fig. 1D). After surgery, 12 PD of right hypertropia was observed, and limitation of elevation and depression persisted.

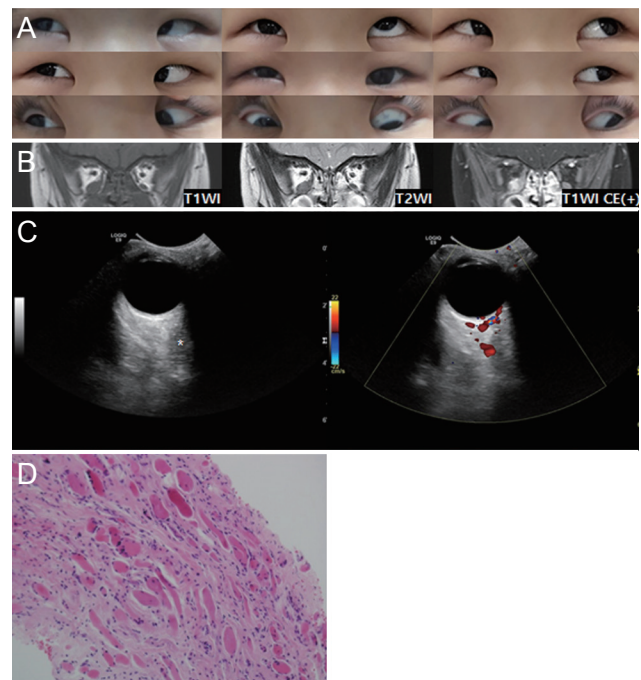


Fig. 1. Clinical, radiological, and pathological images of the patient. (A) Nine cardinal photographs of the patient show limitation in elevation (-2) and depression (-2) in the right eye. (B) Orbital magnetic resonance imaging revealed an enhancing mass in the right retrobulbar area involving the inferior rectus muscle and abutting the medial rectus muscle. The mass measured 1.2 \times 1.4 \times 0.9 cm and was isointense with the muscle in the T1-weighted image and hypointense in the T2-weighted image. (C) Eyeball sonography revealed a hypoechoic mass (asterisk) in the right inferior intraconal space without definite vascularity on the color Doppler image. (D) Biopsy of the mass revealed fibroskeletal tissue without mitoses, nuclear hyperchromasia, nuclear pleomorphism, or necrosis (H&E, \times 100).

Extracardiac rhabdomyomas are rare, and most of them occur in the head and neck. Four cases of rhabdomyoma in the extraocular muscles have been reported; one in the superior rectus, one in the inferior rectus, and two in the medial rectus muscles [1-4]. Of the previously reported cases, two appeared as an intraconal mass (as in the present case), and all presented with unilateral exophthalmos. Our case is unique in that the patient had no exophthalmos, but there was vertical eye movement limitation and hypertropia.

Radiologically, rhabdomyomas are well circumscribed, and the attenuation or signal intensities are similar to those of normal muscles. The tumor has a homogenous texture and demonstrates enhancement without necrosis or hemorrhage. The adjacent bony structures are remodeled but not destroyed by the pressure effect [5]. Pathologically, the tumor is composed of compactly arranged striated muscle cells with abundant acidophilic cytoplasm and eccentrically-placed, large, vesicular nuclei. Mitoses, nuclear hyperchromasia, nuclear pleomorphism, and necrosis are absent in a rhabdomyoma, findings that can be used to distinguish it from rhabdomyosarcoma [4].

Orbital masses with a retrobulbar location in children encompass a wide variety of disease entities, including vascular tumors (hemangioma and lymphangioma), rhabdomyosarcomas, inflammatory pseudotumors, neurofibromas, and cysts. Although rare, rhabdomyoma should be considered as a possible diagnosis in the presence of a well-circumscribed mass that is isointense with muscle and shows homogenous enhancement without adjacent infiltration.

Ji Min Kwon

Department of Ophthalmology, Haeundae Paik Hospital, Inje University College of Medicine, Busan, Korea

Jae Hwan Kwon

Department of Otorhinolaryngology, Kosin University Gospel Hospital, Kosin University College of Medicine, Busan, Korea

Soo Jung Lee

Department of Ophthalmology, Haeundae Paik Hospital, Inje University College of Medicine, Busan, Korea
E-mail: kris9352@paik.ac.kr

Conflict of Interest

No potential conflict of interest relevant to this article was reported.

References

1. Forrest AW. Intraorbital tumors. *Arch Ophthalmol* 1949;41:198-232.
2. Nath K, Nema HV, Hameed S, Shukla BR. Orbital rhabdomyoma. *Am J Ophthalmol* 1965;59:1130-4.
3. Krespi YP, Som PM, Shugar JM. Rhabdomyomas: a rare cause of unilateral proptosis. *Mt Sinai J Med* 1979;46:392-5.
4. Knowles DM 2nd, Jakobiec FA. Rhabdomyoma of the orbit. *Am J Ophthalmol* 1975;80:1011-8.
5. Myung J, Kim IO, Chun JE, et al. Rhabdomyoma of the orbit: a case report. *Pediatr Radiol* 2002;32:589-92.