

A Case of Complete Ophthalmoplegia in Herpes Zoster Ophthalmicus

Hyun-Min Shin, MD, Helen Lew, MD, Young-Su Yun, MD

Department of Ophthalmology, Pochon CHA University College of Medicine, Pundang CHA Hospital, Sungnam, Korea

Purpose: To report a case with complete ophthalmoplegia after herpes zoster ophthalmicus.

Methods: A 70-year-old male patient visited a clinic because of vesicular eruptions over the left side of his face with severe pain. Drooping and severe swelling of the left eyelid were present, along with keratitis and uveitis. While the lid swelling and uveitis were improving, external ophthalmoplegia and exophthalmos were discovered. Intramuscular injections of dexamethasone 5 mg were given for 10 days, followed by oral administration of prednisolone at a dosage of 15 mg for two weeks and 10 mg for two weeks.

Results: The patient was fully recovered from the complete ophthalmoplegia and exophthalmos six months after the onset of the cutaneous lesion.

Conclusions: Complete ophthalmoplegia is a rare ophthalmic complication of herpes zoster infection. Therefore, an evaluation of extraocular muscle and lid function should be performed during the examination of herpes zoster patients in order to screen for ophthalmoplegia. *Korean Journal of Ophthalmology* 19(4): 302-304, 2005

Key Words: Complete ophthalmoplegia, exophthalmos, herpes zoster ophthalmicus

Herpes zoster occurs by the reactivation of latent virus lying in the ganglion after a prior attack of chicken pox.¹ Ten to fifteen percent of herpes zoster occurrences involve the ophthalmic branch of the trigeminal nerve, and 50% of these cases involve the ocular component.²⁻⁵ Complications of herpes zoster ophthalmicus include keratitis, uveitis, secondary glaucoma, cataracts, and the involvement of cranial nerves.^{1,3,4}

The third, fourth, and sixth nerves tend to be involved, and the third nerve is the most common site among them.^{1,4,6} Ophthalmoplegia associated with herpes zoster ophthalmicus mostly occurs in patients over the age of 50 years.⁷ The prognosis of ophthalmoplegia is commonly good.⁷

However, complete ophthalmoplegia is reported to be a very rare complication of herpes zoster ophthalmicus.^{7,8} We examined a patient exhibiting complete ophthalmoplegia associated with herpes zoster, and we report on this case with a review of the literature.

Case Report

A 70-year-old man presented with sudden vesicular

eruptions and pain over the left side of his face (Fig. 1). At first physical examination, visual acuity of the right eye was 20/20; visual acuity of the left eye was 20/100, due to hazy and edematous change of cornea, folding of Descemet's membrane, and corneal erosion with moderate inflammatory reaction at the anterior chamber. Pupil sizes were 5mm on the right and 7 mm on the left, and pupil reflexes were prompt on the right and sluggish on the left. For uveitis treatment, levofloxacin, prednisolone acetate, and atropine eye drops were used. Other examinations were impossible because of severe lid swelling and intractable pain.

Two months after conservative treatment for cutaneous lesions, the keratitis and uveitis related to the herpes zoster ophthalmicus were improved. At that time, lid swelling was slightly recovered, but the drooping of the upper eyelid continued. Proptosis and complete ophthalmoplegia were found in the left eye. The proptosis of the left eye was about 3mm, and moderate to severe limitations of ocular movement in all directions were noted (Fig. 2). A brain MRI was taken to rule out a brain lesion.

Lesions that might affect ocular movement were not discovered on the brain MRI. We proceeded with conventional treatment for herpes zoster ophthalmicus: intravenous infusions of acyclovir 750 mg for three days, intramuscular injections of dexamethasone 5 mg for 10 days, and oral administration of prednisolone at 15 mg for two weeks and 10 mg for two weeks.

Ophthalmoplegia and lid drooping continued after the

Received: April 26, 2005 Accepted: September 29, 2005

Reprint requests to Helen Lew, MD. Department of Ophthalmology, College of Medicine Pochon CHA University, #351 Yatap-dong, Bundang-gu, Sungnam, Gyeonggi-do 463-712, Korea. Tel: 82-31-780-5330, Fax: 82-31-780-5333, E-mail: eye@cha.ac.kr

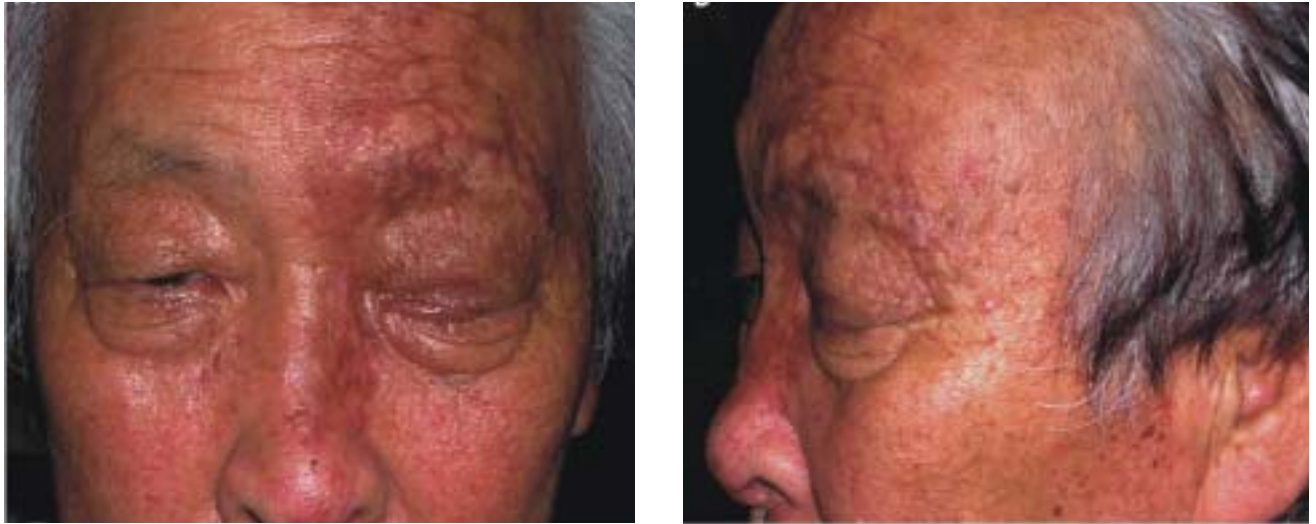

Fig. 1. (A) Vesicular eruption over the left side of face. (B) Severe proptosis of left eye.

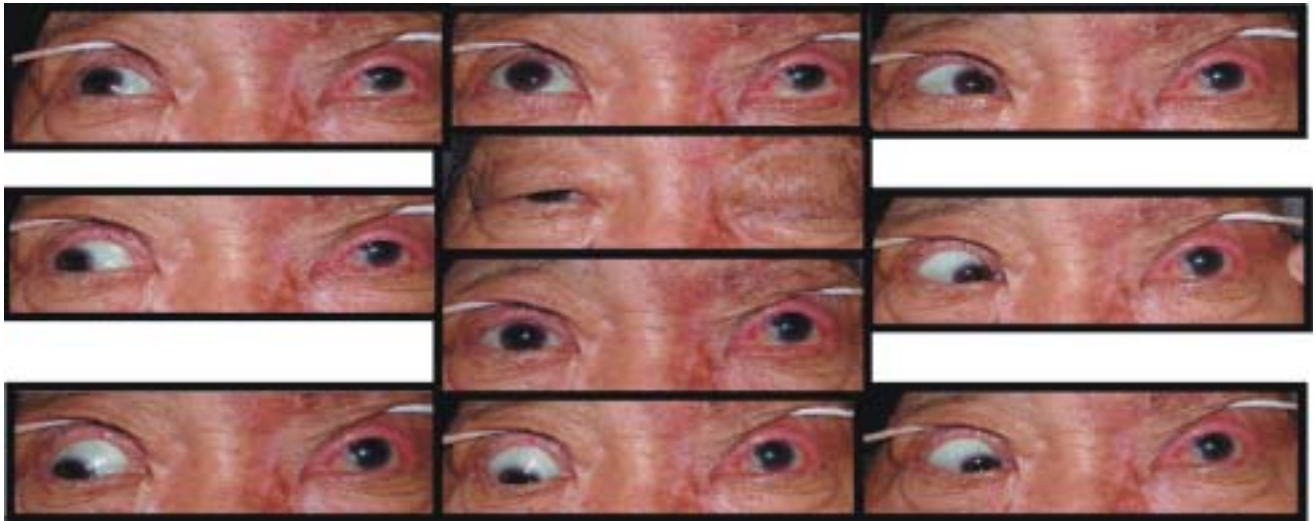

Fig. 2. Nine cardinal directions of ocular movement at an early stage of disease. Left lid drooping and limitation of ocular movement in all nine directions of gaze were noted.

improvement of cutaneous lesions, keratitis, and uveitis. At three months after treatment, the ophthalmoplegia and lid drooping were starting to recover.

Six months after the onset of herpes zoster, post-herpetic neuralgia was present, but the patient had recovered fully from other complications including lid drooping and exophthalmos, and also recovered from the ophthalmoplegia, with the exception of adduction. Both pupils were 5 mm in size, and pupil reflexes were prompt. The exophthalmometric findings were Rt-15.0 mm and Lt-15.5 mm, with a baseline of 97 mm (Fig. 3).

Discussion

The nerves most commonly affected by herpes zoster are the sensory nerves of the thoracic dermatomes, followed by the cranial nerves.^{1,2,9} Herpes zoster ophthalmicus was diagnosed in 10-15% of herpes zoster patients.

The ocular complications of herpes zoster ophthalmicus usually occur in 50% of all cases.^{1,9} The ophthalmoplegia occurs in 11-29% of patients with herpes zoster ophthalmicus. Third, fourth, and sixth nerve palsies occur more frequently, and the third nerve appears to be the most commonly affected.^{1,5,9} Any kinds of ophthalmoplegia (third, fourth, or sixth nerve palsies) may be accompanied by proptosis. If all three nerves are involved simultaneously, this may cause complete ophthalmoplegia.

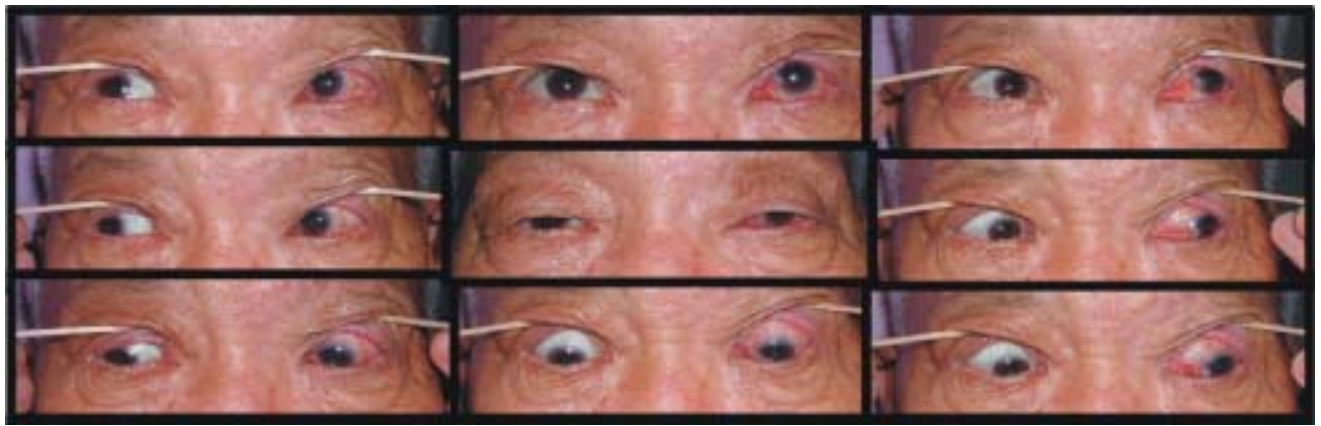


Fig. 3. Nine cardinal directions of ocular movement at six months after disease onset. Lid drooping and limitation of ocular movement were recovered to normal, except for adduction.

The rate of extraocular muscle palsy in herpes zoster ophthalmicus was reported to be from 5% to 14% in a study investigating the general complications of the condition. However, a study that investigated the ocular motor functions reported that the rate is as high as 31%.¹

The pathogenesis of cranial nerve palsy in herpes zoster can be explained as follows. First, the direct cytopathic effect of virus is on the surrounding neural tissue.¹⁰ Second, an allergic response to the virus can happen in the central nervous system.¹¹ Third, occlusive vasculitis may be induced by the virus.¹ Fourth, another latent neuropathic virus can be activated by the varicella/zoster virus.

The therapeutic goal in the treatment of herpes zoster is the administration of an antiviral agent that crosses the blood-brain barrier. It is effective, non-toxic, and systemic. If the antiviral agent were given during the early course of the disease, it would prevent the direct cytotoxic effect of virus, the allergic response of the surrounding neural tissue, and the initiation of a secondary vasculitis by destroying the virus at early stage. The use of a systemic steroid may be effective to prevent occlusive vasculitis.¹²

The possible causes of complete ophthalmoplegia in this case can be explained as follows. First, since general condition can decline with age, the cytopathic effect could be more severe than in a younger patient. Second, the late use of steroids may have resulted in advanced occlusive vasculitis.

It was reported that duration of diplopia associated with ocular motor palsy was from 2 months to 23 months. However, 87.5% of diplopia cases were recovered to normal within one year. This patient showed a recovery after a similar duration.

It is usually difficult to evaluate the exact function of

extraocular muscles, due to severe lid swelling and pain. However, it is obligatory that physicians definitely confirm ocular motor involvement by evaluation of extraocular muscle and lid function to effectively manage and treat ocular motor palsy.

References

1. Marsh RJ, Dulle B, Kelly V. External ocular motor palsies in ophthalmic zoster: a review. *Br J Ophthalmol* 1977;61:677-82.
2. Edgerton AE. Herpes Zoster Ophthalmicus; report of cases and review of literature. *Arch Ophthalmol* 1945;34:40-62.
3. Womack LW, Liesegang TJ. Complication of herpes zoster ophthalmicus. *Arch ophthalmol* 1983;101:42-5.
4. Hahn ES, Jung YC, Chang K. A case of herpes zoster ophthalmicus complicated by abducens palsy. *J Korean Ophthalmol Soc* 1989;30:447-53.
5. Lee HR, Cho BC. A clinical study of herpes zoster ophthalmicus. *J Korean Ophthalmol Soc* 1988;29:387-91.
6. Goldsmith MO. Herpes zoster ophthalmicus with VIth nerve palsy. *Can J Ophahalmol* 1968;3:279-83.
7. Chang-Godinich A, Lee AG, Brazis PW, et al. Complete Ophthalmoplegia After Zoster Ophthalmicus. *J Neuro-ophthalmol* 1997;17:262-5.
8. Pandey PK. Extraocular Muscle and Facial Paresis in Herpes Zoster Ophthalmicus. *J Pediatr Ophthalmol Strabismus* 2001;38:363-6.
9. Archambault P, Wise JS, Rosen J. Herpes Zoster Ophthalmoplegia, Report of Six Cases. *J Clin Neuroophthalmol* 1988;8:185-91.
10. Copes S, Jones AT. Hemiplegia complicating ophthalmic zoster. *Lancet* 1954;2:898-9.
11. Appelbaum E, Kreps SI, Sunshine A. A zoster encephalomyelitis. *Am J Med* 1914-5;7:513-4.
12. Marsh RJ. Current management of ophthalmic herpes zoster. *Tran Ophthalmol Soc U K* 1976;96:334-7.