

## A Case of *Enterococcus Faecalis* Endophthalmitis with Corneal Ulcer

Sun Min Lee, MD, Jeong Hee Lee, MD

Department of Ophthalmology, Mokdong Hospital, Ewha Womans University  
College of Medicine, Seoul, Korea

Although there have been a few reported cases of Enterococcal endophthalmitis, this is an unusual case of endophthalmitis complicated with corneal ulcer caused by *Enterococcus faecalis*. A 67-year-old male patient with diabetes mellitus underwent secondary intraocular lens implantation. Post-operative recovery was uneventful until a wound rupture was noted 3 weeks after the operation. On day 12 after the repair of the wound, endophthalmitis accompanied by wound necrosis and a full-thickness corneal ulcer was detected. His vision was light perception, and *Enterococcus faecalis* was identified by culture in samples of conjunctival sac, anterior chamber and vitreous humor. After 3 rounds of intravitreal antibiotics injection, the vitreous opacity disappeared on ultrasonographic finding but corneal opacity and corneal neovascularization still remained.

**Key words:** corneal ulcer, endophthalmitis, *Enterococcus faecalis*

### INTRODUCTION

Enterococci are normal inhabitants of the intestinal, and urinary tracts and the anterior urethrae of humans. Although enterococci have been considered to have relatively low-virulence, they can cause serious infections such as endocarditis, sepsis and vision-threatening endophthalmitis due to increasing antimicrobial resistance.<sup>1</sup> *Enterococcus faecalis* is an uncommon cause of postoperative endophthalmitis and visual outcomes in *Enterococcus faecalis* endophthalmitis are reported to be generally poor.

Although a few cases of enterococcal endophthalmitis of exogenous and endogenous origin have

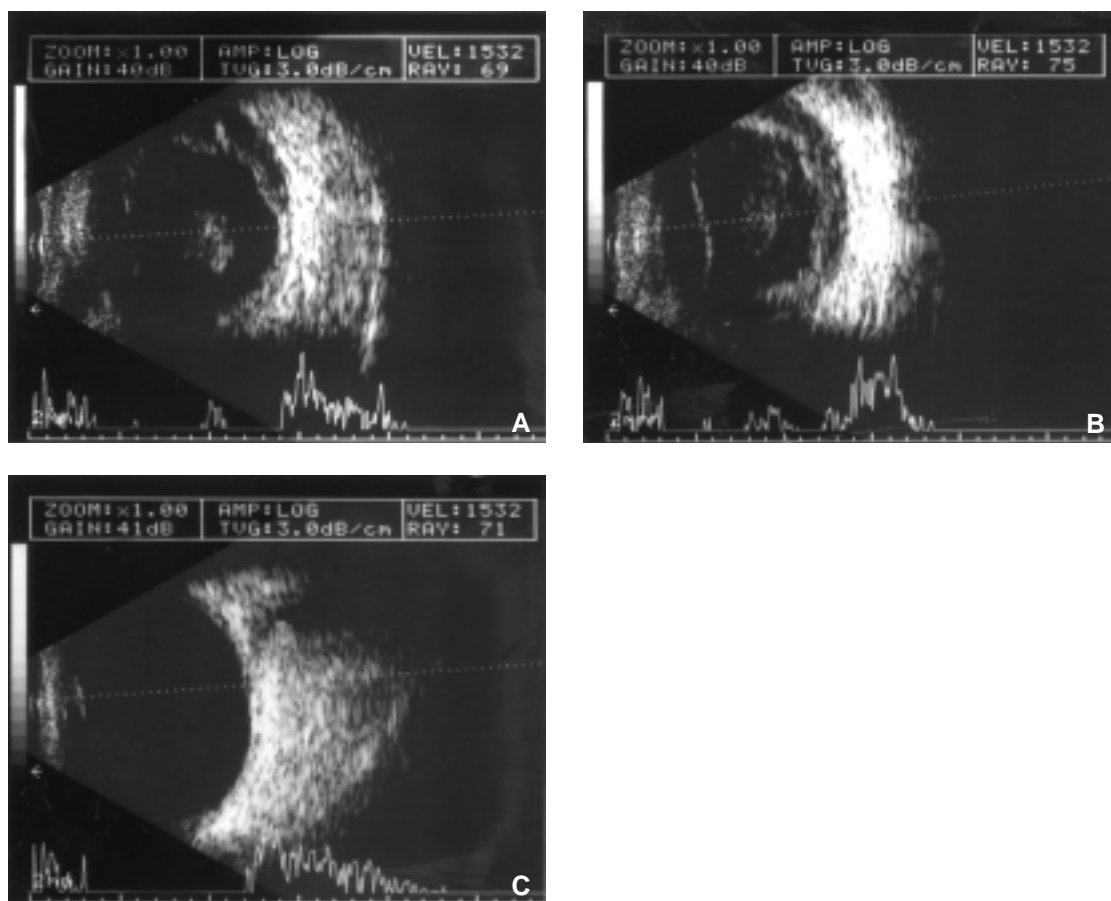
been reported,<sup>2-6</sup> there have been no published data concerning endophthalmitis complicated with corneal ulcer caused by *Enterococcus faecalis*. We present a case of postoperative endophthalmitis accompanied with corneal ulcer caused by *Enterococcus faecalis*.

### CASE REPORT

A 67-year-old male patient with diabetes mellitus had undergone cataract extraction of his right eye 15 years previously and had been aphakic. He had undergone grid laser photocoagulation to his right eye due to diabetic macular edema two years previously. Ophthalmoscopic exam revealed mild non-proliferative diabetic retinopathy of both eyes. He underwent secondary intraocular lens implantation of his right eye. Under the peribulbar anesthesia, irrigation and aspiration of the remnant cortex was performed through limbal corneal incision. A foldable PMMA intraocular lens was fixated into the

Reprint requests to Jeong Hee Lee, MD, Department of Ophthalmology, Ewha Womans University, College of Medicine, Mokdong Hospital, # 911-1 Mok-dong, Yangcheon-ku, Seoul 158-710, Korea.

This paper was presented as a poster at the Korean Ophthalmological Society Annual Meeting, 2003, Busan, Korea.

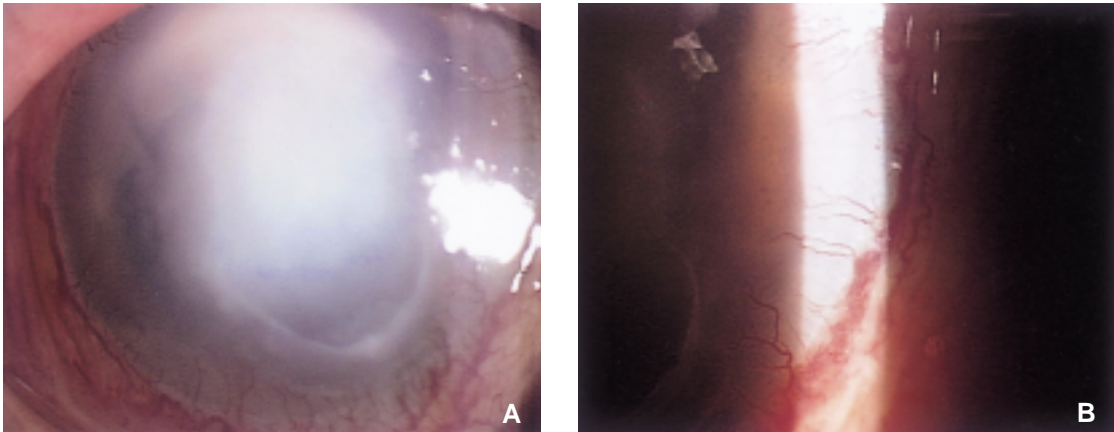


**Fig. 1.** (A) Ultrasonographic finding of the right eye shows vitreous opacity on admission day. (B) Ultrasonographic finding shows vitreous opacity is slightly increased in spite of the double intravitreal antibiotics injection (3 days after the second intravitreal injection). (C) Ultrasonographic finding shows vitreous opacity is decreased on final follow up findings (1 month after the first intravitreal injection).

sulcus. The wound was closed with two 10-0 nylon sutures. Pre-operative best-corrected visual acuity (BCVA) of the right eye was 20/40. Post-operative recovery was uneventful and BCVA of the operated eye was 20/70. A wound rupture was noted on the 21st post-operative day. He did not have any history of ocular trauma. After the repair of the wound, BCVA of the operated eye was 20/100.

On day twelve after the repair of the wound, he visited our clinic with ocular pain and visual acuity of his right eye decreased to light perception. The intraocular pressure was 8 mmHg in the right eye. Biomicroscopic examination showed wound necrosis with leakage of hypopyon. Full-thickness corneal abscess and total corneal epithelial defect were also

noted. The anterior chamber was nearly fully filled with hypopyon. Neither the IOL nor the fundus was visible. B-scan ultrasonography showed vitreous opacity on admission day (Fig. 1-A). After samplings of the conjunctival sac, anterior chamber and vitreous cavity were performed, intravitreal injection of vancomycin (1 mg/0.1 ml), amikacin (0.4 mg/0.1 ml) and amphotericin (5  $\mu$ g/0.1 ml) was given. Treatment included topical fortified vancomycin (50 mg/ml), fortified amikacin (10 mg/ml) every 1 hour alternatively and intravenous ceftazidime, and amphotericin. *Enterococcus faecalis* was identified by the cultures in samples of conjunctival sac, aqueous and vitreous humor. A second intravitreal injection of vancomycin, ceftazidime



**Fig. 2.** (A) Anterior segment photograph shows epithelial defect and corneal opacity still remain after the vitreous opacity was subsided. (B) Corneal neovascularization is also noted at the limbus.

(2.25 mg/0.1 ml), the dexamethasone was given. Ultrasonographic findings showed that vitreous opacity was slightly increased in spite of the double intravitreal injection (Fig. 1-B). *Enterococcus faecalis* proved sensitive to vancomycin and cefazidime. A third intravitreal injection of vancomycin and dexamethasone was given.

One month after the first intravitreal injection, the vitreous opacity was subsided on the ultrasonographic findings (Fig. 1-C). However corneal opacity and corneal neovascularization still remained (Fig. 2-A, B). Visual acuity of the operated eye was still light perception only.

## DISCUSSION

*Enterococcus faecalis* is an uncommon cause of postoperative endophthalmitis. According to the Endophthalmitis Vitrectomy Study, *Enterococcus faecalis* was isolated in 1.2% of all confirmed growth isolates.<sup>7</sup> Visual acuity outcomes in case of *Enterococcus faecalis* endophthalmitis are generally poor, with no light perception in 50% of cases.<sup>8,9</sup> Although the visual acuity outcome in endophthalmitis is known to be related to the virulence of the particular bacterial species,<sup>8,10,11</sup> the exact constituents that contribute to the virulence are not yet clearly defined. Aggregation substance, surface carbohydrates, fibronectin-binding moieties, extracellular toxins such as cytolysin, and lipoteichoic acid, and superoxide production are known to be con-

tributing factors to the pathogenic potential of *Enterococcus faecalis*.<sup>12-14</sup> According to the experimental model of *Enterococcus faecalis* endophthalmitis, cytolysin was reported to cause a more fulminant courses and render the infection refractory to therapeutic intervention.<sup>15</sup> Since *Enterococcus faecalis* rarely colonizes ocular structures and adjacent surfaces, infection of these organisms is either the result of seeding from contaminated material or endogenously seeding. As our patient did not have any sign of endocarditis, sepsis or urinary tract infection, it was most likely that self-contaminated organisms gained access to the eye through the wound defect. *Enterococcus faecalis* that had invaded through the post-operative wound seems to have caused the infection of both cornea and anterior chamber. The infection seems to have passed through the open posterior capsule so that the vitreous was also infected. It is reasonable to assume that endophthalmitis and corneal ulcer occurred at intervals of one or two days or nearly at the same time.

Risk factors considered for poor final visual acuity in endophthalmitis are older age, history of diabetes, corneal infiltrates or ring ulcer, abnormal intraocular pressure, rubeosis, an absent reflex, an open posterior capsule and initial visual acuity of light perception only.<sup>16</sup> Most literature suggests that persons with diabetes mellitus have a higher risk of developing endophthalmitis after intraocular surgery.<sup>11,17</sup> Furthermore, it is well known that patients with diabetes are more likely to experience

delayed wound healing, thus, they may be predisposed to wound breakdown or persistent wound defects or both, which, in turn may increase their risk of developing endophthalmitis. The Endophthalmitis Vitrectomy Study indicated that diabetics tend to be infected with virulent organisms and to have increased risk of poor final vision compared with nondiabetics.<sup>17</sup>

Vitrectomy as a treatment modality for endophthalmitis provides several theoretical advantages, including debridement of bacteria and the toxins they produce, removal of vitreous membranes, clearing of vitreous opacity, and better distribution of antibiotics.<sup>16</sup> Moreover routine immediate vitrectomy is known to have substantial benefit compared to the intravitreal injection of antibiotics in cases of endophthalmitis with light perception-only vision at presentation.<sup>16,17</sup> In our case, we could not perform immediate vitrectomy due to the accompanying corneal ulcer. Although a case of endophthalmitis caused by *Enterococcus faecalis* from contaminated donor cornea after penetrating keratoplasty has been reported,<sup>18</sup> it was an unusual case of endophthalmitis with corneal ulcer caused by *Enterococcus faecalis*. In our case, history of diabetes, postoperative wound defect and an unfavorable condition to perform early vitrectomy due to corneal ulcer resulted in a poor final visual outcome. We recommend close post-operative follow-up and patient education about the risk of endophthalmitis for patients expected to experience delayed wound healing process, postoperative wound defect or poor compliance.

## REFERENCES

1. Mundy LM, Sham DF, Gilmore MS. Relationship between enterococcal virulence and antimicrobial resistance. *Clin Microbiol Rev.* 2000;13:513-522.
2. Ejderik-Lindblad B, Lindberg M, Hakansson E. Enterococcal endophthalmitis following cataract extraction treated with ampicillin intravitreally. *Acta Ophthalmol.* 1992;70:842-843.
3. Uchio E, Inamura M, Okada K, Hatano H, Saeki K, Ohno S. A case of endogenous *Enterococcus faecalis* endophthalmitis. *Jpn J Ophthalmol.* 1992;36:215-221.
4. Fraser SG, Ohri R. Endophthalmitis caused by *Enterococcus faecalis*. *Eye.* 1995;9:535-536.
5. Bae JH, Lee SS. A case of *Enterococcus faecalis* endophthalmitis following ECCE. *J Korean Ophthalmol Soc.* 1994;35:66-70.
6. Kim US, Yu SY, Kwak HW. Two cases of *Enterococcus faecalis* endophthalmitis. *J Korean Ophthalmol Soc.* 2003;44:523-528.
7. Han DP, Wisniewski SR, Wilson LA, Barza M, Vine A, Doft BH, Kelsey SF, The Endophthalmitis Vitrectomy Study Group. Spectrum and susceptibilities of microbiologic isolates in the endophthalmitis vitrectomy study. *Am J Ophthalmol.* 1996;122:1-17.
8. Endophthalmitis Vitrectomy Study Group. Microbiologic factors and visual outcome in the endophthalmitis vitrectomy study. *Am J Ophthalmol.* 1996;122:830-846.
9. Driebe WT, Mandelbaum S, Foster RK, Schwartz LK, Culbertson WW. Pseudophakic endophthalmitis, diagnosis and management. *Ophthalmology.* 1986;93:442-448.
10. Callegan MC, Booth MC, Jett BD, Gilmore MS. Pathogenesis of gram-positive bacterial endophthalmitis. *Infect Immun.* 1999;67:3348-3356.
11. Phillips WB, Tasman WS. Postoperative endophthalmitis in association with diabetes mellitus. *Ophthalmology.* 1994;101:508-518.
12. Jett BD, Huycke MM, Gilmore MS. Virulence of enterococci. *Clin Microbiol Rev.* 1994;7:462-478.
13. Callegan MC, Engelbert M, Parke II DW, Jett BD, Gilmore MS. Bacterial endophthalmitis: epidemiology, therapeutics, and bacterium-host interaction. *Clin Microbiol Rev.* 2002;15:111-124.
14. Jett BD, Atkuri RV, Gilmore MS. *Enterococcus faecalis* localization in experimental endophthalmitis: role of plasmid-encoded aggregation substance. *Infect Immun.* 1998;66:843-848.
15. Jett BD, Jensen HG, Atkuri RV, Gilmore MS. Evaluation of therapeutic measures for treating endophthalmitis caused by isogenic toxin-producing and toxin-nonproducing *Enterococcus faecalis* strains. *Invest Ophthalmol Vis Sci.* 1992;33:1650-1656.
16. Endophthalmitis Vitrectomy Study Group. Results of the endophthalmitis vitrectomy study: a randomized trial of immediate vitrectomy and of intravenous antibiotics for the treatment of postoperative bacterial endophthalmitis. *Arch Ophthalmol.* 1995;113:1479-1496.
17. Doft BH, Misniewski SR, Kelsey SF, Fitzgerald SG, The Endophthalmitis Vitrectomy Study Group. Diabetes and postoperative endophthalmitis in the endophthalmitis vitrectomy study. *Arch Ophthalmol.* 2001;119:650-656.

18. Cameron JA, Badr IA, Miguel Risco J, Abboud E, Gonnah el-S. Endophthalmitis cluster from contaminated donor corneas following penetrating keratoplasty. *Can J Ophthalmol.* 1998;33:8-13.