

바깥귀길에서 발생한 상피-근상피암종의 세포소견

- 1예 보고 -

충북대학교 의과대학 병리학교실, 이비인후과학교실¹

이 호 창 · 송 형 근 · 최 영 석¹ · 이 옥 준

Cytologic Features of Epithelial-Myoepithelial Carcinoma Occurring in External Auditory Canal

- A Case Report -

Ho-chang Lee, M.D., Hyung Geun Song, M.D.,
Young Seok Choi, M.D.¹, Ok-Jun Lee, M.D.

Department of Pathology, and Department of
Otolaryngology¹, Chungbuk National University
College of Medicine, Cheongju, Korea

논문접수 : 2007 년 7월 12일
게재승인 : 2008 년 1월 16일

책임저자 : 이 옥 준
주 소 : (361-711) 충청북도 청주시 흥덕구 개신동 62
충북대학교 의과대학 병리학교실
전 화 : 043-269-6260
팩 스 : 043-269-6269
E-mail address : ojlee@chungbuk.ac.kr,
ok5218@hanmail.net

이 논문은 2006년도 충북대학교 학술연구 지원사업의 연구비 지원에 의하여 연구되었음. (This work was supported by Chungbuk National University Grant in 2006)

Epithelial-myoepithelial carcinoma (EMC) is a low grade malignant neoplasm that commonly occurs in the parotid gland. Recently, we investigated a case of EMC that occurred in the external auditory canal (EAC) in a 35-year-old male, and this tumor was initially diagnosed as pleomorphic adenoma. The difficulty associated with diagnosing EMC by aspiration cytology arises from both the rare incidence of this tumor and the overlapping spectrum of cytological features found in various salivary gland tumors, such as pleomorphic adenoma, basal cell adenoma and adenoid cystic carcinoma.

(*Korean J Cytopathol* 2008;19(1):52-56)

Key Words : Epithelial-myoepithelial carcinoma, Pleomorphic adenoma, Cytology

INTRODUCTION

Epithelial-myoepithelial carcinoma (EMC) is a rare biphasic salivary gland tumor that's typically composed of epithelial cells that resemble intercalated ducts and the surrounding myoepithelial cells. EMC is a low grade malignancy and it predominantly occurs in the parotid gland.¹ Making the cytologic diagnosis of EMC is diffi-

cult and it can be confused with the more common salivary neoplasms such as pleomorphic adenoma. However, the fine needle aspiration (FNA) cytology of this tumor has rarely been described in the literature. We report here on a case that was initially misinterpreted as a pleomorphic adenoma, but it was later identified as EMC of the external auditory canal (EAC) with a clinical presentation of otorrhea from the left ear.

CASE

A previously healthy 35-year-old male visited the Otolaryngology Clinic at the Chungbuk National University Hospital with a history of discharge from his left ear for a month. Computed tomography (CT) showed a 1.2 cm-sized, well-defined mass covering the cartilaginous and osseous portion of left posterior EAC and we found no definite mass or lesion on his parotid gland. Excisional biopsies from the left EAC were performed twice, and both specimens were mainly composed of granulation tissue and some squeezed epithelial tissues. Six months after the second operation, he was admitted with left ear swelling that extended to the parotid area. CT and ultrasonography demonstrated an ill-defined mass involving the posterior EAC and parotid gland. In addition to this lesion, a mass in the lower lobe of his left lung was incidentally detected. After the FNA cytology on the left parotid area, which was initially diagnosed as pleomorphic adenoma, he underwent wide excision, including the left parotid gland, the submandibular gland and the EAC, and regional lymph node dissection. He then underwent excisional biopsy of the lung mass, which was identified to be a pulmonary blastoma.

Cytologic Findings

The aspirated material was smeared onto glass slides, immediately fixed with 95% ethanol and then it was stained with Papanicolaou stain. The smear was moderately cellular and composed of both isolated cells and multilayered cellular clusters. Some larger clusters showed pseudopapillary architectures clustered along strands of fibrovascular stroma. The clusters were composed of a large number of myoepithelial cells and a smaller number of epithelial cells. The epithelial cells that formed the tubule-like structures had uniformly round and bland nuclei and scanty but well-defined cytoplasm. The myoepithelial cells, which were less cohesive and often dispersed, had elongated nuclei

with fine chromatin, small nucleoli and a large amount of clear cytoplasm. There were also numerous scattered cells with naked nuclei. Hyaline stromal globules and occasional fragments of hyaline stroma were present (Fig. 1).

Histologic Findings

The resected tumor specimen, measuring 3 × 3 cm in dimension, was reddish brown. Microscopically, the tumor cells were arranged in solid nests composed of both epithelial cells and surrounding myoepithelial cells with clear cytoplasm. The epithelial cells were cuboidal and arranged in single-layered ducts. The myoepithelial cells made up the major portion of the tumor and they had elongated nuclei with clear cytoplasm. The tumor had an infiltrative border and it was surrounded by fibrotic stroma. The neoplasm included the left EAC and parotid gland, but not the submandibular gland. There was no metastasis in the regional lymph nodes. The myoepithelial cells were positive for smooth muscle actin (1A4, Labvision, 1:50) and S-100 (polyclonal, DAKO, 1:200). The epithelial components were strongly positive for cytokeratin 19 (A53-B/A2, DiNonA, 1:500) and pancytokeratin (34betaE12/DC-10/A53-B/A2, DiNonA, 1:300), but they were negative for smooth muscle actin and S-100 (Fig. 2).

DISCUSSION

EMC mostly occurs in the major salivary glands, and mainly in the parotid glands, with a slight female predominance.^{1,2} As its name indicates, EMC is histologically a biphasic salivary-type tumor composed of ductal cells with dark cytoplasm, and these cells form an inner layer of glandular structures and myoepithelial cells in a peripheral position. EMC represents about 1% of all salivary gland neoplasms; it is more prevalent in older individuals and it affects mainly those in the sixth and seventh decades of life. Most patients present with a pain-

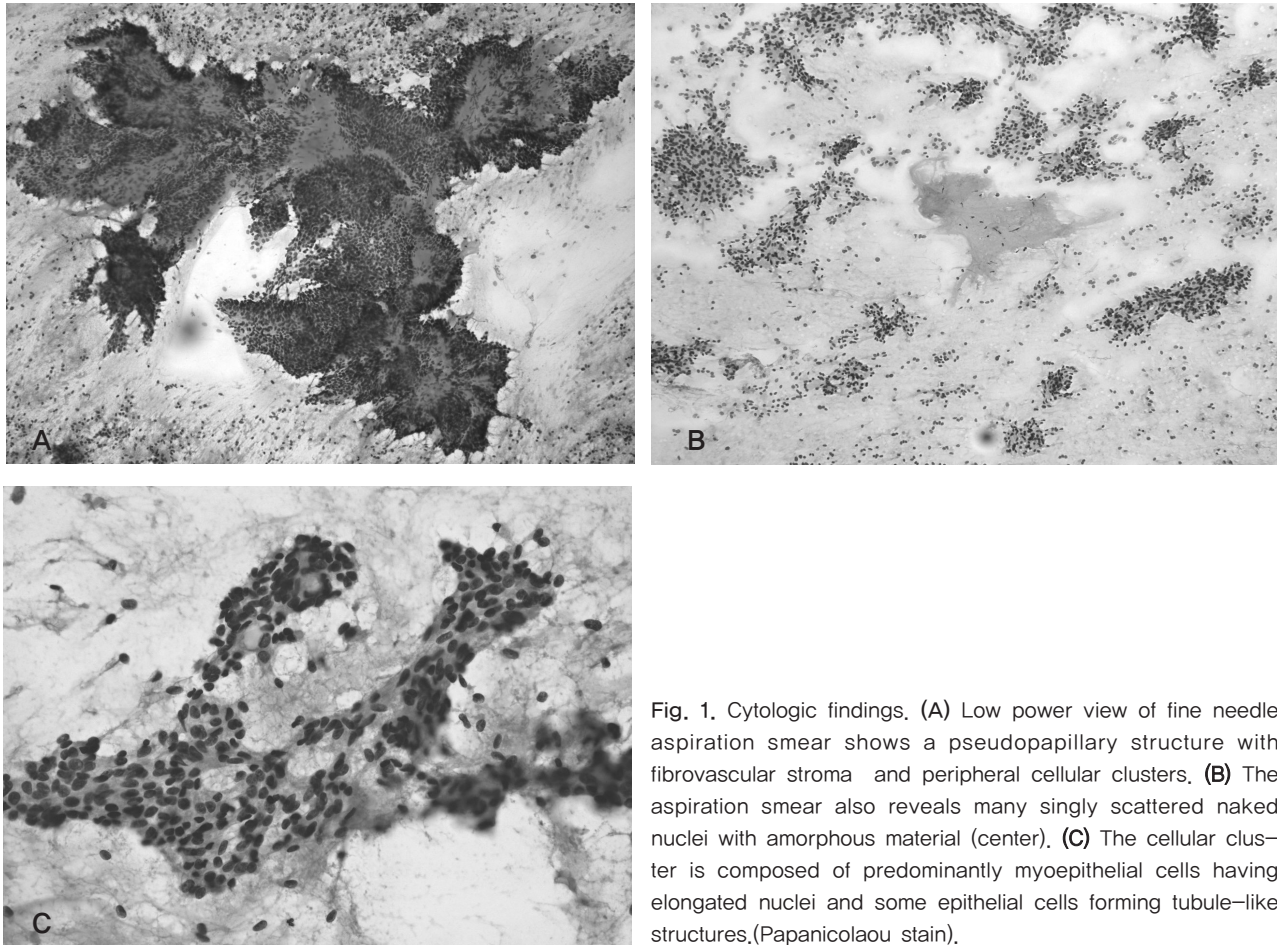


Fig. 1. Cytologic findings. (A) Low power view of fine needle aspiration smear shows a pseudopapillary structure with fibrovascular stroma and peripheral cellular clusters. (B) The aspiration smear also reveals many singly scattered naked nuclei with amorphous material (center). (C) The cellular cluster is composed of predominantly myoepithelial cells having elongated nuclei and some epithelial cells forming tubule-like structures (Papanicolaou stain).

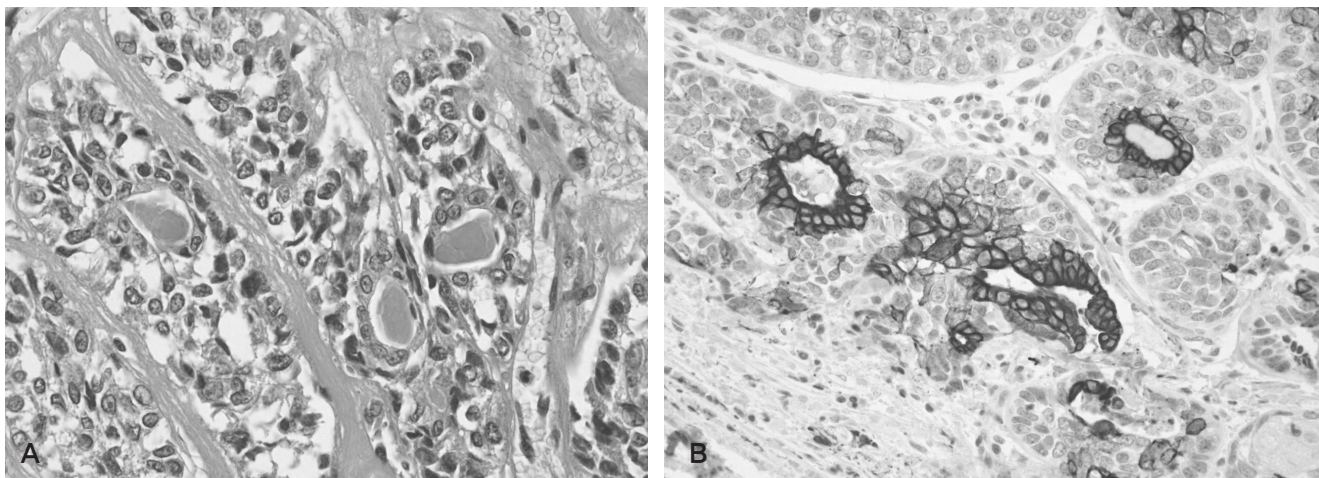


Fig. 2. Histopathologic findings. (A) The tumor cell nests are composed of centrally located and single-layered cuboidal epithelial cells and surrounding myoepithelial cells with clear cytoplasm. These nests contain hyaline globules. (H&E). (B) The epithelial cells are strongly positive for pan-cytokeratin (Immunohistochemical stain).

less, slow-growing mass. Because of its often deceptively bland cytology and expansile tumor border, EMC was initially considered within the spectrum of adenomas.³ However, it is now clear that EMC behaves as a low grade malignancy with a documented local recurrence rate of around 40% and a metastasis rate of 14%.¹ Distant metastases to regional lymph nodes, brain, lung, kidney and bone have been described.^{1,4,5}

To date, over 320 surgical biopsy cases have been reported on.² However, the cytologic descriptions of EMC have been very limited. An important factor that makes the cytologic diagnosis difficult is mainly the extreme rarity of this tumor and the overlapping spectrum of cytological appearances found in a variety of salivary gland tumors. Miliauskas et al.⁶ reviewed 23 reported cases and 83% were cytologically diagnosed as being suspicious of malignancy or malignant, and 17% were diagnosed as a benign tumor such as pleomorphic adenoma (3 cases) and monomorphic adenoma (1 case). Stewart et al.⁷ also reviewed 8 cases of EMC with three of them considered as pleomorphic adenoma, one as an adenoid cystic carcinoma, two as epithelial neoplasms not specified, one as a clear cell carcinoma and only one as an EMC. EMC was frequently misinterpreted as pleomorphic adenoma, which is one of the most common salivary gland tumors.

Carrillo et al.⁸ described neoplastic cells arranged in large clusters and they were occasionally with spherical acellular hyaline material. The peripheral cells had clear cytoplasm. Arora et al.⁹ observed two cell populations including dark and clear cells. Although a biphasic pattern can be discernible in FNA smears, it is more subtle on the FNA smears than in tissue sections and may be absent since the clear cells have fragile cytoplasm and they often appear as naked nuclei. The less consistent characteristic features are hyaline stromal globules, trabecular or pseudopapillary fragments, cell clusters with hyaline stromal material and microtubular aggregates.

Cytologically, EMC should be differentiated from the more common types of salivary gland neoplasms, including the cellular type of pleomorphic adenoma,

basal cell adenoma and adenoid cystic carcinoma. A chondromyxoid matrix and plasmacytoid myoepithelial cells are characteristic of pleomorphic adenoma, and the nuclei of pleomorphic adenoma are totally bland and finely granular. A smear showing numerous naked nuclei is not a feature of pleomorphic adenoma. The misdiagnosis of pleomorphic adenoma in our case was based on the relatively uniform nuclear features and the presence of fibromyxoid stroma. Moreover, any biphasic pattern of the tumor cells was not evident. However, the presence of numerous naked nuclei was a supporting feature of EMC. Basal cell adenoma is composed of a monomorphic population of basaloid tumor cells with no clear cell component. Thus, the presence of clear myoepithelial cells in the direct smear is an important finding against the diagnosis of basal cell adenoma. The cytological diagnosis of EMC versus adenoid cystic carcinoma may be very difficult due to focal cribriform pattern that contains acellular hyaline globules, which is a characteristic finding in adenoid cystic carcinoma, but this is also present in EMC. Cylindrical and finger-like structures are indicative of adenoid cystic carcinoma. Moreover, the presence of clear or vacuolated cells is not consistent with a diagnosis of adenoid cystic carcinoma.

In contrast to the previously reported cases, our case has unique features. First, it occurred in a relatively young man. Second, the patient came to our hospital with left ear discharge simulating a symptom of ear infection. Third, the EMC arose in the left external auditory canal and it extended into the parotid gland. Finally, this tumor was one of a double primary cancer, that is, EMC and pulmonary blastoma. This lesion could be a true diagnostic dilemma for a pathologist. However, the diagnosis of EMC based on the cytologic appreciation of the tumor cells may help to avoid an erroneous diagnosis.

REFERENCE

1. Fonseca I, Soares J. Epithelial-myoepithelial carcinoma. In: Barnes L, Eveson JW, Reichart P, Sidransky D. World Health Organization classification of tumors: Pathology & genetics. Head and neck tumors. Lyon: IARC Press, 2005;225-6.
2. Seethala RR, Barnes EL, Hunt JL. Epithelial-myoepithelial carcinoma: a review of the clinicopathologic spectrum and immunophenotypic characteristics in 61 tumors of the salivary glands and upper aerodigestive tract. *Am J Surg Pathol* 2007;31:44-57.
3. Corridan M. Glycogen-rich clear cell adenoma of the parotid gland. *J Pathol Bacteriol* 1956;72:623-6.
4. Noel S, Brozna JP. Epithelial-myoepithelial carcinoma of salivary gland with metastasis to lung: report of a case and review of the literature. *Head Neck* 1992;14:401-6.
5. Klijanienko J, Vielh P. Fine-needle sampling of salivary gland lesions VII. Cytology and histology correlation of five cases of epithelial-myoepithelial carcinoma. *Diagn Cytopathol* 1998;19:405-9.
6. Miliauskas JR, Orell SR. Fine-needle aspiration cytological findings in five cases of epithelial-myoepithelial carcinoma of salivary glands. *Diagn Cytopathol* 2003;28:163-7.
7. Stewart CJ, Hamilton S, Brown IL, MacKenzie K. Salivary epithelial-myoepithelial carcinoma: report of a case misinterpreted as pleomorphic adenoma on fine needle aspiration (FNA). *Cytopathology* 1997;8:203-9.
8. Carrillo R, Poblet E, Rocamora A, Rodriguez-Peralto JL. Epithelial-myoepithelial carcinoma of the salivary gland. Fine needle aspiration cytologic findings. *Acta Cytol* 1990;34:243-7.
9. Arora VK, Misra K, Bhatia A. Cytomorphologic features of the rare epithelial-myoepithelial carcinoma of the salivary gland. *Acta Cytol* 1990;34:239-42.