

양측 Pacman 피판을 이용한 항문 주위 파제트병의 재건

장석윤 · 배태희 · 김우섭 · 김한구

중앙대학교 의과대학 중앙대학교병원 성형외과학교실

Perianal Paget's Disease Reconstruction with Bilateral Pacman Flap

Suk Yoon Jang, Tae Hui Bae, Woo Seob Kim, Han Koo Kim

Department of Plastic and Reconstructive Surgery, Chung-Ang University Hospital, Chung-Ang University College of Medicine, Seoul, Korea

Extramammary Paget's disease is uncommon slow-growing intraepithelial adenocarcinoma which usually occurs in area of body where apocrine glands are present. A 70-year-old man had a dermatologic evaluation for anal bleeding and underwent a skin biopsy with diagnostic of Paget's disease in perianal region. Wide excision under intraoperative frozen biopsy and reconstruction operation was performed under general anesthesia. Final defect shape was elliptical and bilateral Pacman flap was performed. Elliptical perianal defect was successfully reconstructed without any complications such as congestion, partial necrosis or infection.

Key Words: Perianal Paget's disease, Extramammary Paget's disease, Pacman flap

Extramammary Paget's disease (EMPD) is uncommon slow-growing intraepithelial adenocarcinoma which usually occurs in area of body where apocrine glands are present. There have been case reports about ectopic EMPD occurring in areas without apocrine gland, but they are exceedingly rare¹. Perineum, vulva and perianal area are commonly involved areas. Since it resembles eczema or dermatitis, diagnosis and appropriate treatment is occasionally delayed. Direct dermal invasion and lymphatic spread are known pathways of EMPD's regional or distant metastasis. Therefore, delayed diagnosis and optimal treatment may critically affect patient's prognosis. Diagnosis can be made histopathologically by identifying epidermal Paget cells. Treatment of choice is

wide surgical excision with safety margin (1.5-3.0 cm) by using intraoperative frozen biopsy technique or Mohs microscopic surgery². Large defect due to wide excision is usually reconstructed by plastic surgeons. Local flap or skin graft is most commonly used and in some cases free tissue transfer is also considered. To the best of our knowledge, bilateral Pacman flap has never been reported to reconstruct perianal area defect. Herein, we introduce a case of perianal Paget's disease (PPD) reconstruction with bilateral Pacman flap.

CASE REPORT

A 70-year-old male was sent to our hospital's general

Received October 12, 2017, Revised October 29, 2017, Accepted November 9, 2017

Corresponding author: Tae Hui Bae

Department of Plastic and Reconstructive Surgery, Chung-Ang University Hospital, 102 Heuksuk-ro, Dongjak-gu, Seoul 06973, Korea
TEL: +82-2-6299-1630, FAX: +82-2-823-1049, E-mail: psbth@cau.ac.kr, ORCID: http://orcid.org/0000-0002-0342-1439

Copyright © 2018 by Korean Society for Surgery of the Hand, Korean Society for Microsurgery, and Korean Society for Surgery of the Peripheral Nerve. All Rights reserved.
This is an Open Access article distributed under the terms of the Creative Commons Attribution Non-Commercial License (<http://creativecommons.org/licenses/by-nc/4.0/>) which permits unrestricted non-commercial use, distribution, and reproduction in any medium, provided the original work is properly cited.

surgery (GS) department for further evaluation and treatment of anal lesion from local hospital. Erythematous skin lesion 5 cm in diameter was extending around anus and had bleeding tendency. Skin biopsy was confirmed as PPD. No abnormal hypermetabolic lesion was found with whole-body PET/CT scan and all tumor markers were within normal range. Routine colonoscopy and esophagogastroduodenoscopy were performed to confirm possible internal malignancy. However, there was no evidence of any underlying internal malignancy. Radical excision with intraoperative frozen biopsy was performed by GS department under general anesthesia. Final size of the defect was 15×20 cm and eventually became elliptical shape (Fig. 1, 2). Bilateral Pacman flap was performed to cover elliptical shape defect. During the flap elevation, central portion of each flaps should not be dissected to

preserve perforators that would supply the blood flow to the flap (Fig. 3). Patient had undergone colostomy operation for proper wound healing and barovac drains were inserted under each flaps. Intravenous 10 µg of alprostadil (Eglandin; Welfide, Osaka, Japan) was administered to the patient every day for 5 days and total stitch off was done after 3 weeks. Elliptical perianal defect was successfully reconstructed without any complications such as congestion, partial necrosis or infection. He was followed up in the outpatient department for a year without any evidence of recurrence or other complications (Fig. 4).

DISCUSSION

The perianal region is the second most common localization of all EMPD. It was found that 4.3% of all EMPD originates from the anorectal region³. Perianal defect is

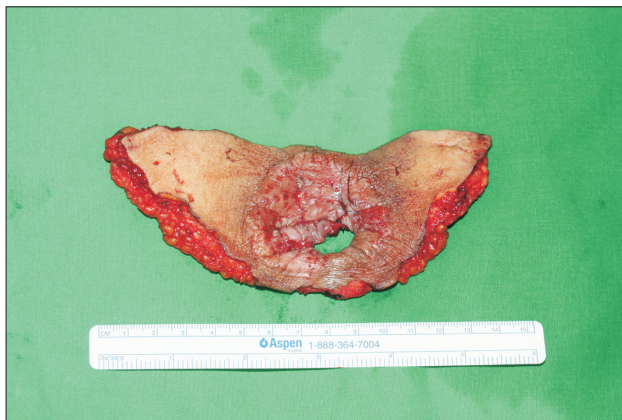


Fig. 1. Removed skin lesion.

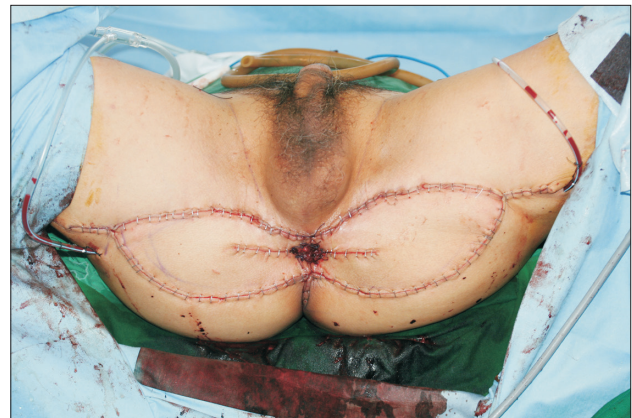

Fig. 3. Immediate postoperative image.

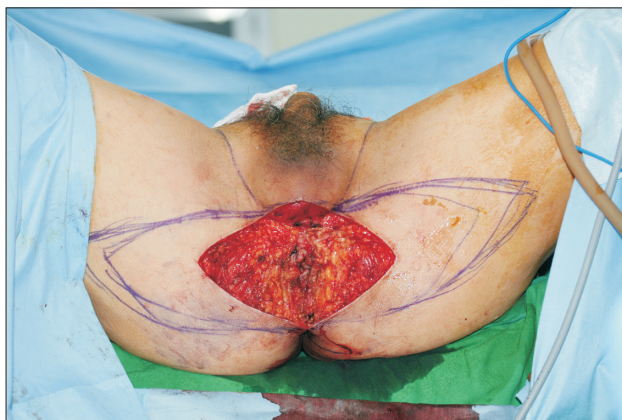


Fig. 2. Final defect after wide excision based on intraoperative frozen biopsy.

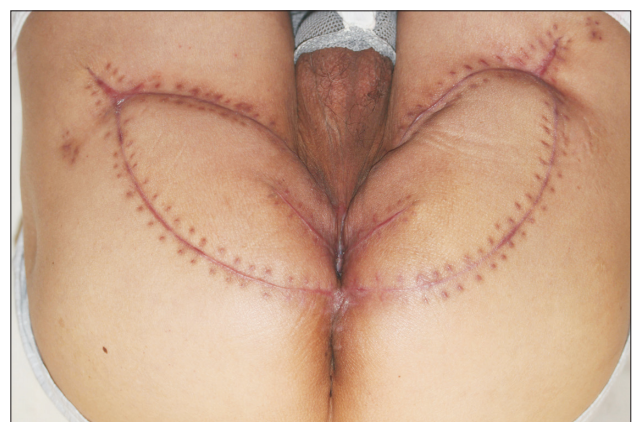

Fig. 4. Four months postoperative image.

difficult to reconstruct due to its complexity and lack of spare tissue nearby.

In our case, there were significant difference between initial skin lesion and the final defect. It was because of dermal invasion of PPD. Frozen biopsy revealed dermal invasion which extended to both proximal medial thighs without any skin lesion. The most important prognostic factor of Paget's disease is depth of invasion. Tumor with depth of >1 mm are associated with poorer prognosis⁴. Chan et al.⁵ reported that dermal invasion was found in 18.8% on histological examination after wide excision. Statistically significant relationship between dermal invasion and regional lymph node metastasis was found. Therefore, if wide range of dermal invasions was found, surgeon must be aware that much wide safety margin is required. In addition, exquisite reconstruction plan can be set up if accurate resection margin is obtained by preoperative mapping biopsy⁶.

Pacman flap was first introduced by Mithat Akan et al.⁷ for reconstruction of pressure sores which is named after a famous Japanese video game. Aoki and Hyakusoku⁸ applied this flap to various areas such as face, lower extremity, and anterior chest wall. The disadvantages of the Pacman flap are the creation of a dog-ear in the center of the flap and uncertainty of flap necrosis. To overcome the uncertainty of flap necrosis, Bonomi et al.⁹ introduced perforator-based Pacman flap. Preoperative locating of perforators made much easier flap elevation and advancement for the operators. I believed this is the first article to reconstruct a perianal defect with the Pacman flap.

In conclusion, we successfully reconstructed perianal defect caused by EMPD with bilateral Pacman flap without any complication. Bilateral pattern can efficiently cover wide elliptical defect that may require a free tissue

transfer.

CONFLICTS OF INTEREST

The authors have nothing to disclose.

REFERENCES

1. Heymann WR. Extramammary paget's disease. *Clin Dermatol*. 1993;11:83-7.
2. Mohs FE, Blanchard L. Microscopically controlled surgery for extramammary Paget's disease. *Arch Dermatol*. 1979;115:706-8.
3. Karam A, Dorigo O. Treatment outcomes in a large cohort of patients with invasive Extramammary Paget's disease. *Gynecol Oncol*. 2012;125:346-51.
4. Cohen JM, Granter SR, Werchniak AE. Risk stratification in extramammary Paget disease. *Clin Exp Dermatol*. 2015;40:473-8.
5. Chan JY, Li GK, Chung JH, Chow VL. Extramammary paget's disease: 20 years of experience in chinese population. *Int J Surg Oncol*. 2012;2012:416418.
6. Kim BJ, Park SK, Chang H. The Effectiveness of Mapping biopsy in patients with extramammary Paget's disease. *Arch Plast Surg*. 2014;41:753-8.
7. Mithat Akan I, Sungur N, Ozdemir R, Kiliç H, Sensöz O. "Pac Man" flap for closure of pressure sores. *Ann Plast Surg*. 2001;46:421-5.
8. Aoki R, Hyakusoku H. Pacman flap method. *Plast Reconstr Surg*. 2007;119:1799-802.
9. Bonomi S, Salval A, Brenta F, Rapisarda V, Settembrini F. The Pacman perforator-based V-Y advancement flap for reconstruction of pressure sores at different locations. *Ann Plast Surg*. 2016;77:324-31.

양측 Pacman 피판을 이용한 항문 주위 파제트병의 재건

장석운 · 배태희 · 김우섭 · 김한구

중앙대학교 의과대학 중앙대학교병원 성형외과학교실

유방외 파제트병은 일반적으로 아포크린 땀샘이 있는 신체 부위에서 드물게 발생하는 상피 세포 선암이다. 항문 출혈을 주소로 본원 내원한 70세 남자 환자가 피부 생검을 통해 항문 주위 파제트병으로 진단되었다. 전신 마취 하에 동결 생검을 통한 광범위 절제술이 시행되었고 최종적으로 항문 주위 타원형의 결손이 남았다. 타원형 결손의 재건을 위해 양측 Pacman 피판을 사용하였고 수술 후 부분 괴사, 울혈 또는 감염과 같은 합병증 없이 성공적으로 회복되었다.

색인단어: 항문 주위 파제트병, 유방외 파제트병, Pacman 피판

접수일 2017년 10월 12일 수정일 2017년 10월 29일

게재확정일 2017년 11월 9일

교신저자 배태희

06973, 서울시 동작구 흑석로 102, 중앙대학교병원 성형외과

TEL 02-6299-1630 FAX 02-823-1049 E-mail psbth@cau.ac.kr

ORCID: <http://orcid.org/0000-0002-0342-1439>