

Thyroid Associated Ophthalmopathy in a Patient with Hashimoto's Thyroiditis

Ho-Jun Lee¹, Yeo-Joo Kim¹, Suk-Hoe Kweon² and Ah-Jeong Ryu²

Department of Endocrinology, Soonchunhyang University College of Medicine¹, Cheonan, Department of Endocrinology, Good Morning Hospital², Pyeongtaek, Korea

A 53-year-old man consulted an ophthalmologist with a chief complaint of diplopia and bilateral eyelid swelling. He was diagnosed with hypothyroidism 2 years prior at a local clinic and had been taking levothyroxine 150 mcg daily. CT scan of the orbits showed enlargement of bilateral extraocular muscles. Laboratory findings revealed hyperthyroidism due to high dose levothyroxine. Active ophthalmopathy with Hashimoto's hypothyroidism was diagnosed and the patient was treated with steroid pulse therapy. We reported a rare case of severe ophthalmopathy with Hashimoto's thyroiditis that needed steroid pulse therapy.

Key Words: Ophthalmopathy, Hashimoto's thyroiditis, Hypothyroidism, Hyperthyroidism, Steroid

Introduction

Thyroid associated ophthalmopathy (TAO) is an autoimmune disorder of the extraocular muscles and surrounding orbital connective tissue which is generally associated with Graves' disease. Typical signs include upper eyelid retraction, periorbital edema, proptosis, and impairment of eye motility. Although TAO generally occurs in patients with hyperthyroidism due to Graves' disease, it may also accompany Hashimoto's thyroiditis. However, TAO in Hashimoto's thyroiditis is uncommon. A case of severe TAO that needs steroid pulse therapy is very rare. We described a case of severe Hashimoto's ophthalmopathy.

Case Report

A 53-year-old man consulted an ophthalmologist with a chief complaint of diplopia and bilateral eyelid

swelling for 3 months. He was diagnosed with hypothyroidism 2 years prior at a local clinic and had been taking levothyroxine 150 mcg daily. He had no family history of thyroid or autoimmune diseases. He was current smoker. An ophthalmological examination showed mild upgaze restriction (i.e., monocular elevation deficiency) and hypotropia of the right eye (Fig. 1). Laboratory examination results showed a TSH level of 0.01 μ IU/mL (0.27–5.0 μ IU/mL), free T4 level of 1.73 ng/dL (0.93–1.7 ng/dL), antithyroglobulin (anti-Tg) antibody level of 581 IU/mL (0–115 IU/mL), antithyroid peroxidase antibody (anti-TPO) level of 600 IU/mL (0–34 IU/mL), and TSH receptor antibody (TRAb) level of 13.69 IU/L (0–1 IU/L). An ultrasound examination of the thyroid showed diffuse coarse heterogeneous hypoechogenicity (Fig. 2). A computed tomography scan of the orbits revealed both periorbital soft tissue swelling and hypertrophy and enhancement of the superior rectus, medial rectus, and inferior rectus muscles (Fig. 3). An active form of orbitopathy was di-

Received August 20, 2016 / Revised 1st October 19, 2016, 2nd October 24, 2016 / Accepted October 25, 2016

Correspondence: Yeo-Joo Kim, MD, Department of Endocrinology, Soonchunhyang University College of Medicine, 31 Soonchunhyang 6-gil, Dongnam-gu, Cheonan 31151, Korea

Tel: 82-41-570-3685, Fax: 82-41-574-5762, E-mail: yeojoo@schmc.ac.kr

Copyright © 2016, the Korean Thyroid Association. All rights reserved.

© This is an open-access article distributed under the terms of the Creative Commons Attribution Non-Commercial License (<http://creativecommons.org/licenses/by-nc/4.0/>), which permits unrestricted non-commercial use, distribution, and reproduction in any medium, provided the original work is properly cited.

agnosed and methylprednisolone pulse therapy was administered (250 mg/d intravenous methylprednisolone for 4 succeeding days) which was followed by 32 mg/d oral methylprednisolone.

After glucocorticoid therapy and a decrease in the dose of levothyroxine, diplopia and bilateral eyelid swelling, which were the patient's chief complaints, im-

proved. His free T4 level was within the reference values.

Discussion

Thyroid-associated orbitopathy is a set of symptoms caused by an autoimmune process; it is typical of Graves' disease and rarely accompanies Hashimoto's thyroiditis.¹⁾ In both Graves' and Hashimoto's diseases, anti-thyroglobulin and anti-thyroid peroxidase antibodies are detected. Therefore, transformation of Graves' disease into Hashimoto's thyroiditis disease and vice versa has been known to occur.²⁾ Numerous studies have reported the prevalence of Graves' ophthalmopathy. Similar studies about the prevalence of Hashimoto's ophthalmopathy have been reported occasionally. Mild upper eyelid retraction is known to be predominant eye symptom in Hashimoto's ophthalmopathy, but severe form of ophthalmopathy with Hashimoto's thyroiditis that needs aggressive treatment was reported only a few times.

The first study about the prevalence of ophthalmopathy in Hashimoto's thyroiditis was reported by

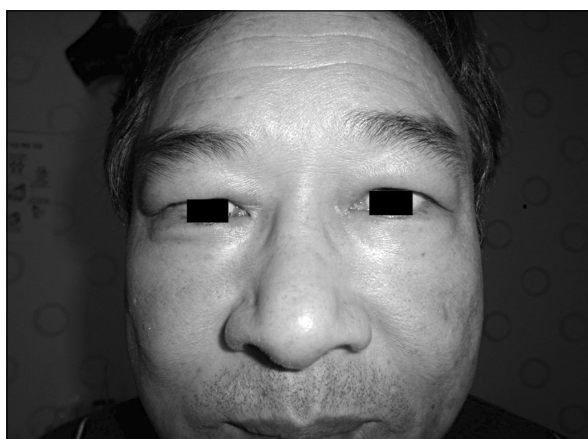

Fig. 1. A 53-year-old man suffered from diplopia and bilateral eyelid swelling.

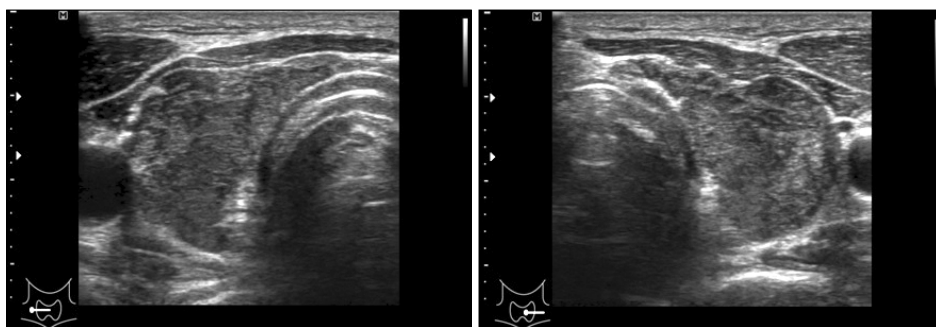


Fig. 2. Ultrasound examination showed no significant findings in both thyroid except diffuse goiter and inhomogeneous echogenicity.

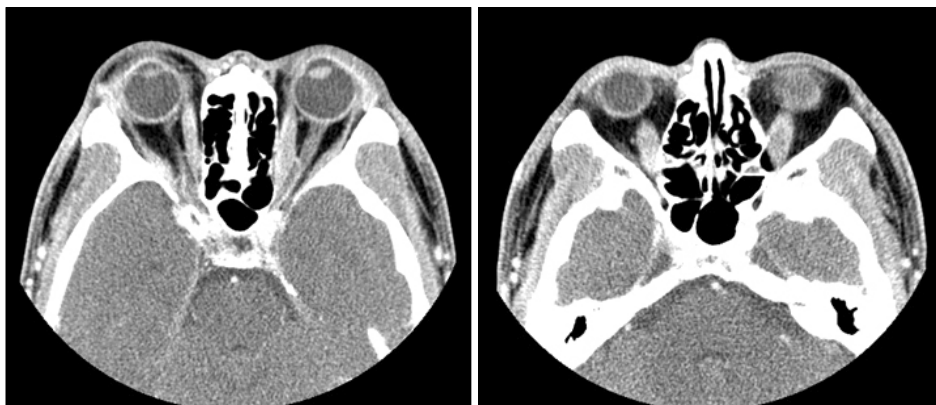


Fig. 3. CT scan of the eyes in the patients showed enlargement of both medial rectus muscles and both inferior rectus muscles.

Tjiang et al.,³⁾ who studied 91 patients recently diagnosed with Hashimoto's thyroiditis and reported that the overall prevalence of any eye signs was 34%, with about one-third of patients having upper eyelid retraction. Two patients had eye muscle dysfunction and about one-third of the patients had severe inflammatory changes such as periorbital swelling, chemosis, conjunctival injection, and proptosis. Kan et al.⁴⁾ studied the prevalence of ophthalmopathy in 110 Hashimoto's thyroiditis patients as compared with healthy control subjects. Those authors reported that the prevalence of eye signs was 22.7% in patients, which was less than that reported in Tjiang's study, and 4% in control subjects; the difference was statistically significant ($p=0.002$). Of all the patients, 11.8% had upper eyelid retraction, 6.4% had proptosis, and 5.5% had ocular myopathy. Kochairi et al.⁵⁾ studied the risk factors which may influence the development of ophthalmopathy in patients with Hashimoto's thyroiditis. A retrospective cross-sectional study included 105 patients with Hashimoto's thyroiditis with and without ophthalmopathy and investigated 6 potential risk factors; age, gender, smoking, vitamin D deficiency, serum TSH, and serum levels of antibodies to thyroid peroxidase (TPO) and thyroglobulin (Tg). They tried to find out the risk factors for i) ophthalmopathy (NOSPECS class ≥ 1), ii) upper eyelid retraction group (often the only sign in patients with Hashimoto's thyroiditis), iii) the type of ophthalmopathy (congestive ophthalmopathy vs. ocular myopathy or both), iv) the activity of the eye disease assessed as CAS (severe ophthalmopathy was taken as a NOSPECS class ≥ 3 , more active ophthalmopathy was defined as a CAS > 3). They reported a protective effect of aging on the development of ophthalmopathy in patients with Hashimoto's thyroiditis; the risk decreased by 5.4% for each additional year. They also reported a detrimental effect of smoking, with the risk of ophthalmopathy being 5.5 times greater in smokers than in non-smokers. Increased serum TSH was not shown to be a risk factor for the presence or severity of ophthalmopathy. High serum levels of TPO antibodies were found to be protective against the development of upper eyelid retraction but not ophthalmopathy. None of the tested factors

seemed to influence the risk of any ophthalmopathy subtype, namely, congestive ophthalmopathy, ocular myopathy, or mixed disease. However, gender was shown to have an effect on the activity of ophthalmopathy: men with Hashimoto's thyroiditis-related eye disease were 18 times more likely to develop more active ophthalmopathy (CAS > 3) than were women. Severe ophthalmopathy is rare in patients with Hashimoto's thyroiditis, only a few cases have been reported.⁶⁻⁹⁾ Yoshihara et al.⁶⁾ presented 2 cases of severe ophthalmopathy with Hashimoto's thyroiditis. A 64-year-old woman with Hashimoto's ophthalmopathy (CAS 3) was treated with orbital irradiation (15 Gy) and orbital decompression surgery. Another patient, 44-year-old woman with Hashimoto's ophthalmopathy (CAS 4) was managed with orbital irradiation (15 Gy) and oral prednisolone 15 mg daily. Other studies used steroid (intravenous or oral) as main treatment and all studies reported improvement of the orbital symptoms after the therapy.

The exact mechanism of TAO is still unknown. However, one theory that explains the association of TAO with autoimmune thyroid disease is immunologic cross reactivity of sensitized T lymphocytes and/or autoantibodies against antigens common to the thyroid and orbit.^{1,10-12)} Sensitized T-cell clones trigger an inflammatory process in the tissues of the orbit. As a result, leukocytes secrete cytokines, which stimulate fibroblasts to secrete glycosaminoglycans, resulting in the swelling of orbital tissues. Kochairi et al.'s study⁵⁾ revealed the protective effect of ageing on the development of Hashimoto's ophthalmopathy, and they explained that this might be due to reduced self-tolerance in young individuals and increased portion of regulatory T cells which maintain peripheral tolerance by suppressing auto-reactive T cells in old people. They also mentioned a study of systemic lupus erythematosus to explain greater risk for severe autoimmunity in men by a higher cumulative genetic load required for men to develop the autoimmune disease.¹³⁾ Several antigens have been identified as possible autoantibody targets, including TRAb,^{14,15)} the skeletal muscle calcium binding protein calsequestrin, and the fibroblast cell membrane protein collagen

XIII.¹⁶⁻¹⁹⁾ Evidences suggests that the TSH receptor is present in the orbit and is expressed on orbital fibroblasts. These findings support the hypothesis that TRAb is not only the cause of Graves' disease, but is also responsible for TAO. Since majority of patients with Hashimoto's thyroiditis test negative for TRAb, it does not explain the etiology of ophthalmopathy in Hashimoto's thyroiditis. An alternative explanation is the specific production of an antibody against an eye muscle antigen, such as calsequestrin, flavoprotein, or G2s.²⁰⁾ In this case, the patient was a current smoker and male. These were thought to be risk factors for severe ophthalmopathy. CAS or NOSPECS classification was not conducted, but as we presented, we thought his clinical symptoms were at least CAS 2 or higher. Unfortunately, we did not test antibodies such as calsequestrin, flavoprotein or G2s, but the patient was reported as TRAb, TPO Ab, and TG Ab positive. The patient's initial FT4 level was high because he was administered an overdose of synthroid at a local clinic. After decreasing the dose of synthroid, the FT4 level decreased to within normal limits.

In conclusion, we presented a case of Hashimoto's hypothyroidism with severe ophthalmopathy. Few cases of ophthalmopathy are reported in patients with Hashimoto's thyroiditis, but severe form of ophthalmopathy is very rare. This case highlights that severe symptoms and functional disorders may be accompanied by ophthalmopathy in patients with Hashimoto's thyroiditis. Thus, more intensive routine ophthalmic examinations including CAS and NOSPECS classification are needed in patients with Hashimoto's thyroiditis and steroid pulse therapy can be considered as the treatment.

References

- 1) El-Kaissi S, Frauman AG, Wall JR. *Thyroid-associated ophthalmopathy: a practical guide to classification, natural history and management. Intern Med J* 2004;34(8):482-91.
- 2) Wall JR, Bernard N, Boucher A, Salvi M, Zhang ZG, Kennerdell J, et al. *Pathogenesis of thyroid-associated ophthalmopathy: an autoimmune disorder of the eye muscle associated with Graves' hyperthyroidism and Hashimoto's thyroiditis. Clin Immunol Immunopathol* 1993;68(1):1-8.
- 3) Tjiang H, Lahooti H, McCorquodale T, Parmar KR, Wall JR. *Eye and eyelid abnormalities are common in patients with Hashimoto's thyroiditis. Thyroid* 2010;20(3):287-90.
- 4) Kan E, Kan EK, Ecemis G, Colak R. *Presence of thyroid-associated ophthalmopathy in Hashimoto's thyroiditis. Int J Ophthalmol* 2014;7(4):644-7.
- 5) Kochairi IE, Champion B, Wall JR. *Risk factors for the development of ophthalmopathy in patients with Hashimoto's thyroiditis. Ophthalmology Research* 2014;2(4):177-88.
- 6) Yoshihara A, Yoshimura Noh J, Nakachi A, Ohye H, Sato S, Sekiya K, et al. *Severe thyroid-associated orbitopathy in Hashimoto's thyroiditis. Report of 2 cases. Endocr J* 2011;58(5):343-8.
- 7) Tateno F, Sakakibara R, Kishi M, Ogawa E. *Hashimoto's ophthalmopathy. Am J Med Sci* 2011;342(1):83-5.
- 8) Grzesiuk W, Szydlarska D, Pragacz A, Bar-Andziak E. *Thyroid-associated orbitopathy in patients with Hashimoto's thyroiditis: a case report. Pol Arch Med Wewn* 2008;118(5):318-21.
- 9) Hiraga A, Mimura M, Kamitsukasa I. *Isolated inferior rectus muscle myopathy due to Hashimoto's thyroiditis. Intern Med* 2008;47(13):1283-4.
- 10) Jacobson DM. *Dysthyroid orbitopathy. Semin Neurol* 2000;20(1):43-54.
- 11) Garrity JA, Bahn RS. *Pathogenesis of graves ophthalmopathy: implications for prediction, prevention, and treatment. Am J Ophthalmol* 2006;142(1):147-53.
- 12) Costa RM, Dumitrascu OM, Gordon LK. *Orbital myositis: diagnosis and management. Curr Allergy Asthma Rep* 2009;9(4):316-23.
- 13) Hughes T, Adler A, Merrill JT, Kelly JA, Kaufman KM, Williams A, et al. *Analysis of autosomal genes reveals gene-sex interactions and higher total genetic risk in men with systemic lupus erythematosus. Ann Rheum Dis* 2012;71(5):694-9.
- 14) Bahn RS. *Clinical review 157: Pathophysiology of Graves' ophthalmopathy: the cycle of disease. J Clin Endocrinol Metab* 2003;88(5):1939-46.
- 15) Starkey KJ, Janezic A, Jones G, Jordan N, Baker G, Ludgate M. *Adipose thyrotrophin receptor expression is elevated in Graves' and thyroid eye diseases ex vivo and indicates adipogenesis in progress in vivo. J Mol Endocrinol* 2003;30(3):369-80.
- 16) Gopinath B, Ma G, Wall JR. *Eye signs and serum eye muscle and collagen XIII antibodies in patients with transient and progressive thyroiditis. Thyroid* 2007;17(11):1123-9.
- 17) Gopinath B, Musselman R, Adams CL, Tani J, Beard N, Wall JR. *Study of serum antibodies against three eye muscle antigens and the connective tissue antigen collagen XIII in patients with Graves' disease with and without ophthalmopathy: correlation with clinical features. Thyroid* 2006;16(10):967-74.
- 18) Lahooti H, Parmar KR, Wall JR. *Pathogenesis of thyroid-associated ophthalmopathy: does autoimmunity against calsequestrin and collagen XIII play a role? Clin Ophthalmol* 2010;4:417-25.
- 19) Wall JR, Lahooti H. *Pathogenesis of thyroid eye disease--does autoimmunity against the TSH receptor explain all cases? Endokrynol Pol* 2010;61(2):222-7.
- 20) Miller A, Arthurs B, Boucher A, Liberman A, Bernard N, Rodien P, et al. *Significance of antibodies reactive with a 64 kDa eye muscle membrane antigen in patients with thyroid autoimmunity. Thyroid* 1992;2(3):197-202.