

Images of Hematology

Blood Research Educational Material

BLOOD RESEARCH

Volume 52 • Number 3 • September 2017

<https://doi.org/10.5045/br.2017.52.3.157>

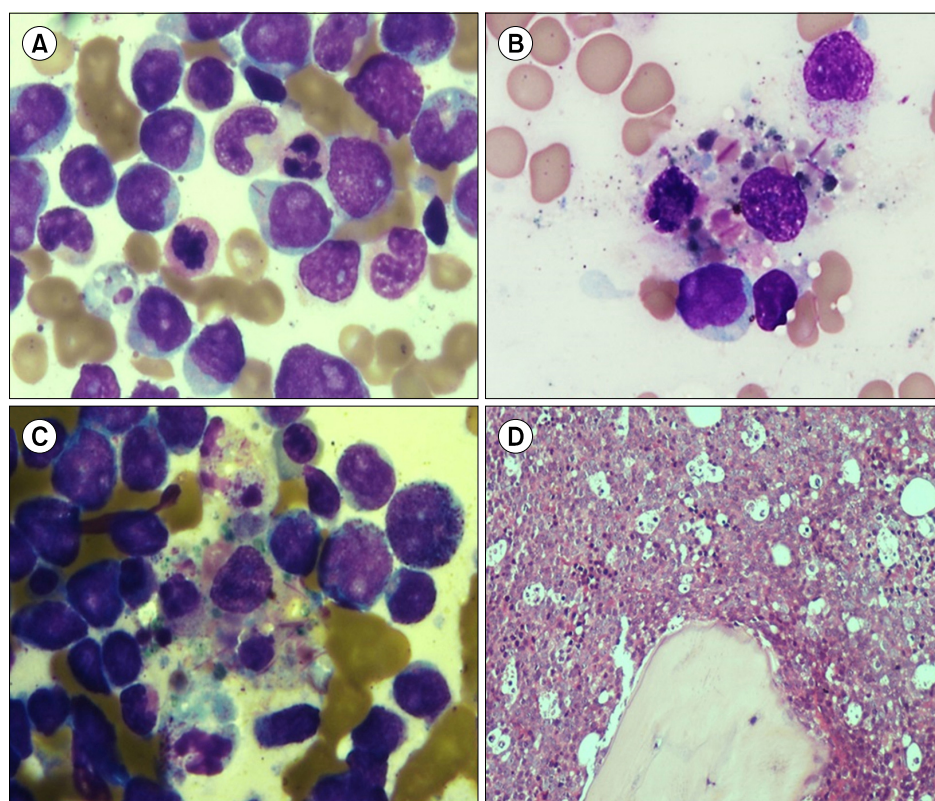
Auer rods in unusual sites: macrophage indigestion

Praveen Sharma, Jasmina Ahluwalia

Department of Hematology, Postgraduate Institute of Medical Education and Research, Chandigarh, India

Received on October 9, 2016; Revised on October 18, 2016; Accepted on January 17, 2017

Correspondence to Jasmina Ahluwalia, M.D., Department of Hematology, Postgraduate Institute of Medical Education and Research, Sector 12, Chandigarh 160012, India, E-mail: japgi@live.com



A 30-year-old woman presented with fever and fatigue. She had pallor, gum hyperplasia, and hepatosplenomegaly along with anemia (hemoglobin 7.7 g/dL), thrombocytopenia ($63 \times 10^9/L$), and leukocytosis ($20.7 \times 10^9/L$). Her marrow aspirate had 76% blasts, many showing single, long, slender Auer rods. Dysgranulopoiesis was noted (A). There was a marked increase in hemophagocytic histiocytes, some of them showing the presence of multiple ingested intact Auer rods (B, C). The histiocytes imparted a “starry sky appearance” to the trephine biopsy (D). Immunophenotyping using flow cytometry showed weak CD45-positive blasts that were positive for CD13, CD33, CD117, CD38, HLA-DR, and anti-MPO antibody. They were negative for CD41, CD61 (megakaryocytic), CD14, CD64 (monocytic), T and B cell antigens. Induction chemotherapy was initiated.

Multiple ingested intact Auer rods in histiocytes may be seen in promyelocytic leukemias during therapy. Auer rods are composed of the myeloperoxidase enzyme in a crystalline form, which may resist digestion by the enzymes in the histiocytes and thus persist. Extensive phagocytic activity, as evidenced by multiple Auer rods within the macrophages in non-promyelocytic leukemias as seen in this case, is an unusual occurrence.