



Overlap myositis associated with Sjögren's syndrome

Eun Ji Lee¹, Rae On Kim¹, Yon Hee Kim², Hakjae Roh¹

¹Department of Neurology, Soonchunhyang University Seoul Hospital, Soonchunhyang University College of Medicine, Seoul, Korea

²Department of Pathology, Soonchunhyang University Seoul Hospital, Soonchunhyang University College of Medicine, Seoul, Korea

Received: September 19, 2022

Revised: November 10, 2022

Accepted: November 11, 2022

Correspondence to

Hakjae Roh

Department of Neurology, Soonchunhyang University Seoul Hospital, Soonchunhyang University College of Medicine, 59 Daesagwan-ro, Yongsan-gu, Seoul 04401, Korea
Tel: +82-2-709-9224
Fax: +82-2-795-3687
E-mail: newroh@schmc.ac.kr

ORCID

Eun Ji Lee

<https://orcid.org/0000-0001-6690-5783>

Rae On Kim

<https://orcid.org/0000-0002-7859-6209>

Yon Hee Kim

<https://orcid.org/0000-0001-6276-7459>

Hakjae Roh

<https://orcid.org/0000-0002-0979-4279>

Overlap myositis (OM) associated with Sjögren's syndrome (SS) is a relatively uncommon disorder. It is more difficult to detect OM when a patient had not been previously diagnosed with SS. We report a case of OM associated SS that initially presented with dysphagia followed by proximal weakness. If proximal muscle weakness is preceded by dysphagia, the possibility of OM associated with connective-tissue disease should be considered.

Key words: Overlap myositis; Sjögren's syndrome; Dysphagia

Inflammatory myopathy (IM) is an acquired disease that manifests as progressive muscle weakness, where inflammatory cells infiltrate into skeletal muscle tissue. The causes of IM are categorized into idiopathic and infectious. Idiopathic IM (IIM), which can occur along with other connective-tissue diseases (CTDs), is referred to as overlap myopathy (OM).¹ Most previous studies have defined OM as myositis accompanied by CTD. Systemic sclerosis is the CTD that is most commonly related to IIM, followed by mixed CTD.² On the other hand, Sjögren's syndrome (SS) is relatively rare in OM-related CTD. We report the case of a patient with OM associated with SS who presented with dysphagia as her first symptom.

CASE

A 59-year-old female was referred from the gastroenterology department for weakness in the proximal arms and legs, which had initially presented 1 month previously. She experienced discomfort in her throat and dry mouth 2 months before the onset of weakness, which worsened with dysphagia and caused her to lose 6-7 kg in weight during that time. Her first diagnosis was gastroesophageal reflux disease, and she was prescribed antacid and proton-pump inhibitors. She found it difficult to raise her arms above her shoulders,

sit, and get up out of a chair. She also complained of fatigue, myalgia, and dry eyes, but had no skin problems. A neurological examination indicated that both hip and elbow flexions were grade IV on the Medical Research Council scale

and both shoulder abductions were worse (grade IV⁻). Distal muscle strength was not affected. Cranial nerve test results were normal, and there were no pathologic reflexes or lower motor neuron signs. The blood test results indicated ele-

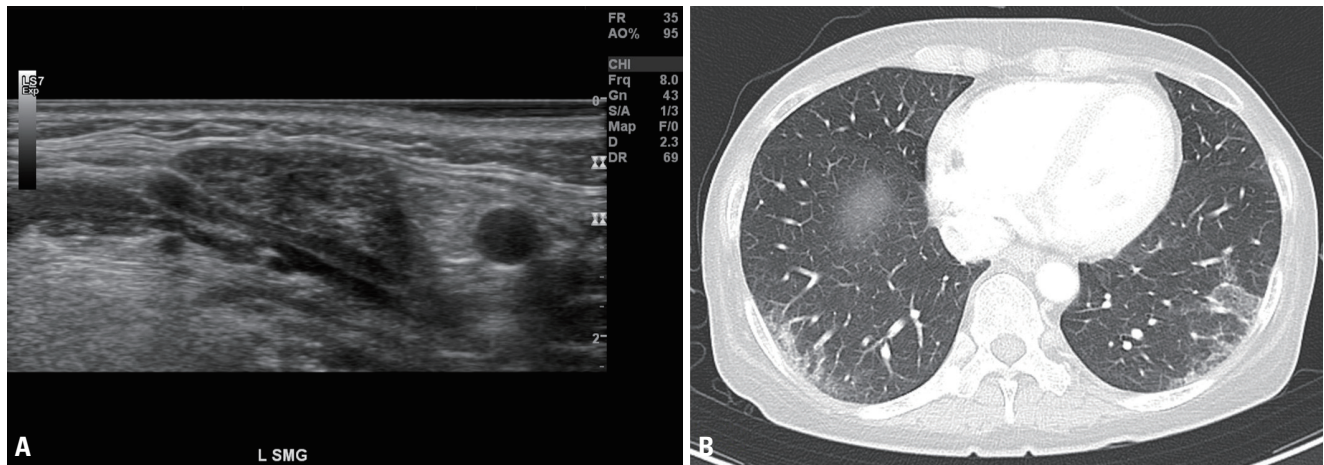


Fig. 1. (A) Left submandibular gland echography indicating moderate-to-diffuse inhomogeneity with multiple hypoechoic area, which were grade 2 to 3 according to the outcome measures in rheumatology ultrasound scoring system for Sjögren's syndrome. (B) Enhanced chest CT revealed subpleural reticular opacities with consolidation and ground-glass opacity in both lower lobes. CT, computed tomography.

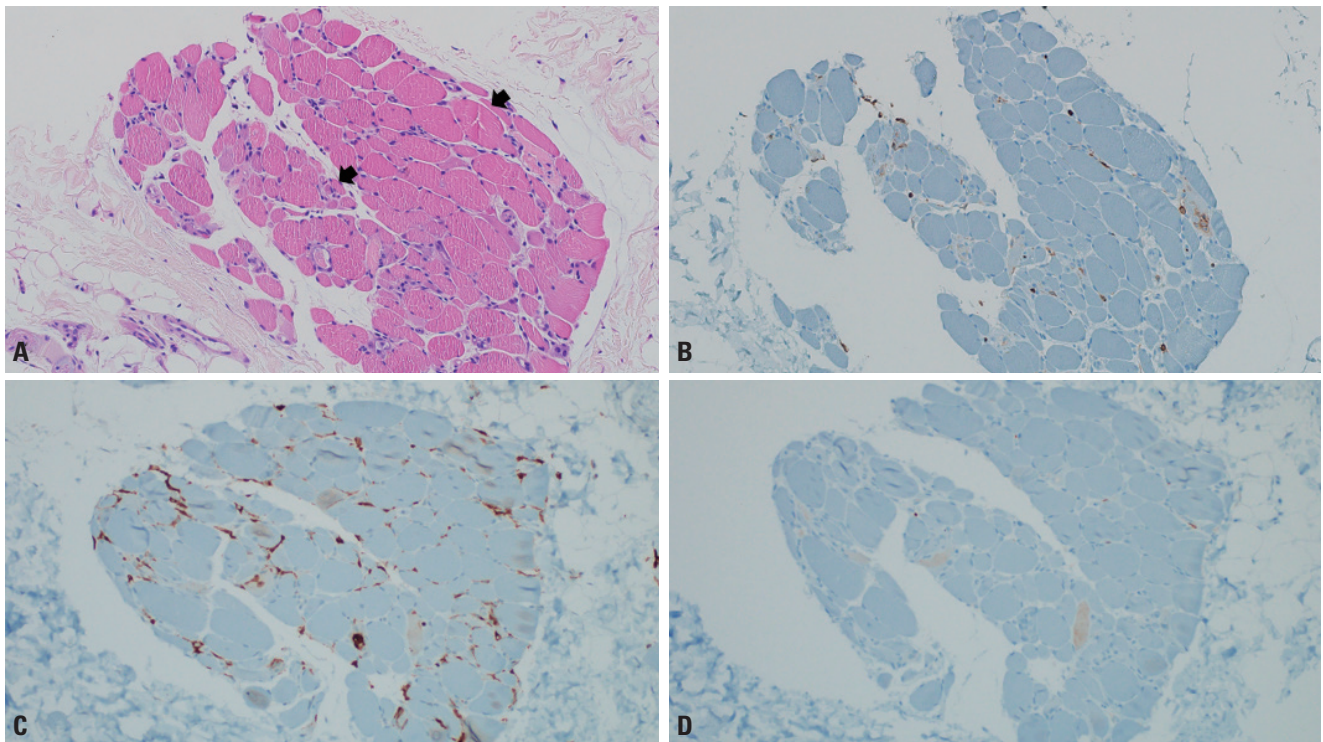


Fig. 2. (A, B, C, D) Fragments of skeletal muscular tissue indicating focal size variation in myofibers and mild lymphocytic infiltrates ($\times 200$, black arrows; A, H&E; B, LCA; C, CD4; D, CD8). H&E, hematoxylin and eosin; LCA, leukocyte common antigen.

vated aspartate aminotransferase/alanine aminotransferase (427/234 U/L, normal range 0-40/0-41 U/L), creatinine kinase (6,559 U/L, normal range 0-190 U/L), and rheumatoid factor (16 IU/mL, normal range 0-14 IU/mL), and anti-Ro antibodies were observed. Anti-Jo 1 antibody and other CTD-related markers including anti-RNP, anti-dsDNA, and anti-Scl-70 were not found. Both eyes had 3-4 mm/5 min (normal range >5 mm/5 min) of moisture on Schirmer's test. The nerve conduction study results were normal, but electromyography revealed myopathic patterns. Sonography on the salivary gland revealed heterogenous salivary glands with multiple hypoechoic areas (Fig. 1A), which supported SS. Her laryngeal elevation and closure function were decreased in the videofluoroscopic swallowing study, in which she scored 55, which was above mean values of patients with stroke or other bulbar weakness.³ Chest computed tomography revealed characteristics of interstitial lung disease (Fig. 1B). Magnetic resonance imaging of the thigh revealed diffusely increased signal intensities in the obturator, quadratus femoris, and anterior compartment muscles. A muscle biopsy was performed on the deltoid and vastus lateralis muscles using immune-histochemical staining with monoclonal antibodies (CD8, CD4, and leukocyte common antigen), and the results indicated varying focal sizes of myofibers and mild lymphocytic infiltrates, which suggested IM (Fig. 2). The patient received 60 mg of IV methylprednisolone treatment for 3 days, followed by 250, 125, and 62.5 mg for 2 days each. Since her muscle weakness did not improve markedly, 500 mg of IV cyclophosphamide treatment was applied at 3-week intervals. Her weakness had not improved markedly at 3 months after the treatment.

DISCUSSION

Dysphagia is known to appear in as many as 73% of patients with IIM, and it occurs most frequently in patients with inclusion-body myositis.⁴ It is estimated to be quite common in OM (in around 26% of patients),⁵ but it is much milder than in other types of IIM.⁶ Inflammatory involvement of the swallowing muscles causes dysphagia in IIM, and dysphagia is estimated to present as an initial symptom in less than 10% of OM cases.⁴ It can lead to severe complications such as weight loss or aspiration pneumonia. Some studies have

led to recommendations to be wary of dysphagia in which aspiration pneumonia is the leading cause of death.⁷ Meanwhile, some other findings contradict the direct association between dysphagia and mortality, instead supporting that it worsened functional status and can be regarded as a clear negative prognostic factor.⁸ In the current patient, dysphagia first appeared 2 months before the onset of proximal muscle weakness, which would have initially made it difficult to suspect myositis. Based on the diagnostic criteria for SS released in 2016,⁹ our case was considered to have satisfied the criteria for a positive Schirmer's test result and anti-Ro antibody positivity. Moreover, according to the new IIM-related classification released in 2017,¹⁰ it could be classified as OM because skeletal muscle involvement presented with features of interstitial lung disease and SS. From the perspective of discrimination, dermatomyositis can be distinguished because the patient did not show any skin signs, and the muscle biopsy results did not support anti-signal recognition particle myopathy or inclusion-body myositis. Given that OM is classified as a new subset of IIM and that SS is sometimes associated with OM, physicians should be aware of the possibility of OM in cases where overlapping symptoms such as dysphagia or SS features appear before proximal muscle weakness. We introduce this presentation by highlighting that the patient, who was ultimately diagnosed with OM, exhibited several symptoms of SS after dysphagia.

Conflicts of Interest

None.

Acknowledgements

This research was supported by the Soonchunhyang University Research Fund.

REFERENCES

1. Nuño-Nuño L, Joven BE, Carreira PE, Maldonado-Romero V, Larena-Grijalba C, Llorente Cubas I, et al. Overlap myositis, a distinct entity beyond primary inflammatory myositis: a retrospective analysis of a large cohort from the REMICAM registry. *Int J Rheum Dis* 2019;22:1393-1401.
2. Maundrell A, Proudman S, Limaye V. Prevalence of other connective tissue diseases in idiopathic inflammatory myopathies.

- Rheumatol Int 2019;39:1777-1781.
3. Jung SH, Lee KJ, Hong JB, Han TR. Validation of clinical dysphagia scale: based on videofluoroscopic swallowing study. *J Korean Acad Rehabil Med* 2005;29:343-350.
 4. Oh TH, Brumfield KA, Hoskin TL, Stolp KA, Murray JA, Bassford JR. Dysphagia in inflammatory myopathy: clinical characteristics, treatment strategies, and outcome in 62 patients. *Mayo Clin Proc* 2007;82:441-447.
 5. Lilleker JB, Vencovsky J, Wang G, Wedderburn LR, Diederichsen LP, Schmidt J, et al. The euromyositis registry: an international collaborative tool to facilitate myositis research. *Ann Rheum Dis* 2018;77:30-39.
 6. Stathopoulos P, Dalakas MC. Autoimmune neurogenic dysphagia. *Dysphagia* 2022;37:473-487.
 7. Labeit B, Pawlitzki M, Ruck T, Muhle P, Claus I, Suntrup-Krueger S, et al. The impact of dysphagia in myositis: a systematic review and meta-analysis. *J Clin Med* 2020;9:2150.
 8. Galindo-Feria AS, Rojas-Serrano J, Hinojosa-Azaola A. Clinical and prognostic factors associated with survival in Mexican patients with idiopathic inflammatory myopathies. *J Clin Rheumatol* 2016;22:51-56.
 9. Shiboski CH, Shiboski SC, Seror R, Criswell LA, Labetoulle M, Lietman TM, et al. 2016 American College of Rheumatology/European league against rheumatism classification criteria for primary Sjögren's syndrome: a consensus and data-driven methodology involving three international patient cohorts. *Arthritis Rheumatol* 2017;69:35-45.
 10. Senécal JL, Raynauld JP, Troyanov Y. Editorial: a new classification of adult autoimmune myositis. *Arthritis Rheumatol* 2017;69:878-884.