



Percutaneous mechanical lumbar disc decompression using the enSpire™ interventional discectomy system: a preliminary study

Department of Anesthesiology and Pain Medicine, College of Medicine, The Catholic University of Korea, Seoul, Korea

Jin Woo Nam, Ho Sik Moon, Young Hye Kim, and Bo Mi Han

Background: The enSpire™ interventional discectomy system is a new device for treating percutaneous disc decompression (PDD). The outcomes of using the enSpire™ for lumbar disc herniation have not been previously reported. The aim of this study was to determine the clinical effectiveness and safety of the enSpire™ interventional discectomy system for lumbar disc herniation with radiating pain.

Methods: Twelve patients with lumbar disc herniation with radiating leg pain were enrolled in the study. All patients received PDD using enSpire™. Numeric rating scale (NRS) scores for pain and Oswestry Disability Index (ODI) scores were obtained initially and after 1 and 3 months. The patients were divided into 2 groups: Group 1, in which the NRS score improved by more than 50% at 3 months after procedure, and Group 2, in which the NRS score remained the same or improved by less than 50%.

Results: After PDD using the enSpire™, the NRS scores decreased from 6.9 ± 1.2 to 2.8 ± 2.7 ; and ODI scores decreased from 25.8 ± 4.6 to 18.2 ± 5.5 . No statistical differences occurred between Group 1 ($n = 8$) and Group 2 ($n = 4$) except in the duration of prior illness.

Conclusions: The enSpire™ interventional discectomy system is effective and safe over the short-term, minimally invasive, and easy to use. (Anesth Pain Med 2017; 12: 72-76)

Key Words: Herniated disc, Percutaneous discectomy, Treatment outcome.

INTRODUCTION

Lumbar disc herniation is among the most common of the musculoskeletal diseases. Because majority of cases have a favorable prognosis, non-surgical treatment should be considered [1]. Minimally invasive procedures or lumbar disc surgery can be considered in cases that are non-responsive to conservative treatment [2].

The pathogenesis of pain in lumbar disc herniation involves both inflammatory and mechanical mechanisms [3]. If inflammation is the main cause of pain, anti-inflammatory treatment may be sufficient [4,5]. However, in the event of mechanical origin, decompression is required [6]. Surgical decompression can resolve the pain and dysfunction of disc herniation more rapidly than conservative treatment, but its benefit wanes over time [3,7]. In addition, many patients suffer from surgical complications, including failed back surgery syndrome [8-11]. Therefore, several minimally invasive procedures have been developed, which are designed to minimize tissue damage, including intradiscal electrothermal annuloplasty, nucleoplasty, automated percutaneous lumbar discectomy, percutaneous laser disc decompression, and percutaneous endoscopic lumbar discectomy [12].

The enSpire™ interventional discectomy system (SpineView, Inc., Fremont, CA, USA) is a nonthermal, needle-based tool designed to cut, grind, and aspirate disc tissue in lumbar discectomy procedures [13]. This device was approved by the Food and Drug Administration and released in the USA in 2009. However, there have been no reports to date on outcomes of treatment of lumbar disc herniation with enSpire™.

We designed this preliminary clinical observational study to evaluate the hypothesis that percutaneous mechanical lumbar

Received: August 23, 2016.

Revised: 1st, October 22, 2016; 2nd, October 24, 2016.

Accepted: October 25, 2016.

Corresponding author: Ho Sik Moon, M.D., Ph.D., Department of Anesthesiology and Pain Medicine, Yeouido St. Mary's Hospital, College of Medicine, The Catholic University of Korea, 10, 63-ro, Yeoungdeungpo-gu, Seoul 07345, Korea. Tel: 82-2-3779-1268, Fax: 82-2-783-0368, E-mail: mhsjshgma@gmail.com

This is an Open Access article distributed under the terms of the Creative Commons Attribution Non-Commercial License (<http://creativecommons.org/licenses/by-nc/4.0>) which permits unrestricted non-commercial use, distribution, and reproduction in any medium, provided the original work is properly cited.

disc decompression using enSpire™ improves the symptoms of lumbar disc herniation. The primary objective of the study was to evaluate changes in pain intensity at 3 months after percutaneous mechanical lumbar disc decompression. The secondary objective was to evaluate changes in the degree of disability after the procedure.

MATERIALS AND METHODS

This study was a preliminary clinical observational trial. The trial was conducted between January 1, 2014 and December 31, 2014 at the pain clinic of a university hospital, with a follow-up period of 3 months. The Institutional Review Board approved the study protocol; and all patients provided written informed consent to participate in the study.

Participants

Twelve participants were enrolled. The inclusion criteria were patients diagnosed with lumbar disc herniation based on symptoms (lower back pain and radiating leg pain), sign ($< 70^\circ$ in a straight-leg raise test), and magnetic resonance imaging (MRI); at least 20 years old; and non-responsive to conservative treatment for at least 3 months. The exclusion criteria were patients with a bulging or sequestered disc; foraminal or extraforaminal disc herniation; signs of motor weakness or cauda equina syndrome; coagulopathy; infectious process; concomitant spinal disease such as spinal stenosis, facet syndrome, spondylolisthesis, compression fracture, tumor, or internal disc derangement; disc height $\leq 50\%$ compared to a normal adjacent disc; multi-level lumbar disc herniation; and discordance between symptoms and MRI findings.

Variables

Before the procedure, several variables such as age, gender, symptom location, size of disc herniation, type of disc herniation on axial plane MRI, level of disc herniation, change of analgesic consumption (acetaminophen), duration of illness before percutaneous mechanical lumbar disc decompression, numeric rating scale (NRS) score for pain (0, no pain; 10, worst pain imaginable), and Oswestry Disability Index (ODI) score were assessed. NRS score and complications were assessed at the 1-month follow-up in our pain clinic. At the 3-month follow-up visit, NRS and ODI scores, change of analgesic consumption (acetaminophen), and any complications were assessed. Participants were divided into 2 groups depending on their response to treatment: Group 1, in which the NRS score improved by more than 50% at 3 months after procedure, and Group 2, in which the NRS score remained the same or improved by less than 50%.

Intervention

All surgical procedures were carried out by a single expert in the operating room. A prophylactic antibiotic was injected 30 min before the procedure. Blood pressure, electrocardiogram, and pulse oximetry were monitored during the procedure. The patients were in the prone position with a pillow placed under the pelvis to reduce the lumbar lordotic curve. The disc level was confirmed with fluoroscopy before the procedure. After skin preparation, we inserted the introducer cannula through the Kambin's triangle on the side ipsilateral to the symptoms under C-arm guidance (Fig. 1). For patients who had bilateral symptoms, we selected the appropriate side for the approach. To make a pilot hole and provide clearance for the device tip

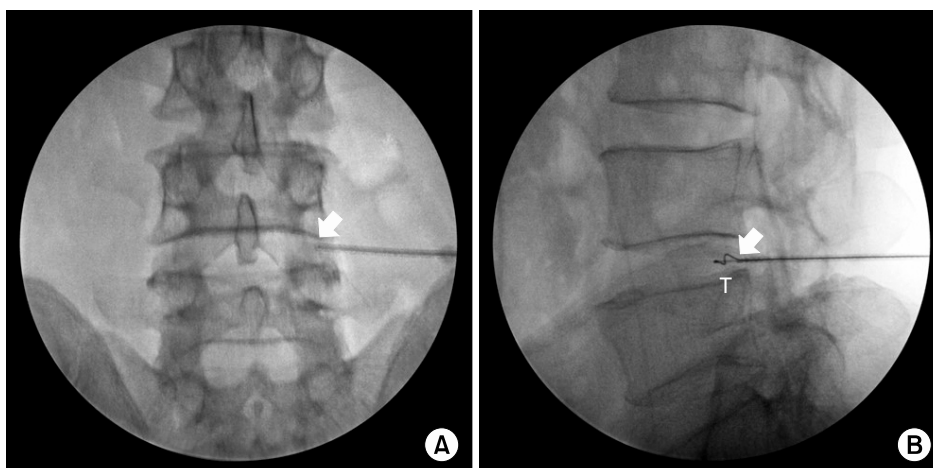


Fig. 1. C-arm images. C-arm images of percutaneous mechanical lumbar disc decompression using the enSpire™ interventional discectomy system; (A) AP view and (B) lateral view. Thick arrow: the tip of introducer cannula. T: spiral wire of device tip.

and device travel, the introducer cannula was carefully advanced into the intervertebral disc to 20 mm beyond the disc annulus. The cannula was pulled back to the junction between the nucleus and annulus on the side of entry, after which the enSpire™ device (Fig. 2) was inserted through the cannula. The depth of the device tip (5 or 10 mm) was selected by manipulating the locking ring. In the present study, a 10-mm depth was used in all cases; thus, the maximum distance between the cannula tip and device tip was 20 mm. The cannula was held parallel to and equidistant from the adjacent endplates on the fluoroscopic anterior-posterior and lateral views. With the device powered on, the cannula hub was slowly and repeatedly advanced and retracted for 90–120 s




Fig. 2. enSpire™ device. S: slider, C: tissue collection chamber, R: locking ring, and T: spiral wire of device tip.

Table 1. Demographic Data and Baseline Values for Patients

Clinical characteristics	Values
Age (yr)	44.5 ± 2.4
Gender (M/F)	7/5
Symptom location (n)	
One side	9
Both side	3
Size of disc herniation (n)	
Protrusion	8
Extrusion	4
Type of disc herniation (n)	
Central	6
Subarticular	6
Duration of illness (months)	30.4 ± 8.7
Level of disc herniation (n)	
L4–L5	7
L5–S1	5
ODI score	
Before the procedure	25.8 ± 4.6
At 3 months	18.2 ± 5.5*
NRS score	
Before the procedure	6.9 ± 1.2
At 1 month	4.0 ± 2.7*
At 3 months	2.8 ± 2.7*

Values are mean ± SD or the number of patients. Duration of disease: the period during which other conservative treatments were used, ODI: Oswestry Disability Index; NRS: numeric rating scale. *P < 0.05 vs. before the procedure.

to remove sufficient tissue. This procedure was repeated 1–2 times, during which we removed 0.5–1 ml of disc material from each patient.

Statistical analyses

All data were presented as mean ± SD or as number of patients. Differences in age, ODI score, duration of illness, and change of analgesic consumption between Groups 1 and 2 were evaluated using an unpaired *t*-test or Mann-Whitney *U* test. Comparison of gender, symptom location, size of disc herniation, type of disc herniation, amounts of aspirated disc materials, and level of disc herniation between the groups was conducted using Fisher's exact test. Differences in NRS scores between the initial and 1-month evaluations, and between the initial and 3-month evaluations, were analyzed using a paired *t*-test. P < 0.05 was considered statistically significant. All statistical analyses were performed using SPSS version 16.0.

RESULTS

Twelve individuals were recruited for this study and complete data were collected for all participants. Demographic and baseline data were presented in Table 1 and Fig. 3. Pain intensity and ODI scores were decreased after percutaneous mechanical lumbar disc decompression using the enSpire™ device; the pain reduction and improvement in disability were maintained for up to 3 months. In all individuals, the consumption of analgesics was decreased, with no difference between groups. Complications such as discitis, hematoma, or

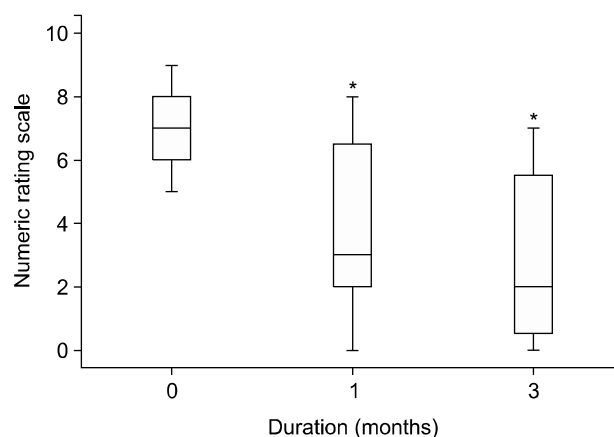


Fig. 3. Changes in the NRS over 3 months. Box plots shows the median (solid line), interquartile ranges (box), and values within 1.5 interquartile ranges from each side of the box (whiskers). *P < 0.05 compared with the initial NRS score.

Table 2. Comparison between Group 1 and Group 2

Variables	Group 1 (n = 8)	Group 2 (n = 4)	P value
Age (yr)	45.0 ± 7.9	43.5 ± 10.6	0.791
Gender (M/F)	6/2	1/3	0.223
NRS before the procedure	6.3 ± 1.2	6.1 ± 0.9	0.780
Symptom location (one side/both sides)	6/2	3/1	0.762
Size of disc herniation (protrusion/extrusion)	6/2	2/2	0.553
Type of disc herniation (central/subarticular)	3/5	3/1	0.552
Level of disc herniation (L4-L5/L5-S1)	4/4	3/1	0.581
Decrease of analgesic consumption (acetaminophen), mg/day	893.8 ± 336.4	487.5 ± 325	0.091
Amount of aspirated disc material (0.5 ml/1.0 ml)	1/7	0/4	1.000
Duration of illness (months)	18.4 ± 27.1	54.5 ± 21.0	0.041

Values are mean ± SD or the number of patients. Group 1: the NRS score improved by $\geq 50\%$ at 3 months after the procedure, Group 2: the NRS score stayed the same or improved by $\leq 50\%$ at 3 months after the procedure, NRS: numeric rating scale.

pain aggravation were absent in all patients.

Eight patients were placed in Group 1 and 4 in Group 2. There were no statistical differences between Groups 1 and 2, except that Group 2 had a longer mean duration of illness prior to the intervention (Table 2).

DISCUSSION

We investigated outcomes of the enSpire™ interventional discectomy system in 12 patients with lumbar disc herniation for 3 months after treatment. After percutaneous mechanical lumbar disc decompression using the enSpire™ device, NRS and ODI scores were decreased. The success rate in reducing the NRS score more than 50% was 66.7%, similar to or better than other percutaneous disc decompression (PDD) procedures [14-19]. Moreover, there were no complications related to the enSpire™ discectomy procedure.

PDD is increasingly performed as an alternative to open discectomy [12,19]. Open discectomy has added risks related to general anesthesia, hospital stays of ≥ 2 days, high cost, potential complications related to broad tissue injury, and the possibility of persistent or recurrent pain [8]. On the other hand, percutaneous nuclear decompression procedures have advantages of no requirement for general anesthesia, discharge on the day of the procedure, relatively low cost, and less tissue injury.

The enSpire™ device appears similar to the Dekompessor® (Stryker Spine, Allendale, NJ, USA). Both are a high-rpm device for percutaneous mechanical disc decompression, but with different methods of removal of herniated nuclear material. The tip of the enSpire™ device is an expandable

spiral cutting wire, whereas, the Dekompessor® has a screw-shaped tip [20]. In our experience, the enSpire™ has certain advantages over the Dekompessor®. First, the expandable spiral cutting wire of the enSpire™ device is wider than the tip of the Dekompessor®. When the spiral wire of the enSpire™ device is deployed, the maximum sweep diameter is 7 mm [13]. On the other hand, the Dekompessor® has 4 differently sized tips (13-, 15-, 17-, and 19-gauge) and 13 gauge (1.83 mm) is the maximum diameter. Second, the volume of aspirated disc material can be predetermined (0.5 or 1 ml) by manipulating the locking ring of the enSpire™ device. In the case of enSpire™, we anticipated better treatment results because of its wider cutting probe.

There is some debate over the efficacy of PDD. PDD, including nucleoplasty and use of the Dekompessor®, has only a weakly positive recommendation for treatment of lumbar radicular pain [21]. In other systematic literature reviews, the level of evidence for use of the Dekompessor® for chronic back pain and radicular leg pain is limited [2,18,22], particularly for long-term effects [23]. Despite negative results and recommendations against using PDD, few well-designed trials of PDD have been conducted, as compared to many trials of other treatment modalities such as open discectomy and epidural steroid injection [18].

Several limitations of this study should be considered when interpreting the results. First, the sample size was too small to evaluate correlations between clinical effectiveness and other variables or to identify possible rare complications related to the procedure; hence, the results may have little clinical significance. This was a preliminary study and participants were limited to improve the quality of the study. Second, the

study period was limited and therefore, we were able to analyze only short-term outcomes of using enSpire™ (≤ 3 months). Therefore, further randomized controlled trials (enSpire™ vs. open discectomy or enSpire™ vs. other PDDs) and long-term follow-up studies are needed.

In conclusion, the enSpire™ interventional discectomy system is minimally invasive, easy to use, and effective and safe over the short term.

REFERENCES

- Andersson GB, Brown MD, Dvorak J, Herzog RJ, Kambin P, Malter A, et al. Consensus summary of the diagnosis and treatment of lumbar disc herniation. *Spine (Phila Pa 1976)* 1996; 21(24 Suppl): S75-8.
- Manchikanti L, Abdi S, Atluri S, Benyamin RM, Boswell MV, Buenaventura RM, et al. An update of comprehensive evidence-based guidelines for interventional techniques in chronic spinal pain. Part II: guidance and recommendations. *Pain Physician* 2013; 16(2 Suppl): S49-283.
- Long DM. Surgery for back and neck pain (including radiculopathy). In: Wall & Melzack's textbook of pain. 6th ed. Edited by McMahon SB, Koltzenburg M, Tracey I, Turk DC: Philadelphia, Elsevier Saunders. 2013, pp 1012-27.
- Manchikanti L, Singh V, Pampati V, Falco FJ, Hirsch JA. Comparison of the efficacy of caudal, interlaminar, and transforaminal epidural injections in managing lumbar disc herniation: is one method superior to the other? *Korean J Pain* 2015; 28: 11-21.
- Kang H, Shin HY. Epidural steroid injection in spinal pain: a study on the NECA report. *Anesth Pain Med* 2014; 9: 9-18.
- Lurie JD, Tosteson TD, Tosteson AN, Zhao W, Morgan TS, Abdu WA, et al. Surgical versus nonoperative treatment for lumbar disc herniation: eight-year results for the spine patient outcomes research trial. *Spine (Phila Pa 1976)* 2014; 39: 3-16.
- Borenstein D. Mechanical low back pain--a rheumatologist's view. *Nat Rev Rheumatol* 2013; 9: 643-53.
- Bosscher HA, Heavner JE. Incidence and severity of epidural fibrosis after back surgery: an endoscopic study. *Pain Pract* 2010; 10: 18-24.
- Chan CW, Peng P. Failed back surgery syndrome. *Pain Med* 2011; 12: 577-606.
- Rohde V, Mielke D, Ryang Y, Gilsbach JM. The immediately failed lumbar disc surgery: incidence, aetiologies, imaging and management. *Neurosurg Rev* 2015; 38: 191-5.
- Shamim MS, Parekh MA, Bari ME, Enam SA, Khursheed F. Microdiscectomy for lumbosacral disc herniation and frequency of failed disc surgery. *World Neurosurg* 2010; 74: 611-6.
- Chen Y, Derby R, Lee SH. Percutaneous disc decompression in the management of chronic low back pain. *Orthop Clin North Am* 2004; 35: 17-23.
- Bartsch T, Goadsby PJ. Increased responses in trigeminocervical nociceptive neurons to cervical input after stimulation of the dura mater. *Brain* 2003; 126: 1801-13.
- Lee SH, Derby R, Sul Dg, Hong Jw, Kim GH, Kang S, et al. Efficacy of a new navigable percutaneous disc decompression device (L'DISQ) in patients with herniated nucleus pulposus related to radicular pain. *Pain Med* 2011; 12: 370-6.
- Singh V, Manchikanti L, Benyamin RM, Helm S, Hirsch JA. Percutaneous lumbar laser disc decompression: a systematic review of current evidence. *Pain Physician* 2009; 12: 573-88.
- Mirzai H, Tekin I, Yaman O, Bursali A. The results of nucleoplasty in patients with lumbar herniated disc: a prospective clinical study of 52 consecutive patients. *Spine J* 2007; 7: 88-92.
- Amoretti N, David P, Grimaud A, Flory P, Hovorka I, Roux C, et al. Clinical follow-up of 50 patients treated by percutaneous lumbar discectomy. *Clin Imaging* 2006; 30: 242-4.
- Manchikanti L, Singh V, Calodney AK, Helm S 2nd, Deer TR, Benyamin RM, et al. Percutaneous lumbar mechanical disc decompression utilizing Dekompressor®: an update of current evidence. *Pain Physician* 2013; 16(2 Suppl): SE1-24.
- Lemcke J, Al-Zain F, Mutze S, Meier U. Minimally invasive spinal surgery using nucleoplasty and the Dekompressor tool: a comparison of two methods in a one year follow-up. *Minim Invasive Neurosurg* 2010; 53: 236-42.
- Lierz P, Alo KM, Felleiter P. Percutaneous lumbar discectomy using the Dekompressor system under CT-control. *Pain Pract* 2009; 9: 216-20.
- Ong D, Chua NH, Vissers K. Percutaneous disc decompression for lumbar radicular pain: a review article. *Pain Pract* 2016; 16: 111-26.
- Vorobeychik Y, Gordin V, Fuzaylov D, Kurowski M. Percutaneous mechanical disc decompression using Dekompressor device: an appraisal of the current literature. *Pain Med* 2012; 13: 640-6.
- Boswell MV, Trescot AM, Datta S, Schultz DM, Hansen HC, Abdi S, et al. Interventional techniques: evidence-based practice guidelines in the management of chronic spinal pain. *Pain Physician* 2007; 10: 7-111.