

A CASE OF RIGHT SIDED AORTIC ARCH COMBINED WITH ATRIAL SEPTAL DEFECT

GEUN JIN HA, MD¹, MYEUNG JOON SUNG, MD¹, YOUNG SOO LEE, MD¹, JIN BAE LEE, MD¹,
JAE KEAN RYU, MD¹, SUB LEE, MD², JI YOUNG CHOI, MD¹, OH CHUN KWON, MD²,
SUNG GUG CHANG, MD¹ AND KEE SIK KIM, MD¹

¹DEPARTMENT OF CARDIOLOGY, ²THORACIC SURGERY, CATHOLIC UNIVERSITY OF DAEGU SCHOOL OF MEDICINE, DAEGU, KOREA

Right sided aortic arch is an uncommon congenital anomaly. It can be classified into three types, depending on the left aortic arch's degenerating pattern and the branching pattern of the great vessels. It can be associated with major congenital heart disease, depending on the type of right sided aortic arch. We report a case of an 18-years-old female who has right sided aortic arch with atrial septal defect (ASD). In our case, the patient had a right sided aortic arch and aberrant left subclavian artery, also she had ASD (ostium secundum) and moderate tricuspid regurgitation with pulmonary hypertension. The patient was successfully performed patch closure of ASD and tricuspid valve annuloplasty via midline sternotomy. The patient had uneventful postoperative course.

KEY WORDS: Right sided aortic arch · Atrial septal defect.

INTRODUCTION

Right sided aortic arch is an uncommon congenital anomaly with a frequency of approximately 0.1% among the general population.¹⁾ Right sided aortic arch results from involution of part of left dorsal aorta and persistence of right dorsal aorta. It can be associated with major congenital heart disease, depending on the type of right aortic arch.²⁻⁵⁾ We report a case of an 18-years-old female who has right sided aorta with atrial septal defect (ASD).

CASE

An 18-years-old female was admitted to our hospital due to intermittent mild dyspnea on exertion for 2 years. The patient had no past medical history and family history of cardiac disease. The vital signs were stable. The chest X-ray showed mild cardiomegaly and increased pulmonary vascularity in both lungs with suspicious right ventricular dilatation (Fig. 1). Trans-thoracic echocardiography showed a large ostium secundum ASD (32-38 mm) with moderate tricuspid regurgitation suggestive of pulmonary hypertension [pulmonary artery systolic pressure (PASP) = 58 mmHg], and markedly enlarged right atrium and right ventricle (Fig. 2). Left ventricular ejection fraction and regional wall motion were normal. The pulmonary-to-systemic blood flow ratio (Qp/Qs) measured by cardiac catheter-

ization was 13.25 [systemic artery oxygen saturation (SAO2) = 97%, mixed venous oxygen saturation (MVO2) = 69.5%, pulmonary artery oxygen saturation (PAO2) = 95%, pulmonary vein oxygen saturation (PVO3) = 97%]. A chest dynamic computed tomography (CT) showed right sided aortic arch with aberrant left subclavian artery and enlargement of right

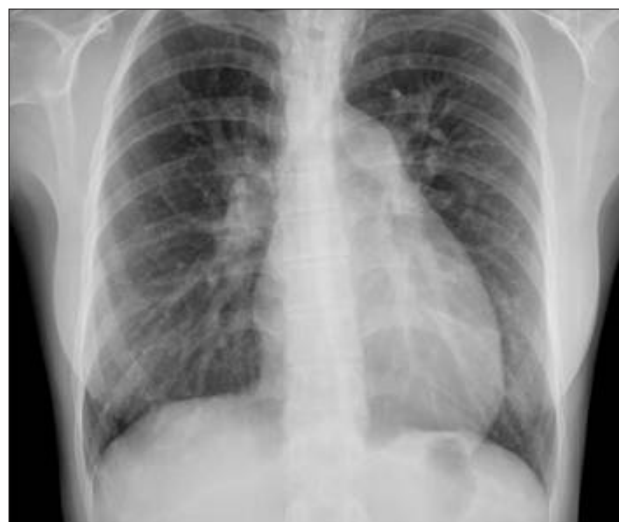

Fig. 1. Chest X-ray showed mild cardiomegaly and increased pulmonary vascularity in both lungs.

• Received: July 27, 2010 • Revised: October 26, 2010 • Accepted: November 16, 2010

• Address for Correspondence: Kee Sik Kim, Department of Cardiology, Catholic University of Daegu School of Medicine, 3056-6, Daemyeong 4-dong, Nam-gu, Daegu 705-718, Korea Tel: +82-53-650-3015, Fax: +82-53-621-3166, E-mail: kks7379@cu.ac.kr

• This is an Open Access article distributed under the terms of the Creative Commons Attribution Non-Commercial License (<http://creativecommons.org/licenses/by-nc/3.0>) which permits unrestricted non-commercial use, distribution, and reproduction in any medium, provided the original work is properly cited.

atrium and right ventricle (Fig. 3).

The patient was successfully performed patch closure of ASD and tricuspid valve annuloplasty via midline sternotomy. The postoperative course was uneventful and the patient remained well during the 2 years follow-up period.

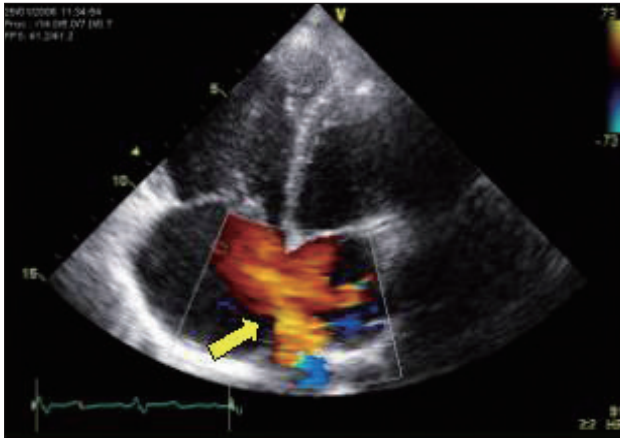


Fig. 2. Transthoracic echocardiography showed a large atrial septal defect (arrow), ostium secundum type (32-38 mm).

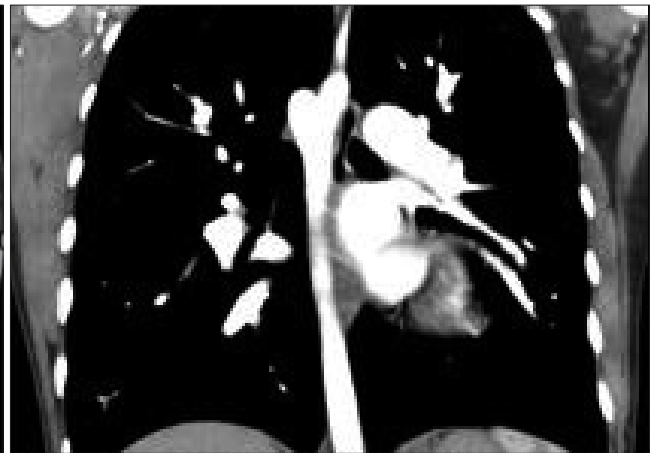
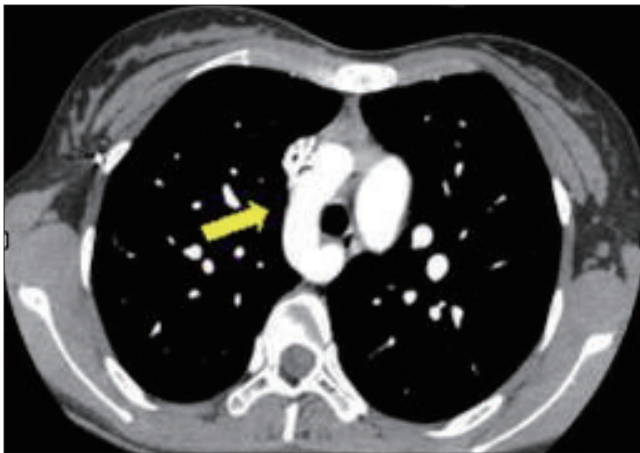
Fig. 3. Chest dynamic computed tomography showed right sided aortic arch (arrow).

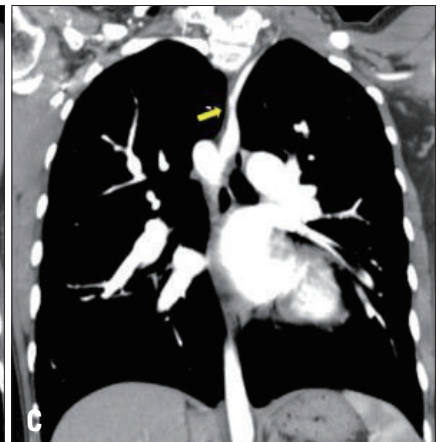
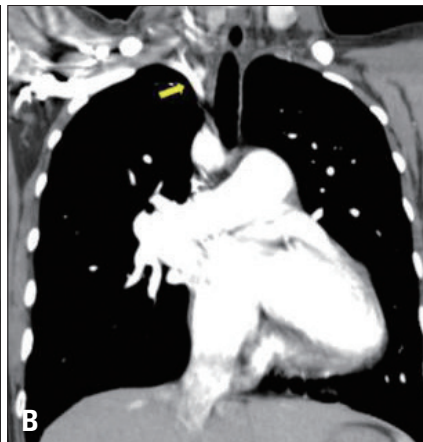
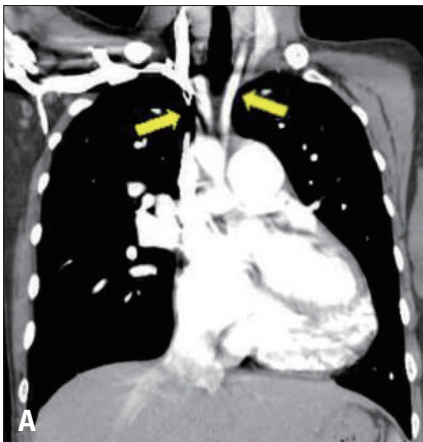Fig. 4. Chest dynamic computed tomography showed the great vessels originated from the arch in the following order, left common carotid artery (right arrow) (A), right common carotid artery (left arrow) (A), right subclavian artery (B), and aberrant left subclavian artery (C). Left subclavian artery originated from descending aortic arch.

DISCUSSION

Right sided aortic arch is rare congenital anomaly, presenting in 0.1% of the general population.¹⁾ Embryologically, the aortic arch is formed from the left aortic arch as the right aortic arch is degenerated. However, if the left aortic arch is degenerated instead of the right aortic arch, the aortic arch will be formed from right aortic arch.²⁾³⁾

Right sided aortic arch can be classified into three types, depending on degenerating pattern of the left aortic arch and branching pattern of the great vessels. The mirror image type (type I) is when the great vessels originate from the arch in the following order, left innominate artery, right common carotid artery and right subclavian artery. The most common type (type II) is when the great vessels originate from the arch in the following order, left common carotid artery, right common carotid artery, right subclavian artery and left subclavian artery originating from Kommerell's diverticulum. Finally, the very rare type is when the left common carotid artery, right common carotid artery and right subclavian artery originate from the right aortic arch orderly and the left subclavian artery is not connected.³⁾⁶⁾ In our case, the great vessels originate

from the arch in the following order, left common carotid artery, right common carotid artery, right subclavian artery, and aberrant left subclavian artery (Fig. 4).

Right sided aortic arch does not manifest symptoms necessarily and it is not needed surgical correlation itself. But this condition is occasionally associated with other congenital disease including esophageal atresia, tracheoesophageal fistula, vascular ring and aortic arch anomaly around the trachea and esophagus which can cause clinical symptom like respiratory obstruction and dysphagia.⁷⁾ Type I is associated with major congenital heart disease, in 98% of patients, including a tetralogy of Fallot, truncus arteriosus and tricuspid atresia. Type II is less frequently associated with major cardiac anomalies (5-10%).^{2,4)} ASD is congenital heart disease very rarely accompanying right sided aortic arch.^{3,5)} In our case, the patient had right sided aortic arch and ASD (ostium secundum) with moderate tricuspid regurgitation.

Surgical approach in patients with right sided aortic arch is important consideration because the anatomical features of right sided aortic arch present specific technical problems compared with a normal left sided aorta. The surgeon must make a decision of approach method according to the vascular ring anatomy and the associated tracheal or cardiac anomalies. The surgical approaches used in such cases include a midline sternotomy, right thoracotomy, left thoracotomy, and bilateral thoracotomy. In our case, the patient was successfully performed patch closure of ASD and tricuspid valve annuloplasty via midline sternotomy. The patient's postoperative course was

uneventful.

In conclusion, right sided aortic arch combined with ASD is rare condition. We report 18-years-old female who has right sided aortic arch combined with ASD, she was successfully performed patch closure of ASD and tricuspid valve annuloplasty via midline sternotomy.

REFERENCES

1. VanDyke CW, White RD. *Congenital abnormalities of the thoracic aorta presenting in the adult. J Thorac Imaging* 1994;9:230-45.
2. Shuford WH, Sybers RG. *The aortic arch and its malformations. In: Shuford WH, Sybers RG, editors. Right aortic arch. Springfield: Charles C. Thomas;1974. p.52-68.*
3. Stewart JR, Kincaid OW, Titus JL. *Right aortic arch: plain film diagnosis and significance. Am J Roentgenol Radium Ther Nucl Med* 1966;97:377-89.
4. Ruckman RN. *Anomalies of the aortic arch complex. In: Adams FH, Emmanouilides GC, Riemenschneider TA, editors. Moss' heart disease in infants and adolescents, 5th ed. Baltimore: Williams & Wilkins;1994.*
5. Stewart JR, Kincaid OW, Edwards JE. *An atlas of vascular rings and related malformations of the aortic arch system. Springfield, Charles C. Thomas;1964. p.8-13, 124-219.*
6. Kaneda T, Lemura J, Zhang Z, Inoue T, Onoe M, Kitayama H, Nakamoto S, Oka H, Otaki M, Oku H. *A case of Stanford type B aortic dissection involving a right-sided aortic arch with mirror-image branching and right-sided descending aorta. Thorac Cardiovasc Surg* 2001;49:51-3.
7. Allen SR, Ignacio R, Falcone RA, Alonso MH, Brown RL, Garcia VF, Inge TH, Ryckman FC, Warner BW, Azizkhan RG, Tiao GM. *The effect of a right-sided aortic arch on outcome in children with esophageal atresia and tracheoesophageal fistula. J Pediatr Surg* 2006;41:479-83.