

Unusual bilateral vulvar liposarcoma

Ju Hyun Kwak, Sun Mi Shin, Jae Won Kim, Nak Woo Lee

Department of Obstetrics and Gynecology, Korea University Ansan Hospital, Korea University College of Medicine, Ansan, Korea

Liposarcoma of vulva is a rare malignant tumor. Only fifteen cases of vulvar liposarcoma have been reported in English literature. Because of extreme rarity of vulvar liposarcoma, it is initially misdiagnosed as benign tumor such as lipoma. This paper aims to present a unique case of liposarcoma of bilateral vulvae with a review of the literature of previously reported cases.

Keywords: Lipoma; Liposarcoma; Radiotherapy; Vulva

Introduction

Liposarcoma is the most common subtype of soft tissue sarcoma, representing an estimated 20% of all sarcoma in adults. The disease may represent anywhere in the body, although it occurs mostly in the extremities, trunk, or abdomen. Vulvar liposarcoma is extremely rare to have been reported only sixteen of cases up to date [1-10]. Vulvar liposarcoma can be mistaken as benign lesions due to its location and rarity, which leads to mistreatment and a delayed diagnosis. We present a case of unusual bilateral vulvar liposarcoma treated by surgical resection of the mass in combination with adjuvant radiotherapy.

Case report

A 37-year-old, gravid 2, para 2, woman with no significant past history was referred from a gynecologic clinic because of bilateral vulvar swelling. The vulvar swelling had developed for several years but she never visited hospital for evaluation because she felt that she gained body fat in the groin. She recognized palpable and painless mass on both vulvae 3 weeks before visiting gynecologic clinic in March 2010. Physical examination revealed a whole vulvar swelling and about 3-cm-size non-tender masses on bilateral labium majus without a protruding lump. Other external genitalia showed no significant abnormality. No signs or symptoms suggesting inflammation was found. Hematological and biochemical values were within normal range. Pelvic magnetic resonance imaging with contrast revealed fatty masses suggesting lipoma (Fig. 1A) and positron emission tomography/computed tomogra-

phy scan of whole body showed no distant metastasis. We performed surgical resection of bilateral vulvar masses and the masses (Fig. 1B) were about 15 and 20 cm in maximum length respectively. It was not easy to clearly demarcate the tumor and fat tissue around. Both inguinal lymph nodes were not enlarged. Histopathologic exam confirmed the diagnosis of well-differentiated liposarcoma which showed adipocytes of various sizes and lipoblasts (Fig. 1C).

Adjuvant radiotherapy was given because we were not sure the tumor was completely resected. After postoperative recovery, the patient was referred to the radiotherapy department in May 2010. The patient was prescribed a dose of 60 Gy to be delivered in 30 fractions of 2 Gy to the vulvae and pelvis, using 6 MV linear accelerator (linac). Treatment was daily, except for the weekend. At 40 Gy the patient presented with erythema arising within a radiation field of perineum and reported persistent anal pain, so radiotherapy was discontinued. The lesion and symptom resolved after a week, not requiring

Received: 2014.5.2. Revised: 2014.7.11. Accepted: 2014.7.15.

Corresponding author: Nak Woo Lee

Department of Obstetrics and Gynecology, Korea University Ansan Hospital, Korea University College of Medicine, 123 Jeokgeum-ro, Danwon-gu, Ansan 425-707, Korea

Tel: +82-31-412-4801 Fax: +82-31-412-4233

E-mail: nwlee@korea.ac.kr

Articles published in Obstet Gynecol Sci are open-access, distributed under the terms of the Creative Commons Attribution Non-Commercial License (<http://creativecommons.org/licenses/by-nc/3.0/>) which permits unrestricted non-commercial use, distribution, and reproduction in any medium, provided the original work is properly cited.

Copyright © 2014 Korean Society of Obstetrics and Gynecology

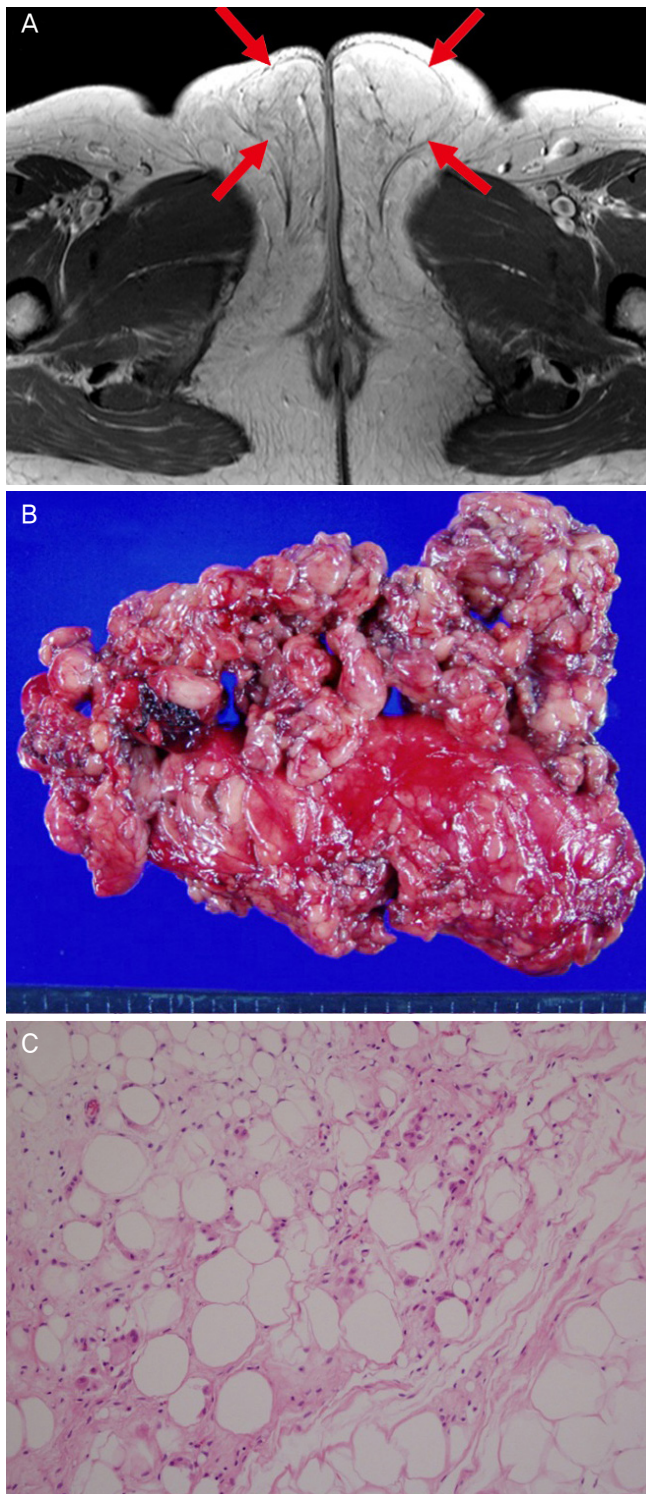


Fig. 1. Radiologic image, gross photo and histopathologic finding of vulvar liposarcoma. (A) Magnetic resonance imaging T1-weighted enhanced image revealed bilateral vulvar masses that show similar signal intensity as surrounding fat tissue without definite enhancement portion. (B) Specimen consists of many irregular adipose tissues. (C) Histologic sections of lipomatous tumor show variable sized adipocytes with atypical myxoid stromal cell (x100).

any intervention. The treatment was restarted with same dose and completed without additional side effects. Neither recurrence nor metastasis has occurred up to 44 months after initial surgical treatment and subsequent radiotherapy.

Discussion

Malignant tumors of the vulva are very unusual and represent less than 5% of gynecologic cancer. The most common histologic type of vulvar cancer is squamous cell carcinoma, accounting for about 95% of all. Vulvar sarcomas are rare, accounting for only 1% to 3% of all vulvar malignancies and the most frequent primary vulvar sarcomas are leiomyosarcomas which usually occurs at the labium majus or Bartholin's gland [11]. Liposarcoma arising in the vulva is extremely uncommon, with 15 cases reported in English literature so far [1-10] and we could find only one case in Korean language literature [12].

Liposarcoma is divided into five subtypes by histologic features: well-differentiated liposarcoma (WDLS), dedifferentiated liposarcoma (DDLs), myxoid liposarcoma (MLS), round cell liposarcoma (RCLS) and pleomorphic liposarcoma (PLS). WDLS is the most common subtype and indolent, low-grade tumor that may recur locally but do not metastasize. Abrupt transition from WDLS to a non-lipogenic sarcoma results in DDLs that is a higher grade lesion with more recurrence, metastatic potential and poor prognosis. MLS is the second most common subtype and considered low-grade and associated with favorable prognosis, especially pure MLS which has no round cell component. RCLS, defined as having $\geq 5\%$ round cell component, is considered a high-grade and more aggressive tumor tends to metastasize. PLS is the least common subtype and a high-grade, aggressive malignant sarcoma that metastasizes early to lung. Histologic subtype is the main prognostic factor regarding clinical outcome. Other factors are the primary site of disease and resection margin status. Liposarcoma arising in the retroperitoneum has higher rates of local recurrence and lower disease-specific survival than liposarcoma arising in the extremity. The treatment of choice of liposarcoma is complete surgical resection. For high-grade lesions or close/positive resection margin, adjuvant radiotherapy may provide benefit effect to control local recurrence [13,14].

The clinical features and managements of all reported cases, including our case have been summarized in Table 1 [1-10,12]. The patients' ages ranged from 15 to 69 years, and the mean age was 43.6 years. The most common histologic subtype is

Table 1. Seventeen cases of vulvar liposarcomas reported in the literature including the present case

Case	Author	Age (yr)	Site	Subtype	Treatment	Follow-up	Outcome
1	Taussig [1]	29	L LM	Unknown	HV	5 mo	Recurrence
2	Gondos et al. [2]	38	L perineum	PLS	WE	8 yr	Recurrence
3	Brooks et al. [3]	15	Perineum	MLS	WE	31 mo	Recurrence
4	Genton et al. [4]	60	L LM	WDLS	LE	10 mo	No R/M
5	Rogers et al. [5]	65	L LM	PLS	LE	Unknown	Unknown
6	Nucci et al. [6]	61	R LM	WDLS	LE	7 yr	No R/M
7	Nucci et al. [6]	44	R LM	WDLS	LE	Unknown	Unknown
8	Nucci et al. [6]	46	R LM	WDLS	LE	1 yr	No R/M
9	Nucci et al. [6]	28	LM	WDLS	LE	14 mo	No R/M
10	Nucci et al. [6]	69	Clitoris	WDLS	LE	18 mo	No R/M
11	Nucci et al. [6]	59	L LM	WDLS	LE	31 mo	Recurrence
12	Yokouchi et al. [7]	21	L LM	WDLS	LE RT	18 mo	No R/M
13	Donnellan et al. [8]	26	L LM	MLS	WE	9 mo	No R/M
14	AshrafGanjooie [9]	65	L LM	WDLS	LE	Unknown	Unknown
15	Wu et al. [10]	45	R LM	MLS	LE	28 mo	Recurrence
16	Baek et al. [12]	33	B LM	MLS	WE	2 yr	No R/M
17	Current case	37	B LM	WDLS	LE RT	44 mo	No R/M

L, left; LM, labium majus; HV, hemivulvectomy; PLS, pleomorphic liposarcoma; WE, wide excision; MLS, myxoid liposarcoma; WDLS, well-differentiated liposarcoma; LE, local excision; R/M, recurrence and/or metastasis; R, right; RT, adjuvant radiotherapy; B, bilateral.

well-differentiated liposarcoma (10 of 17 cases). Clinical diagnosis of almost the whole cases was thought a benign disease such as lipoma. Most initial treatments were surgical excision alone, but adjuvant radiotherapy added to the surgical excision in two of cases including our case. In our case, although histologic subtype was WDLS, adjuvant radiotherapy was added to surgery because negative resection margin was not guaranteed. Of the 17 cases that were followed for 5 months to 8 years, local recurrence was found in five patients; two of four MLSs, one of two PLSs, one of ten WDLSs and one unknown subtype. In the WDLS case, tumor had not been completely removed primarily. The clinical features of cases accord with that of other liposarcoma in general. But it is difficult to come to a conclusion about general character of vulvar liposarcoma due to too small numbers of cases.

In summary, the vulvar liposarcoma is extremely rare case in the world. Therefore, there are no established protocols for diagnosis, clinical course, standard treatment and clinical follow-up. In this case, the primary vulvar liposarcoma was managed by surgical resection with an unclear resection margin and followed by adjuvant radiotherapy because the positive resec-

tion margin is regarded as a poor prognosis factor. Without the standard treatment, we tried adjuvant radiotherapy on vulva which was the first attempt in South Korea and the second worldwide. After the radiotherapy, the patient has been followed up for 44 months with no evidence of local recurrence and metastasis. From her result, despite the rarity of the case, we are optimistic to help to establish the future treatment modality for the vulvar liposarcoma.

Conflict of interest

No potential conflict of interest relevant to this article was reported.

References

1. Taussig FJ. Sarcoma of the vulva. *Am J Obstet Gynecol* 1937;33:1017-26.

2. Gondos B, Casey MJ. Liposarcoma of the perineum. *Gynecol Oncol* 1982;14:133-40.
3. Brooks JJ, LiVolsi VA. Liposarcoma presenting on the vulva. *Am J Obstet Gynecol* 1987;156:73-5.
4. Genton CY, Maroni ES. Vulval liposarcoma. *Arch Gynecol* 1987;240:63-6.
5. Rogers RG, Thorp JM Jr. Liposarcoma of the vulva: a case report. *J Reprod Med* 1995;40:863-4.
6. Nucci MR, Fletcher CD. Liposarcoma (atypical lipomatous tumors) of the vulva: a clinicopathologic study of six cases. *Int J Gynecol Pathol* 1998;17:17-23.
7. Yokouchi J, Negishi Y, Abe K, Shirasawa K, Mernyei M. Radiotherapy for liposarcoma of the vulva. *Gynecol Oncol* 2000;79:315-7.
8. Donnellan R, Moodley M. Vulval myxoid liposarcoma. *Int J Gynecol Cancer* 2001;11:321-2.
9. AshrafGanjooie T. Case report of vulvar liposarcoma. *J Obstet Gynaecol Res* 2004;30:80-3.
10. Wu TC, Tarn JJ. Vulvar myxoid liposarcoma. *Taiwan J Obstet Gynecol* 2007;46:293-4.
11. Behranwala KA, Latifaj B, Blake P, Barton DP, Shepherd JH, Thomas JM. Vulvar soft tissue tumors. *Int J Gynecol Cancer* 2004;14:94-9.
12. Baek JY, Park CS, Joo SH. A case of liposarcoma of the perineum. *Korean J Obstet Gynecol* 2007;50:932-5.
13. Dalal KM, Antonescu CR, Singer S. Diagnosis and management of lipomatous tumors. *J Surg Oncol* 2008;97:298-313.
14. Crago AM, Singer S. Clinical and molecular approaches to well differentiated and dedifferentiated liposarcoma. *Curr Opin Oncol* 2011;23:373-8.