

Laser-guided intraoral radiography: A future focus

Shishir Ram Shetty^{1,*}, Subhas Babu¹, Edwin Varkeyachan²

¹Department of Oral Medicine and Radiology, AB Shetty Memorial Institute of Dental Science, Nitte University, Mangalore, India

²Department of Prosthodontics, AB Shetty Memorial Institute of Dental Science, Nitte University, Mangalore, India

Over the past few decades, rapid changes have taken place in the fields of science and technology. Simultaneously, great progress has been made in research work on laser applications. Today, laser use ranges from simple applications such as recording prices of groceries to complex applications such as measuring distance to the moon and laser-guided warfare.¹ In the field of dentistry, the research and development of laser technology was initiated in the 1960s; since then, it has made significant progress, and today, this technology is being used for a wide variety of clinical applications ranging from surgical (biopsy and frenectomy) to endodontics and conservative dentistry (root canal treatment, tooth whitening, vitality checking, cavity preparations, and reduction of dentinal and hypersensitivity) and from periodontics (gingivectomy and gingivoplasty) to oral medicine (treatment of aphthous and herpetic ulcers).¹⁻³

Perhaps the only specialty of dentistry that has not made optimum use of lasers is oral radiology. Although laser-guided positioning of a patient is routinely performed in panoramic radiography, its application in intraoral radiography has not been researched sufficiently.^{4,5} However, recently, pioneering research work has been carried out in the field of laser-guided collimation in dental radiographic training.^{5,6}

In 2006, Chau et al. designed and fabricated a custom-made collimator with four red laser diodes on each corner of the rim of an aluminum alloy cubic housing.⁵ In their study, 18 dental hygiene students were randomized into test and control groups. The laser group used a rectangular collimator with the laser device, while the non-laser group

used a conventional rectangular collimator. Each group attended nine intraoral radiography training sessions. All radiographs were assessed and classified into three categories - Excellent, Acceptable, and Repeat - by a masked academic staff member. Reasons for repeats were recorded. Statistical comparisons between the two groups were made. They found that a total of 2334 radiographs were taken, and cone-cuts were more common on bitewings than on periapicals. The laser group produced fewer cone-cuts than the non-laser group. The laser group produced more excellent radiographs with fewer repeats than the non-laser group, but there was no significant difference.

Similarly, in 2010, Zamani et al. devised a laser-guided indicator, which was made of two low-power red laser diodes and was capable of generating two perpendicular rays forming a cross (+) in the center of the tube, which indicated a central ray.⁶ In their study, a total of 18 students were divided into two groups of nine. In the first group, the periapical technique was taught without the use of the laser-guided indicator, while in the second group, the laser-guided indicator was applied in training the students. All students took radiographs from the phantom. In total, 216 radiographs were taken, and technical errors and the quality of these radiographs were evaluated. The researchers found that the radiographs taken by students showed significant differences in cone cutting (p value=0.014), overlapping (p value=0.018), and elongation (p value<0.001) between the two study groups. In the subjective review of radiography quality, the difference was also significant (p value<0.001).

The results of the above studies strongly indicated that a laser-guided indicator/collimator could be used as an effective training aid for easier learning of central ray adjustment and reduction of technical errors by dental students. We firmly believe that laser-guided collimators/indicators should be taken up as research topics for inventing more

Received January 20, 2014; Revised March 27, 2014; Accepted April 15, 2014

* Correspondence to: Dr. Shishir Ram Shetty

Department of Oral Medicine and Radiology, AB Shetty Memorial Institute of Dental Science, Nitte University, Mangalore 575018, Karnataka, India
Tel) 91-998-6221047, Fax) 91-824-2204305, E-mail) drshishirshettyomr@yahoo.com

Copyright © 2014 by Korean Academy of Oral and Maxillofacial Radiology

This is an Open Access article distributed under the terms of the Creative Commons Attribution Non-Commercial License (<http://creativecommons.org/licenses/by-nc/3.0>) which permits unrestricted non-commercial use, distribution, and reproduction in any medium, provided the original work is properly cited.

Imaging Science in Dentistry • pISSN 2233-7822 eISSN 2233-7830

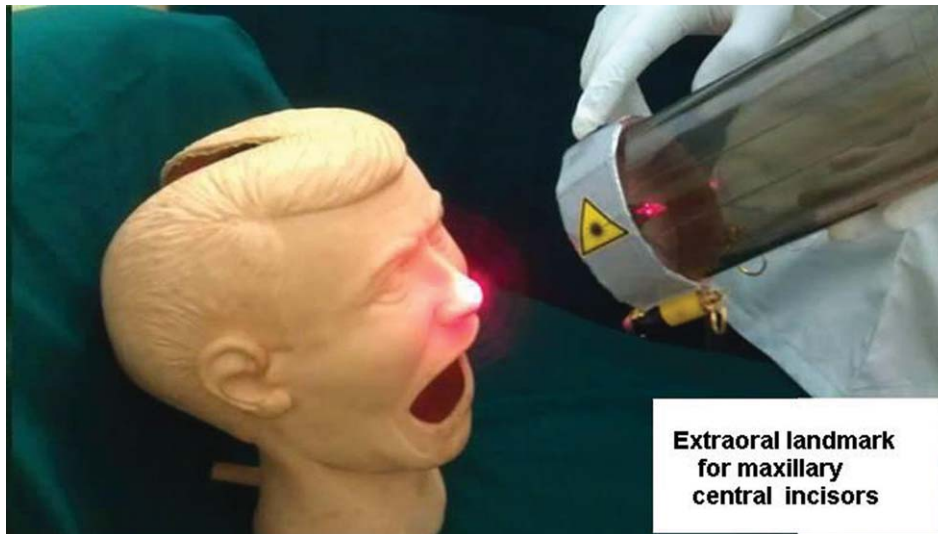


Fig. 1. A photograph shows the Laxmi-Kanth Aiming Device (LKAID) capped to an intraoral unit for demonstrating an extraoral landmark for maxillary central incisors.

such teaching aids. With this background in mind, we developed a laser guide device using a single laser-guided device that could be capped to the intraoral unit so as to make the student aware of the accurate extraoral landmark prior to the radiographic procedure (Fig. 1). The device has been named Laxmi-Kanth Aiming Device (LKAID) after Dr. Laxmikanth Chatra, Professor and Head, Department of Oral Medicine and Radiology, Yenepoya Dental College, Yenepoya University. The device is in its initial trial stages, and the outcomes will be discussed in detail in future articles.

References

1. Stabholz A, Zeltser R, Sela M, Peretz B, Moshonov J, Ziskind D, et al. The use of lasers in dentistry: principles of operation and clinical applications. *Compend Contin Educ Dent* 2003; 24: 935-49.
2. Roper MJ, White JM, Goodis HE, Gekelman D. Two-dimensional changes and surface characteristics from an erbium laser used for root canal preparation. *Lasers Surg Med* 2010; 42: 379-83.
3. de Oliveira Guaré R, Costa SC, Baeder F, de Souza Merli LA, Dos Santos MT. Drug-induced gingival enlargement: biofilm control and surgical therapy with gallium-aluminum-arsenide (GaAlAs) diode laser-A 2-year follow-up. *Spec Care Dentist* 2010; 30: 46-52.
4. Lambert PM, Gorman LM, Karimnamazi H, Kuthy RA. Technique for standardization of panoramic radiographs using helium-neon laser guided positioning. *Implant Dent* 1993; 2: 251-6.
5. Chau AC, Li TK, Wong J. A randomized double blinded study to assess the efficacy of a laser-guided collimator on dental radiography training. *Dentomaxillofac Radiol* 2006; 35: 200-4.
6. Zamani NA, Hekmatian E, Khalili H, Sadeghi HS. Effect of using laser guided indicator on the reduction of technical errors in periapical radiographies prepared by dental students. *J Isfahan Dent Sch* 2010; 6: 173-9.