

A CASE OF PEUTZ-JEGHERS SYNDROME WITH ENDOMETRIAL ADENOMYOMATOUS POLYP

Yoon Hee Lee, MD, Dae Gy Hong, MD, Ji Hae Bae, MD, Nae Yoon Park, MD, Gun Oh Chong, MD, Yoon Soon Lee, MD

Department of Obstetrics and Gynecology, Kyungpook National University Hospital, Kyungpook National University School of Medicine, Daegu, Korea

Peutz-Jeghers syndrome, which has autosomal dominant inheritance, shows pigmentation in lip and skin. It also has features of hamartomatous polyp over the gastrointestinal tract, while sometimes developing tumor in genital tract. Known tumors in female genital tract include cervical adenocarcinoma, sex cord tumor, etc. Adenomyomatous polyp in uterus is also one of the rare diseases, which seldom develop in the absence of hormone treatment such as Tamoxifen. Currently, there is one case of Peutz-Jeghers syndrome patient with endometrial adenomyomatous polyp. Authors found mole-like lesions on the transvaginal ultrasonogram in a typical Peutz-Jeghers syndrome patient without pregnancy history and previous chemotherapy. After confirming its diagnosis of adenomyomatous polyp on resectoscopic biopsy, we report our findings along with brief literature review.

Keywords: Peutz-Jeghers syndrome, Adenomyomatous polyp, Resectoscopy

Peutz-Jeghers syndrome (PJS) is known to have autosomal dominant inheritance and is related to the STK11 gene. The symptoms include dark-colored pigmentation from the lip and buccal mucosa to fingers and to the toes, along with hamartomatous polyp over the entire gastrointestinal tract. Moreover, in addition to gastrointestinal tract, it can cause tumor in breast, genital tract, lung, etc. Known tumors in female genital tract include cervical adenocarcinoma, ovarian sex cord tumor, granulosa cell tumor, etc. adenomyomatous polyp in uterus has stromal component consisting of smooth muscle cells and it occasionally develops among women who received hormonal therapy such as Tamoxifen. It has a feature of mole-like appearance of vesicle pattern on the transvaginal ultrasonogram.

cm was detected in endometrium, with normal β human chorionic gonadotropin level. There were no abnormalities on uterine cervix and both adnexa. Diagnostic uterine curettage was performed, but enough specimen was not taken. There was no malignant cells. Following ultrasonogram assisted resectoscopic polypectomy was performed under general anesthesia after two weeks, where the endometrium was filled with Swiss cheese like lesion. During the follow-up observation period, she visited Division of Gastroenterology to receive endoscopic mucosal resection and colonoscopy. The duodenal polypectomy revealed hamartomatous polyp and hence the patient was diagnosed with PJS. According to the follow-up transvaginal ultrasonogram, the endometrium showed decreased thickness to 1.6 cm, while still being observed as mole-

Case Report

A twenty-eight-year-old female visited our hospital with vaginal spotting for about a month. She did not experience pregnancy and had characteristic dark-colored pigmentation in skin and lip. She has a history of bowel resection seventeen and twelve years ago. She did not remember the reasons of bowel resection. As for Family history, the patient's mother died from cervical cancer. She had no history of previous hormonal therapy, such as Tamoxifen. In a transvaginal ultrasonogram, mole-like lesion with a thickness of 3

Received: 2010. 9.30. Revised: 2010.12.19. Accepted: 2011. 1.31.
Corresponding author: Dae Gy Hong, MD
Department of Obstetrics and Gynecology, Kyungpook National University Hospital, Kyungpook National University School of Medicine, 50 Samdeok-dong 2-ga, Jung-gu, Daegu 700-721, Korea
Tel: +82-10-3058-5947 Fax: +82-53-423-7905
E-mail: chssa0220@hanmail.net

This is an Open Access article distributed under the terms of the Creative Commons Attribution Non-Commercial License (<http://creativecommons.org/licenses/by-nc/3.0/>) which permits unrestricted non-commercial use, distribution, and reproduction in any medium, provided the original work is properly cited.

Copyright © 2011. Korean Society of Obstetrics and Gynecology

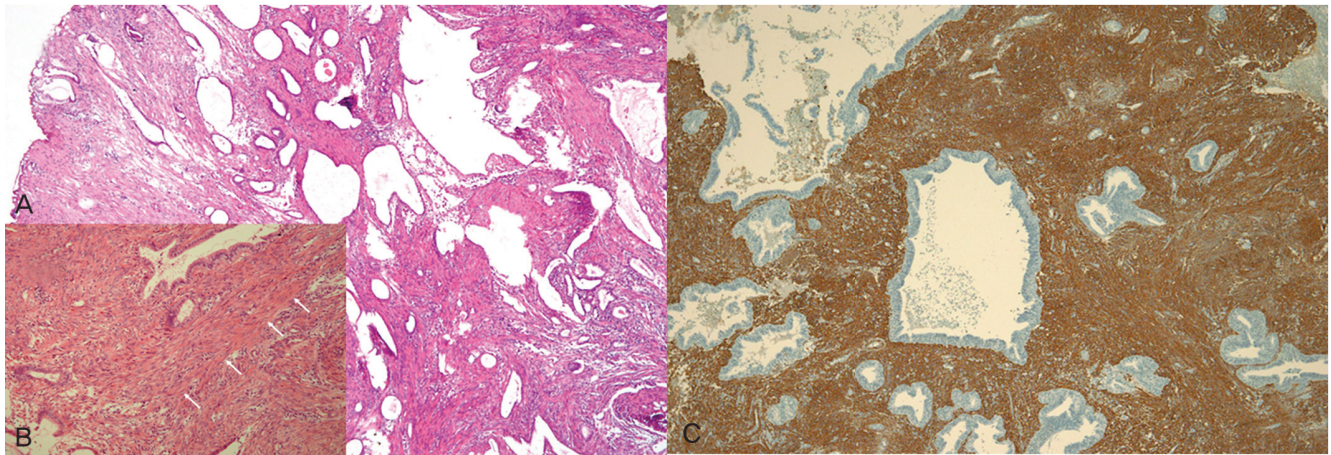


Fig. 1. Adenomyomatous polyps characterized histologically by the intertwining of smooth muscle, endometrial glands and endometrial stroma. (A) The polyp contains many cystically dilated glands and abundant smooth muscle fibers (H&E, $\times 40$). (B) Insert, The white arrows represent smooth muscle fibers in stroma (H&E, $\times 40$). (C) The brown color in stroma reveals positive reactivity upon smooth muscle actin (immunohistochemistry for smooth muscle actin, $\times 40$).

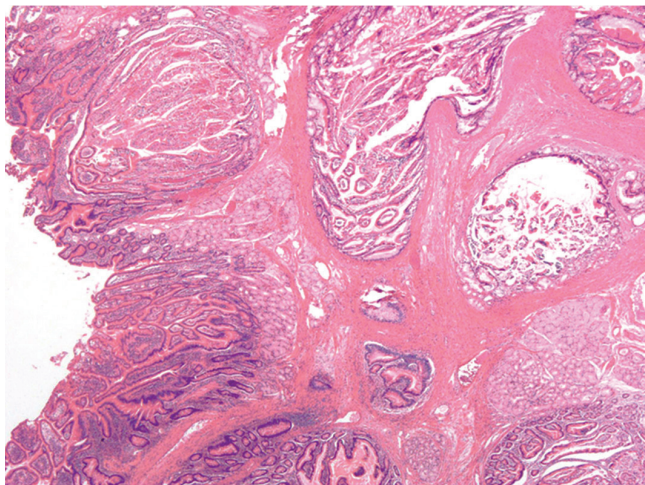


Fig. 2. The polyp resected at the duodenum and resected polyps showed hyperplastic and dilated glands which were compatible with hamartomatous polyp in same patient (H&E, $\times 40$).

like lesion. Two months after performing primary resectoscopy, the secondary resectoscopic polypectomy was performed under general anesthesia. The endometrium was still filled with Swiss cheese like lesion and the diagnosis of adenomyomatous endometrial polyp was confirmed.

The submitted endometrium from the primary curettage and the secondary resectoscopic biopsy showed the similar histologic finding each other. The endometrium revealed several pieces of irregular sized polyps measuring 1.5 \times 1.5 cm of the largest one and aggregating volume was about 20 mL. The polyps were composed of irregularly distributed endometrial glands and prominent bundles of smooth muscle cells in the stroma as well as combined plasma

cells. These bundles of smooth muscle cells were variable in proportion. The endometrial glands revealed cellular proliferation and focal glandular crowding. Also, relatively usual endometrial polyps were present around adenomyomatous polyps (Fig. 1). More than 8 polyps were found at the duodenum and resected polyps showed hyperplastic and dilated glands with intervening smooth muscle bundles which were compatible with hamartomatous polyp (Fig. 2). Two years after surgery, there was no recurrence of symptoms and no thickened uterine endometrium on regular ultrasonographic examination but amenorrhea continued after resectoscopy without menopausal symptoms. Because the patient wants to preserve uterus, even though there are the risk of endometrial cancer, the prophylactic hysterectomy is not performed.

Discussion

This case is considered to be the second endometrial adenomyomatous polyp in patient with PJS on literature review. PJS can cause tumor in genital tract in addition to gastrointestinal tract, which is often precancerous. It is known that the occurrence of such cancer is fifteen times more likely compared to the general population. Even though gynecologic neoplasms related to PJS include cervical adenocarcinoma, endometrial cancer, epithelial ovarian tumor, sex cord stromal ovarian tumor, etc., specific occurrence rate is unknown [1-3].

Endometrial polyp is frequent lesion in uterus, which shows histologically focal hyperplasia of basalis with a localized overgrowth of gland, stroma, and blood vessels. Adenomyomatous polyp has

an overgrowth of benign smooth muscle cell as a component of endometrial polyp. The incidence is known to be very low, with its 1.3% proportion of polyp lesion [4].

Nasu et al. [5] reported nine cases of adenomyomatous polyp which showed abnormal uterine bleeding and dysmenorrhea in 1994. Five among them received hysterectomy, while the remaining four received polypectomy. All the polypoid lesion showed the composition of smooth muscle cell and endometrial gland, while no atypia was observed. Meanwhile, the adenomyomatous polyp is known to be related to the hormonal therapy such as Tamoxifen. Takeuchi et al. [6] reported a patient who after tamoxifen treatment, had heterogenous hyperechoic mass in uterus. The lesion revealed adenomyomatous polyp with small cystic lesion after hysterectomy. According to de Brux [7] it is still unsolved question whether the adenomyomatous polyp is a variant of adenomyosis, endometriosis or a truly neoplastic one. According to Silverberg and Kurman [8] adenomyomatous polyp is hamartomatous and one of the variants of adenomyosis. As a supporting evidence, Nasu et al. [5] reported that the smooth muscle cell element, one of the histological features of adenomyomatous polyp, arise in myometrium. Transvaginal ultrasonogram can be used in diagnosing adenomyomatous polyp. In this case typical mole-like appearance was observed. Furuhashi et al. [9] reported a case of adenomyomatous polyp showing vesicle pattern similar to hydatidiform mole. Treatment includes polypectomy and hysterectomy with purpose of improving symptoms or preserving fertility. Hertig and Gore reported that adenomyomatous polyp usually develops among infertile young patients [10]. However, only one out of nine was nulligravida in a case reported by Nasu et al. [5]. It is also possible that adenomyomatous polyp in PJS is one of the manifestations similar to hamartomatous polyp in gastrointestinal tract. Even though atypia is not observed histologically in case of adenomyomatous polyp, there are reports of endometrial cancer in PJS. Hence, close follow-up for the cancerous condition in genital

tract is required.

In conclusion, the adenomyomatous polyp in PJS is very rare disease and this lesion may be related with hamartomatous lesion which occurs in PJS.

References

1. Chen KT. Female genital tract tumors in Peutz-Jeghers syndrome. *Hum Pathol* 1986;17:858-61.
2. Giardiello FM, Brensinger JD, Tersmette AC, Goodman SN, Petersen GM, Booker SV, et al. Very high risk of cancer in familial Peutz-Jeghers syndrome. *Gastroenterology* 2000;119:1447-53.
3. Sato H, Nanjo H, Tanaka H, Tanaka T. Arias-Stella reaction in an adenomyomatous polyp of the uterus. *Acta Obstet Gynecol Scand* 2007;86:106-8.
4. Peterson WF, Novak ER. Endometrial polyps. *Obstet Gynecol* 1956;8:40-9.
5. Nasu K, Sugano T, Miyakawa I. Adenomyomatous polyp of the uterus. *Int J Gynaecol Obstet* 1995;48:319-21.
6. Takeuchi M, Matsuzaki K, Uehara H, Shimazu H, Nishitani H. A case of adenomyomatous polyp of the uterus associated with tamoxifen therapy. *Radiat Med* 2005;23:432-4.
7. De Brux J. *Histopathologie gynecologique*. Paris: Masson; 1971.
8. Silverberg SG, Kurman RJ, editors. *Atlas of tumor pathology*. 3rd ed. Washington, DC: Armed Forces Institute of Pathology; 1992.
9. Furuhashi M, Miyabe Y, Oda H. Adenomyomatous polyp mimicking hydatidiform mole on ultrasonography. *Arch Gynecol Obstet* 2000;263:198-200.
10. Firminger HI. *Atlas of tumor pathology*. Washington, DC: Armed Forces Institute of Pathology; 1968.

자궁내막 샘근육종 폴립을 동반한 Peutz-Jeghers 증후군 1예

경북대학교 의과대학 경북대학교병원 산부인과

이윤희, 홍대기, 배지혜, 박내운, 정근오, 이윤순

Peutz-Jeghers 증후군은 보통염색체 우성유전을 보이며, 입술과 피부에 색소침착을 보인다. 또한 위장관 전반에 걸친 과오종성 용종이 특징적이나, 때때로 여성 생식기에 종양이 동반되기도 한다. Peutz-Jeghers 증후군에 동반된 여성 생식기 종양으로는 자궁경부의 샘암종, 성끈종양 등이 있다. 자궁의 샘근육종 폴립은 드문 질환으로 타목시펜과 같은 호르몬 치료 없이는 거의 발생하지 않는다. 최근에 저자들은 자궁내막 샘근육종 폴립을 동반한 Peutz-Jeghers 증후군 환자 1예를 경험하였다. 환자는 불임 여성으로 항암화학요법 경험이 없었고 질식 초음파검사서 기태 유사 병변을 보였다. 자궁절제경하 조직검사를 통해 샘근육종 폴립으로 확진하였기에 간단한 문헌 고찰과 더불어 증례를 보고하는 바이다.

중심단어: Peutz-Jeghers 증후군, 샘근육종 폴립, 자궁절제경