



The Effectiveness of Pelvic Arterial Embolization for Intractable Postpartum Hemorrhage after Hysterectomy

자궁 적출술 후에도 지속되는 산후 출혈에 대한
골반 동맥 색전술의 유용성

Jae Myeong Lee, MD , Jai Soung Park, MD* , Jong Joon Shim, MD

Department of Radiology, Soonchunhyang University Hospital, Bucheon, Korea

Purpose To evaluate the effectiveness of pelvic arterial embolization (PAE) for intractable postpartum hemorrhage (PPH) after hysterectomy.

Materials and Methods From March 2011 to December 2017, 14 patients who received PAE for PPH that persisted after total abdominal hysterectomy were included (mean age, 33.6 years; range, 26–37 years). The delivery type, cause of PPH, and angiographic findings were investigated. The technical and clinical success rates and clinical outcomes were evaluated.

Results Of 14 patients, 8 patients (57%) had positive angiographic findings for bleeding; contrast extravasation ($n = 6$), and pseudoaneurysm ($n = 2$). Remnant uterine artery (UA) was the most common bleeding focus ($n = 4$), followed by vaginal artery ($n = 2$), left lateral sacral artery ($n = 1$), and left internal pudendal artery ($n = 1$). Technical and clinical success rates were 100% and 93% (13/14), respectively. In 1 patient, bleeding was not controlled after initial selective embolization and the entire anterior divisions of both internal iliac arteries were embolized with gelfoam.

Conclusion PAE for persistent PPH after hysterectomy is a safe and effective treatment. Remnant UA was the most common bleeding site and all patients recovered without any significant sequelae after embolization.

Index terms Uterine Artery; Hysterectomy; Embolization, Therapeutic

Received July 12, 2018
Revised September 18, 2018
Accepted September 20, 2018

***Corresponding author**

Jai Soung Park, MD
Department of Radiology,
Soonchunhyang University
Hospital, 170 Jomaru-ro,
Bucheon 14584, Korea.

Tel 82-32-621-5866
Fax 82-32-621-5860
E-mail jspark@schmc.ac.kr

This is an Open Access article distributed under the terms of the Creative Commons Attribution Non-Commercial License (<https://creativecommons.org/licenses/by-nc/4.0/>) which permits unrestricted non-commercial use, distribution, and reproduction in any medium, provided the original work is properly cited.

ORCID iDs

Jai Soung Park
<https://orcid.org/0000-0003-0382-0605>
Jae Myeong Lee
<https://orcid.org/0000-0003-4094-5239>

INTRODUCTION

Postpartum hemorrhage (PPH) accounts for 25% of maternal deaths worldwide and is

a major cause of emergency hysterectomy (1, 2). Traditional management includes uterine massage, uterine packing, and uterotonic agent administration. If these treatments are not effective, pelvic artery ligation, balloon tamponade, hysterectomy, and transarterial embolization (TAE) are performed (2, 3).

Since the introduction of TAE as a treatment for PPH in 1979, it has been shown to have a high success rate and low complication rate in many reports (2, 4, 5). Recently, it has been applied to PPH for genital tract laceration, retained or invasive placenta, and uterine atony (3).

Nevertheless, the treatment guideline for refractory PPH differs for each hospital and country, and most of the decisions about pelvic arterial embolization (PAE) are made by obstetricians (2, 6). Therefore, surgical treatment, such as hysterectomy, is performed in many cases according to the patient's condition. However, some bleeding may persist after surgery, and TAE may be required. Nevertheless, the efficacy of TAE to manage persistent bleeding after hysterectomy have not been well documented, because there have been only a few published case reports (7-9).

The purpose of this study was to evaluate the safety and efficacy of pelvic artery embolization for persistent PPH after hysterectomy.

MATERIAL AND METHODS

PATIENTS

Our Institutional Review Board approved this study, and patient informed consent was waived (SCHBC 2018-06-025). From March 2011 to December 2017, among patients who underwent total abdominal hysterectomy because of PPH, TAE was performed in 14 patients (mean age, 33.6 years; range, 26–37 years) who had persistent bleeding. Patients characteristics, including delivery type, operation findings, and angiography findings are summarized in Table 1. Thirteen of the 14 patients were transferred from outside hospitals, and one was

Table 1. Patient Characteristics

No.	Age (years)	Delivery Type	OP Finding	Hb (g/dL)	Angiographic Findings	Embolic Materials
1	35	Vaginal	Atony	8.9	Extravasation, remnant left UA	Coil
2	34	Cesarean	Atony, vaginal laceration	5.5	Extravasation, right vaginal artery	Coil
3	26	Vaginal	Uterine rupture	6.1	Pseudoaneurysm, left lateral sacral artery	Coil
4	34	Cesarean	Atony	7.7	Extravasation, right vaginal artery	Coil
5	36	Vaginal	Atony, vaginal laceration	7.8	Extravasation, left internal pudendal artery	Coil
6	37	Vaginal	Right UA rupture	5.1	No contrast leakage, collapsed both IIA	Gelfoam
7	37	Vaginal	Both UA rupture	4.9	No contrast leakage, collapsed both IIA	Gelfoam
8	36	Vaginal	Uterine rupture	4.8	Pseudoaneurysm, remnant both UA	Coil
9	35	Vaginal	Atony	7.8	No contrast leakage, remnant both UA	PVA
10	34	Cesarean	Retained placenta	6.5	Extravasation, remnant left UA	Coil
11	34	Cesarean	Placenta accreta	8.7	No contrast leakage, remnant both UA	PVA
12	37	Vaginal	Atony	9.5	No contrast leakage, remnant both UA	PVA
13	27	Vaginal	Atony	6.0	No contrast leakage, remnant both UA	PVA
14	29	Vaginal	Uterine rupture	7.1	Extravasation, remnant both UA	Coil

Hb = hemoglobin, IIA = internal iliac artery, OP Finding = operation finding, PVA = polyvinyl alcohol, UA = uterine artery

from our hospital. Vaginal delivery was performed for 10 patients (10/14, 71%) and cesarean section was performed for 4 patients (4/14, 29%).

The most common cause of PPH was uterine atony (7/14, 50%), followed by uterine rupture ($n = 3$), retained placenta ($n = 2$), and uterine artery (UA) rupture ($n = 2$), was confirmed by surgical findings after hysterectomy.

The hemoglobin (Hb) level just before embolization ranged from 4.8 to 8.9 g/dL, with a mean of 6.9 g/dL. Transfusion of pack RBC before and after the procedure was done for all patients.

EMBOLIZATION TECHNIQUE

A 5 Fr. sheath was inserted through the right common femoral artery, A bilateral iliac artery angiogram was performed to identify the presence of residual UA and bleeding site using a Cobra catheter (Cook Medical, Bloomington, IN, USA). The 2.2 Fr. microcatheter (Progreat; Terumo, Tokyo, Japan) was coaxially introduced to access the source of bleeding, and selective arterial embolization was performed. When there was evidence of active bleeding, such as contrast extravasation or pseudoaneurysm, selective embolization was performed using a pushable microcoil (Tornado; Cook Medical) or a detachable microcoil (Interlock; Boston Scientific, Cork, Ireland).

If active bleeding was not visualized, embolization was performed in two ways. When a UA remained, embolization was performed using polyvinyl alcohol (PVA) particles for remaining UA. If the remaining UA was not visible (e.g., vasoconstriction because of hypovolemia), embolization of the anterior division of both internal iliac arteries (IIA) was performed. In this case, gelatin sponge particles (Spongostan; Johnson & Johnson, Gauteng, South Africa) were used as the embolic material.

After embolization, both iliac angiograms and lower abdominal aortograms were performed to check for residual bleeding focus.

DEFINITION OR ANALYSIS

The technical and clinical success rates were evaluated. Technical success was defined as no extravasation of contrast media or as cessation of vaginal bleeding on speculum examination. The clinical success was defined as clinical improvement and no need for further management, such as additional surgery or additional embolization.

RESULTS

Among the 14 patients, 8 patients (57%) had a bleeding focus on angiography, with contrast extravasation ($n = 6$) and pseudoaneurysm ($n = 2$). Remnant UA was the most common bleeding focus ($n = 4$), followed by vaginal artery ($n = 2$), left lateral sacral artery ($n = 1$), and left internal pudendal artery ($n = 1$).

When the bleeding focus was clear, selective embolization was performed using microcoils ($n = 8$) (Fig. 1). Among 6 patients with no active bleeding in the angiography, the UA stump could be identified in 4 patients and embolization was performed with PVA particles. In the remaining 2 patients, active bleeding was not seen, but the vessels had collapsed with severe

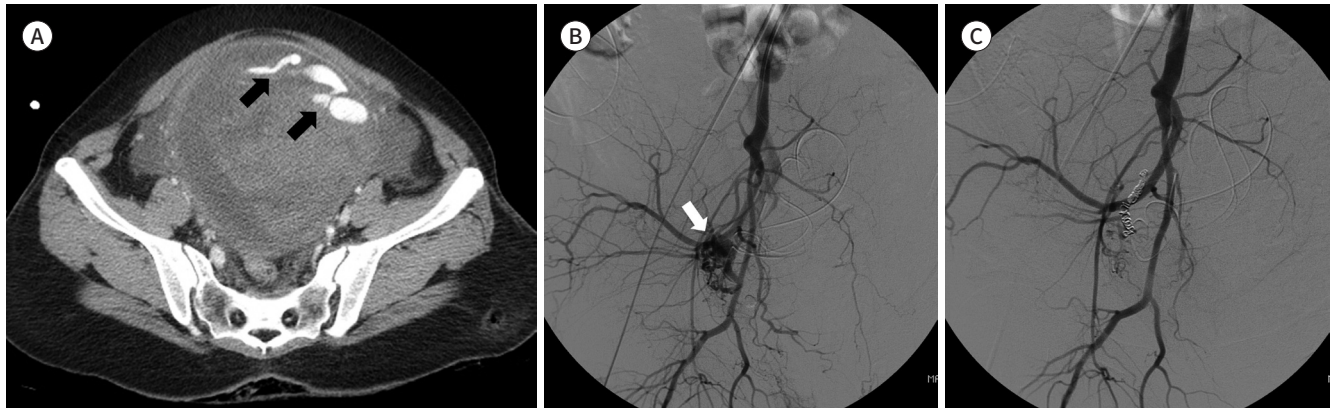
Fig. 1. A 36-year-old female patient (no. 8) with active bleeding and hemodynamic instability.

A. Contrast-enhanced CT performed at admission shows active contrast leakage (arrows) into the uterus and hematoma inside the uterus.

B. The right iliac angiogram shows a remnant right UA and pseudoaneurysm at its distal portion (arrow). The remnant left UA is seen on the left side, but there is no active bleeding (not shown).

C. After the embolization of the remnant right UA, the pseudoaneurysm on the angiogram disappears. PVA embolization was performed on the left UA.

PVA = polyvinyl alcohol, UA = uterine artery



hypovolemia accompanied by coagulopathy (no. 6 and 7). These patients underwent embolization of the anterior division of both IIA. Technical success was achieved in all 14 patients.

Clinical success was achieved in 13 patients (13/14, 93%). One patient (no. 3) with clinical failure had coil embolization because of a pseudoaneurysm in the left lateral sacral artery, but recurrent vaginal bleeding was seen the following day. Follow-up angiogram showed no bleeding focus, but Hb reduction and coagulopathy were observed despite continuous transfusion, and gelfoam embolization was performed on both IIA anterior divisions (Fig. 2). No procedural complications were observed in any of the patients.

DISCUSSION

Primary PPH is defined as a blood loss of more than 500 mL in 24 hr for vaginal delivery and 1000 mL for cesarean delivery, with an incidence of 5–15% (6). The most common cause of primary PPH is uterine atony. Other causes include trauma, such as vaginal or cervical laceration, invasive placentation, coagulopathy, and uterine rupture (2, 3).

According to four national guidelines, eight surgical techniques for PPH that does not respond to medical treatment are uterine packing, balloon tamponade, uterine curettage UA ligation, brace suture, hypogastric artery ligation, arterial embolization, and hysterectomy (6).

Since the introduction of TAE as a treatment for PPH in 1979, it has been shown to have a high success rate and low complication rate in many reports (2, 4, 5). However, patients with hemodynamically unstable or coagulopathy have a relatively low success rate (2, 10, 11).

According to the American College of Obstetricians and Gynecologists guideline, the UAE is considered to be suitable for hemodynamically stable and persistent slow bleeding and failed less invasive therapy (12). Although hysterectomy is the most invasive and the last resort, bleeding may persist even after hysterectomy. Several case studies have reported the embolization of ovarian, vaginal, and inferior epigastric arteries as bleeding sites (7-9).

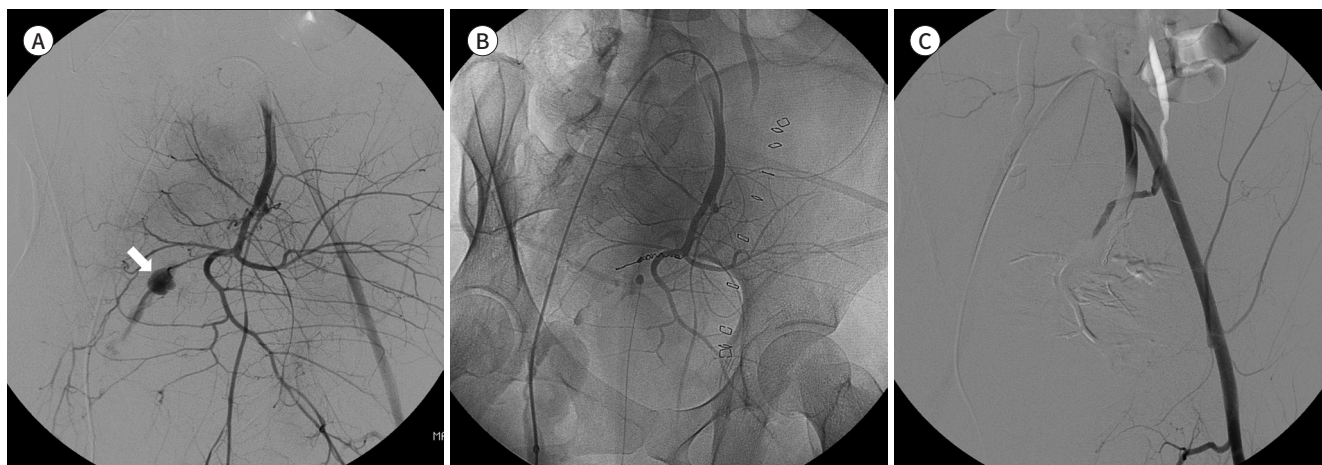
Fig. 2. A 26-year-old patient (no. 3) with persistent bleeding after coil embolization.

A. The left IIA angiogram shows a small pseudoaneurysm (arrow) with contrast leakage in the lateral sacral artery.

B. After coil embolization, the pseudoaneurysm has disappeared.

C. On the next day, left iliac artery angiogram was done because of persistent vaginal bleeding. There is no active bleeding or visualized pseudoaneurysm on the angiogram. Gelfoam embolization was performed on the anterior division of the bilateral IIA.

IIA = internal iliac artery



Several studies have reported embolization after a failed surgical procedure, but most of them are mixed with other operations (e.g., hysterectomy, arterial ligation of a uterine or hypogastric artery, or stepwise uterine devascularization) and few have reported embolization cases after hysterectomy (2, 10, 13). In addition, angiographic findings or embolic materials in embolization have been mentioned in only a few case studies.

Among the 14 patients in our study, 8 patients showed contrast leakage or pseudoaneurysm, suggesting active bleeding on angiography. All of them were embolized using microcoils. Coils are not suitable for embolization of PPH, because of the possibility of proximal embolization and persistent bleeding from collaterals (4). However, in our patients, there was no possibility of collaterals through the uterus because of the previous hysterectomy, and active bleeding was clear. N-butyl-2-cyanoacrylate was not used for the UA stump, because it was short, and the possibility of reflux was high.

Gelatin sponge is the most commonly used transient embolic material in PPH patients and was used in only two cases (no. 6 and 7) in our study. In these patients, active bleeding was not evident, but the vessels were collapsed by severe hypovolemia, and the iliac artery branches were not seen. Therefore, embolization of the anterior division of both IIA was performed, and gelfoam was used to avoid complications after the procedure. When remnants of both UA were seen without active bleeding, PVA particles were used instead of gelfoam for UA embolization.

Our study has several limitations. The first limitation of our study was its retrospective design. The second limitation was that the sample size is too small to find any statistical significance. The third limitation was that the indication of postoperative embolization was not clear. Embolization was done after discussion with the obstetrician about postoperative patient condition, amount of bleeding, and lab findings.

In conclusion, our single-center study confirms that PAE for persistent PPH after a hysterectomy is a safe and effective treatment. Remnant UA was the most representative bleeding

focus and recovered without major complications after embolization.

Conflicts of Interest

The authors have no potential conflicts of interest to disclose.

REFERENCES

1. Al-Zirqi I, Vangen S, Forsen L, Stray-Pedersen B. Prevalence and risk factors of severe obstetric haemorrhage. *BJOG* 2008;115:1265-1272
2. Lee HY, Shin JH, Kim J, Yoon HK, Ko GY, Won HS, et al. Primary postpartum hemorrhage: outcome of pelvic arterial embolization in 251 patients at a single institution. *Radiology* 2012;264:903-909
3. Soyer P, Dohan A, Dautry R, Guerrache Y, Ricbourg A, Gayat E, et al. Transcatheter arterial embolization for postpartum hemorrhage: indications, technique, results, and complications. *Cardiovasc Intervent Radiol* 2015;38:1068-1081
4. Gonsalves M, Belli A. The role of interventional radiology in obstetric hemorrhage. *Cardiovasc Intervent Radiol* 2010;33:887-895
5. Deux JF, Bazot M, Le Blanche AF, Tassart M, Khalil A, Berkane N, et al. Is selective embolization of uterine arteries a safe alternative to hysterectomy in patients with postpartum hemorrhage? *AJR Am J Roentgenol* 2001;177:145-149
6. Dahlke JD, Mendez-Figueroa H, Maggio L, Hauspurg AK, Sperling JD, Chauhan SP, et al. Prevention and management of postpartum hemorrhage: a comparison of 4 national guidelines. *Am J Obstet Gynecol* 2015; 213:76.e1-76.e10
7. Oei PL, Chua S, Tan L, Ratnam SS, Arulkumaran S. Arterial embolization for bleeding following hysterectomy for intractable postpartum hemorrhage. *Int J Gynaecol Obstet* 1998;62:83-86
8. Collins CD, Jackson JE. Pelvic arterial embolization following hysterectomy and bilateral internal iliac artery ligation for intractable primary post partum haemorrhage. *Clin Radiol* 1995;50:710-713; discussion 713-714
9. Naydich M, Friedman A, Aaron G, Silberzweig J. Arterial embolization of vaginal arterial branches for severe postpartum hemorrhage despite hysterectomy. *J Vasc Interv Radiol* 2007;18:1047-1050
10. Sentilhes L, Gromez A, Clavier E, Resch B, Verspyck E, Marpeau L. Predictors of failed pelvic arterial embolization for severe postpartum hemorrhage. *Obstet Gynecol* 2009;113:992-999
11. Touboul C, Badiou W, Saada J, Pelage JP, Payen D, Vicaut E, et al. Efficacy of selective arterial embolisation for the treatment of life-threatening post-partum haemorrhage in a large population. *PLoS One* 2008;3: e3819
12. Committee on Practice Bulletins-Obstetrics. Practice bulletin no. 183: postpartum hemorrhage. *Obstet Gynecol* 2017;130:e168-e186
13. Fargeaudou Y, Morel O, Soyer P, Gayat E, Sirol M, Boudiaf M, et al. Persistent postpartum haemorrhage after failed arterial ligation: value of pelvic embolisation. *Eur Radiol* 2010;20:1777-1785

자궁 적출술 후에도 지속되는 산후 출혈에 대한 골반 동맥 색전술의 유용성

이재명 · 박재성* · 심종준

목적 자궁 적출술 후에도 지속되는 산후 출혈에 대한 골반 동맥 색전술의 효과를 평가하고자 하였다.

대상과 방법 2011년 3월부터 2017년 12월까지 중증 산후 출혈에 대한 치료로 복식 자궁 적출술(total abdominal hysterectomy) 후 지속적 출혈로 인해 골반 동맥 색전술을 받은 14명의 환자를 대상으로 하였다(평균 연령 33.6세, 범위 26~37세). 출산 유형, 산후 출혈의 원인 및 혈관 조영술 소견을 조사하였다. 기술 및 임상 성공률 및 임상 결과를 평가하였다.

결과 혈관 조영술에서 출혈 소견이 있었던 환자는 총 8명(8/14, 57%)이었고 그중 6명은 혈관 외 조영제 누출 소견을, 2명은 가성동맥류 소견을 보였다. 남아있는 자궁 동맥이 가장 흔한 출혈 부위였고(4명), 다음으로 질동맥(vaginal artery)이 2명, 왼쪽 외측천골동맥(left lateral sacral artery)이 1명, 왼쪽 내음부동맥(left internal pudendal artery)이 1명이었다. 기술적 및 임상적 성공률은 각각 100%와 93%(13/14)였다. 색전술 후 출혈이 지속되었던 한 명의 환자에서 gelfoam을 사용하여 양쪽 장골 동맥의 전방분지를 색전 후 성공적으로 지혈되었다.

결론 자궁 적출술 후 지속되는 산후 출혈에 대한 골반 동맥 색전술은 안전하고 효과적인 치료법이다. 남아있는 자궁 동맥은 가장 흔한 출혈 부위이며 색전술 후 심각한 후유증 없이 회복되었다.

순천향대학교 부천병원 영상의학과