



# Assessment of Maxillary Sinus Wall Thickness with Paranasal Sinus Digital Tomosynthesis and CT

## 부비동 디지털 토모신테시스와 컴퓨터단층촬영을 이용한 상악동 벽 두께의 평가

Jieun Byun, MD<sup>1</sup>, Sung Shine Shim, MD<sup>1\*</sup>, Yookyung Kim, MD<sup>1</sup>, Kyoung Ae Kong, MD<sup>2</sup>

Department of <sup>1</sup>Radiology, <sup>2</sup>Clinical Trial Center, Mokdong Hospital, Ewha Womans University School of Medicine, Seoul, Korea

**Purpose:** This study was performed to compare paranasal sinus tomosynthesis with computed tomography (CT) imaging as a radiologic tool to evaluate the paranasal sinuses, using measurement of the soft tissue thickness of the maxillary sinus.

**Materials and Methods:** A total of 114 patients with sinusitis who underwent both paranasal sinus digital tomosynthesis (DT) and CT were enrolled in this retrospective study. Two observers independently assessed soft tissue thickness in both maxillary sinus chambers using both DT and CT images.

**Results:** The mean difference in soft tissue thickness measured by each observer was -0.31 mm on CT and 0.15 mm on DT. The mean differences in soft tissue thickness measured with DT and CT were -0.15 by observer 1 and -0.31 by observer 2. Evaluation of the agreement in measurement of soft tissue thickness in the maxillary sinus using DT and CT showed a high intraclass correlation, with the 95% limit of agreement ranging from -3.36 mm to 3.06 mm [intraclass correlation coefficient (ICC), 0.994:  $p < 0.01$ ] for observer 1 and from -5.56 mm to 4.95 mm (ICC, 0.984:  $p < 0.01$ ) for observer 2.

**Conclusion:** As an imaging tool, DT is comparable to CT for assessing the soft tissue thickness of maxillary sinuses in patients with sinusitis.

### Index terms

Radiography  
Maxillary Sinus  
Sinusitis  
Tomography  
Radiation Dosage

Received May 31, 2016

Revised July 28, 2016

Accepted September 3, 2016

\*Corresponding author: Sung Shine Shim, MD

Department of Radiology, Mokdong Hospital,  
Ewha Womans University School of Medicine,  
1071 Anyangcheon-ro, Yangcheon-gu,  
Seoul 07985, Korea.  
Tel. 82-2-2650-5380 Fax. 82-2-2653-8891  
E-mail: sinisim@ewha.ac.kr

This is an Open Access article distributed under the terms of the Creative Commons Attribution Non-Commercial License (<http://creativecommons.org/licenses/by-nc/4.0>) which permits unrestricted non-commercial use, distribution, and reproduction in any medium, provided the original work is properly cited.

## INTRODUCTION

Sinusitis is an inflammation of the mucosal layers of the paranasal sinuses (PNS). Obstruction of the draining pathways, such as the ostiomeatal complex or the sphenoethmoidal recess of the sinuses, is thought to be the main cause of sinusitis (1-4). The diagnosis of sinusitis is made by evaluation of the patient's history and physical examination. Imaging studies may also be useful. Imaging findings suggestive of sinusitis include the presence of mucosal thickening, opacification, or a mass within the sinus cavities and associated bony erosion or sclerosis. Also, the radiol-

ogist should search carefully for potential causes and complications of sinus disease, such as an obstructing tumor and spread of infection to the orbits, brain, or bone (5).

Plain radiography is frequently used initially in patients with suspected sinusitis; however, the reliability of plain radiograph findings has been questioned. Even experienced radiologists have difficulty in interpreting these images correctly, particularly in judging whether or not mucosal thickening is present and whether or not the ethmoid and sphenoid sinuses are inflamed (6).

Multidetector computed tomography (MDCT) demonstrates high image quality and provides much more detailed informa-

tion about the anatomy and abnormalities of the PNS. The coronal view is particularly beneficial in reflecting the findings of sinus surgery because the anatomy and pathology are visualized in a plane almost identical to that seen by endoscopy. For these reasons, MDCT has become an important component of the preoperative work-up for sinus surgery. However, the radiation delivered to the patient, especially to the radiosensitive organs, such as the lens of the eye, is a significant risk that should be taken into consideration.

Digital tomosynthesis (DT) is a form of limited-angle computed tomography that allows for reconstruction of multiple section images from a set of projection data acquired over a limited range of X-ray tube angles (7). Several studies have begun to address the technical, ergonomic, and performance issues associated with DT. These studies have shown that the image quality of DT is comparable to that of other standard imaging modalities in breast, bone, and chest sections (8-12). In a field of PNS sections, DT can easily and promptly provide sinus coronal tomographic images with high in-plane spatial resolution and is able to remove overlying structures, enhance local tissue separation, and provide depth information. According to a phantom study by Machida et al. (13), the DT doses for the thyroid gland, brain, submandibular gland, skin, and eyes were lower than the doses of MDCT with values of  $230 \pm 90$ ,  $1770 \pm 560$ ,  $1400 \pm 80$ ,  $1160 \pm 2100$ , and  $112 \pm 6$   $\mu$ Gy, respectively.

With respect to the diagnosis of sinus diseases, there have been relatively few studies to date that have employed DT. A study by Yoo et al. (14) compared DT with plain radiography for the detection of sinusitis and investigated the diagnostic accuracy of DT sinus radiography for detecting sinus opacification (13, 15). In the current study, we performed a comparative examination of digital DT and computed tomography (CT) as a radiologic tool to evaluate the PNS, using measurement of the soft tissue thickness of the maxillary sinus.

## MATERIALS AND METHODS

### Patients

From April 2013 to January 2015, a total of 311 PNS DT and PNS CT imaging studies for the assessment of sinusitis were included from our hospital database. This study was approved by our Institutional Review Board, and the requirement for obtain-

ing written informed consent was waived. Of these patients, 174 patients were excluded due to a prolonged time interval between the two modalities. Twenty-three patients who had an air-fluid level in the maxillary sinuses on PNS DT were also excluded because accurate measurement of the maximum soft tissue thickness of the maxillary sinus is theoretically limited in these cases. Finally, 114 patients with 228 maxillary sinuses were included in this study according to the following inclusion criteria: 1) adequate PNS DT and PNS MDCT without an artifact or air-fluid levels in the maxillary sinuses; 2) PNS DT and PNS MDCT were performed on the same day.

### Image Acquisition

#### MDCT

We used a 16- or 64-detector CT scanner (Somatom<sup>®</sup> Sensation scanner; siemens Healthcare, Forchheim, Germany). All of the patients were positioned supine on the bed at the isocenter of the gantry with the neck extended posteriorly for an X-ray projection tilted 10 degrees to the line between the infraorbital margin and the upper margin of the external auditory meatus (Reid's base line) in the z-direction. We performed the scan from the top of the frontal sinuses to just below the mandible in the z-direction and from the face to the external auditory canal in the y-direction. The scanning parameters were as follows: individual detector width, 0.625 mm; tube voltage, 120 kVp or 200 kVp; tube current, 150 mA or 120 mA; and pitch, 0.7. Dose length product (DLP) was recorded. The average effective dose (ED) for PNS CT was 922.02  $\mu$ Sv (range: 310.2  $\mu$ Sv to 1419  $\mu$ Sv) using a DLP to ED conversion factor of 2.2  $\mu$ Sv/(mGy-cm) (16).

We obtained 3 mm thick reconstructed coronal images from 3 mm thick and 3 mm interval axial images with a perpendicular angle. Thus, the reconstructed coronal images were 110 degrees with respect to the Reid's base line. Reconstructed coronal images were taken from the anterior wall of the frontal sinus to the posterior margins of the sphenoid sinus.

#### DT

Tomosynthesis examinations were conducted using a commercially available unit (Sonialvision Safire II; Shimadzu Co., Kyoto, Japan) with a flat-panel detector system. We performed a DT radiography scan covering the frontal to maxillary sinus with

multiple posterior-anterior projection views of all patients in the upright position using the following scan parameters: tube voltage, 75 kVp; tube current-time product per projection, 2.2 mAs; scan time, 6.4 s; sweep angle, 40 degrees. We reconstructed DT coronal images with a slice interval of 2 mm. Gomi (17) reported on using the same device and scan parameters with the exception of a tube voltage of 80 kVp and tube current-time product per projection of 3.5 mAs with an effective DT dose of 240  $\mu$ Sv. Thus, the ED with our scan parameters was less than 240  $\mu$ Sv.

### Image Assessment

Image assessment was performed by two readers with 20 and 4 years of experience in interpreting PNS images. The two readers independently measured the maximum thickness of soft tissue in both maxillary sinuses. To avoid recall bias, the observers measured the wall thickness in each imaging modality at specific time intervals. First, all CT images were assessed, followed by assessment of the DT data. In both analyses, the volume of a clear maxillary sinus was regarded as 0 mm and the volume of a completely opacified maxillary sinus was regarded as 40 mm.

### Statistical Analysis

The wall thickness values of maxillary sinuses on CT and DT assessed by the two observers were presented as the mean with standard deviation (SD). The mean difference and the SD of the differences were calculated along with the 95% limits of agreement (LOA), which was specified as the mean difference  $\pm$  1.96 SD.

Bland-Altman plots as well as intraclass correlation coefficients were used to investigate the intra and interobserver repeatability. Differences between measurements were plotted against the measurement mean.

All statistical analyses were conducted using the SPSS 19.0 software package (SPSS Inc., Chicago, IL, USA). A *p*-value < 0.05 was considered statistically significant.

## RESULTS

A total of 228 maxillary sinuses of 114 patients were included in this study. The average patient age was  $44.8 \pm 13.8$  years (range: 20–74 years).

The mean soft tissue thickness within the maxillary sinus mea-

sured by observer 1 was  $12.8 \pm 15.0$  mm on CT and  $12.7 \pm 15.0$  mm on DT (Fig. 1). The mean measurements of soft tissue thickness within the maxillary sinus according to both CT and DT obtained by observer 2 were higher than those obtained by observer 1. The mean soft tissue thickness within the maxillary sinus obtained by observer 2 was  $13.1 \pm 14.8$  mm on CT and  $12.8 \pm 15.0$  mm on DT (Table 1).

The mean difference in soft tissue thickness measured by each observer was  $-0.31 \pm 2.03$  mm on CT and  $-0.15 \pm 1.66$  mm on DT. The interobserver 95% LOA for the maxillary sinus soft tissue thickness measurement ranged from  $-4.29$  to  $3.67$  for the CT images and from  $-3.41$  to  $3.11$  for the DT images (Table 2). Bland-Altman plots were used to evaluate the difference between the soft tissue thickness measurements obtained by the two observers versus the mean measurement value for each modality (Fig. 2).

The interobserver agreement for the maxillary sinus soft tissue thickness measurements on CT images was determined to be high. In addition, the intraclass correlation coefficient was 0.991 [95% confidence interval (CI), 0.988–0.993; *p* < 0.01]. The interobserver agreement for the measurements with DT was slightly higher than the interobserver agreement for the measurements with CT, with an intraclass correlation coefficient of 0.994 (95% CI, 0.992–0.995; *p* < 0.01) (Table 2).

Measurement values based on CT tended to be higher than those with DT for both observers. In addition, the difference in measured values for CT and DT was higher for observer 2 compared with observer 1. The mean difference measured by observer 1 was  $-0.15 \pm 1.64$  mm and  $-0.31 \pm 5.56$  mm by observer 2.

The 95% LOA for soft tissue thickness measurement using DT and CT images for the individual observers ranged from  $-3.36$  mm to  $3.06$  mm for observer 1 and from  $-5.56$  mm to  $4.95$  mm for observer 2 (Table 3).

Bland-Altman plots of the agreement between DT and CT for the two observers are shown in Fig. 3.

We observed a good correlation among the intraobserver agreements for both imaging modalities. Specifically, the ICC value for observer 1 was 0.994 (95% CI, 0.992–0.995; *p* < 0.01). While the ICC value for observer 2 was slightly less than that for observer 1, the intraobserver agreement for observer 2 was high, with an ICC of 0.984 (95% CI, 0.979–0.987; *p* < 0.01) (Table 3).

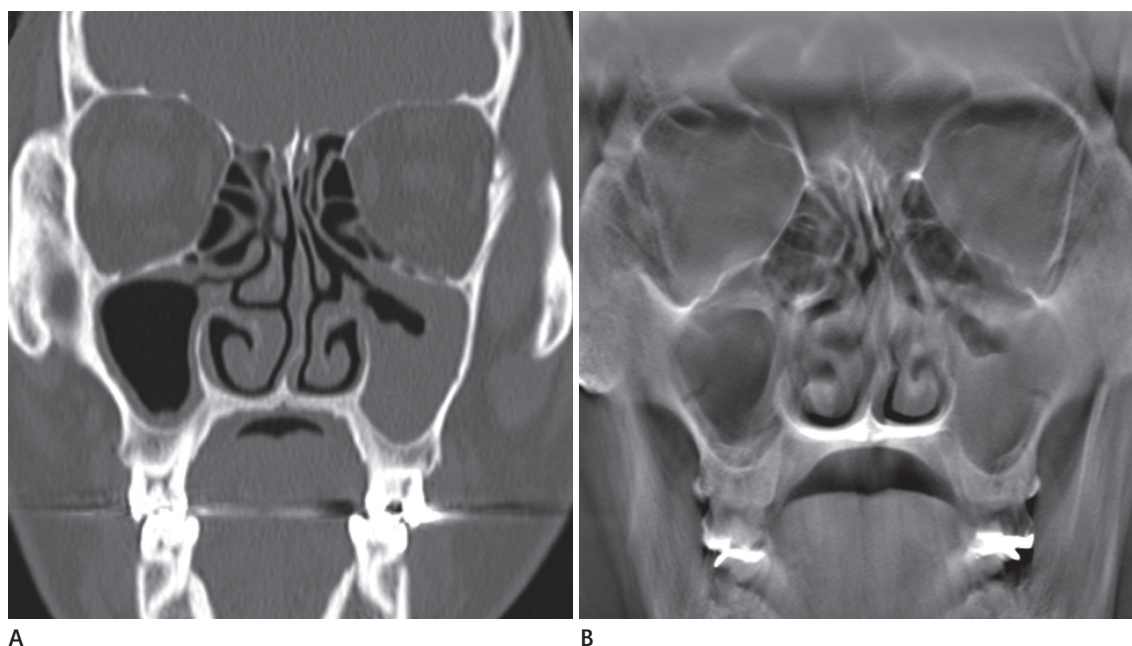
## DISCUSSION

In this study, DT exhibited a comparable diagnostic performance to MDCT in the determination of maxillary sinus wall thickness. In addition, the radiation dose remained substantially lower than the dose used in low-dose MDCT protocols. According to a phantom study, eye lens dose of 0.1 mGy for DT sinus radiography was lower than the previously reported dose of 0.5 mGy for conventional radiography, consisting of Waters, Caldwell, and lateral projections (13, 18). The threshold for pathological radiographic mucosal thickening varies within the literature. Although mild mucosal thickening is often asymptomatic

and considered a normal radiographic finding, thickening > 2 mm has been consistently reported to indicate sinus pathology (19, 20).

Sinusitis is one of the most common diseases treated by primary care physicians. Uncomplicated sinusitis does not require radiological imaging; however, when symptoms are recurrent or refractory despite adequate treatment, further diagnostic evaluations may be indicated. To this end, CT imaging is a highly sensitive method for detecting mucosal thickening of the PNS (19).

Plain radiography has a limited role in the management of sinusitis. Although air-fluid levels and complete opacification of the sinuses are specific indicators of sinusitis, they are seen in only



**Fig. 1.** DT (A) and MDCT (B) MPR coronal images of the paranasal sinuses acquired on the same day in a 52-year-old man with clinically suspected sinusitis. (A) DT shows abnormal mucosal thickening of both maxillary sinuses which is comparable to that shown by MDCT (B). DT = digital tomosynthesis, MDCT = multidetector computed tomography, MPR = multiplanar reconstruction

**Table 1.** Measurement of Maxillary Sinus Soft Tissue Thickness with Both DT and CT (mm)

	DT		CT	
	Observer 1	Observer 2	Observer 1	Observer 2
Mean measurement	12.67	12.82	12.82	13.13
Standard deviation	15.00	14.96	15.02	14.83

CT = computed tomography, DT = digital tomosynthesis

**Table 2.** Mean Maxillary Sinus Soft Tissue Thickness Measurement Error between the Two Observers according to Modality and Interobserver Agreement (mm)

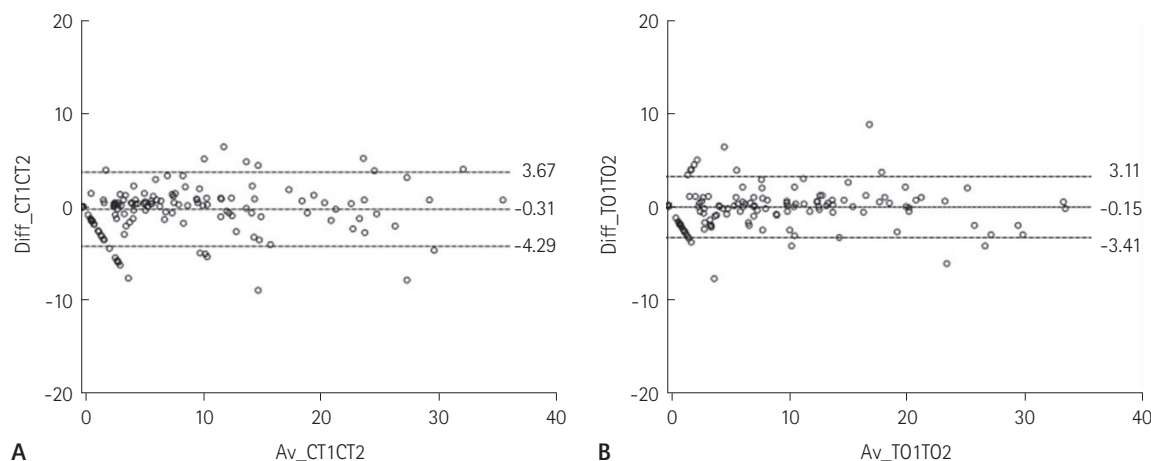
	Difference in Mean Measurement	Standard Deviation	Lower LOA	Upper LOA	ICC (95% CI)
DT	-0.15	1.66	-3.41	3.11	0.994 (0.992–0.995)
CT	-0.31	2.03	-4.29	3.67	0.991 (0.988–0.993)

CT = computed tomography, DT = digital tomosynthesis, LOA = limits of agreement, ICC = intraclass correlation coefficient

60% of cases (21). Additionally, conventional radiography can be confounded by a number of factors including overlying soft tissue, variation in sinus depth, and insufficient image quality. For these reasons, many institutions routinely employ thin-slice MDCT due to its high image quality. Coronal CT images can provide much more detailed information about the anatomy and

abnormalities of the PNS compared to plain radiography. However, radiation dosing, especially to the lens of the eye, is an important consideration according to Machida (13).

DT is a relatively new imaging modality composed of multiple projected images obtained at different angles. DT uses a limited rotation angle with a lower number of discrete exposures than



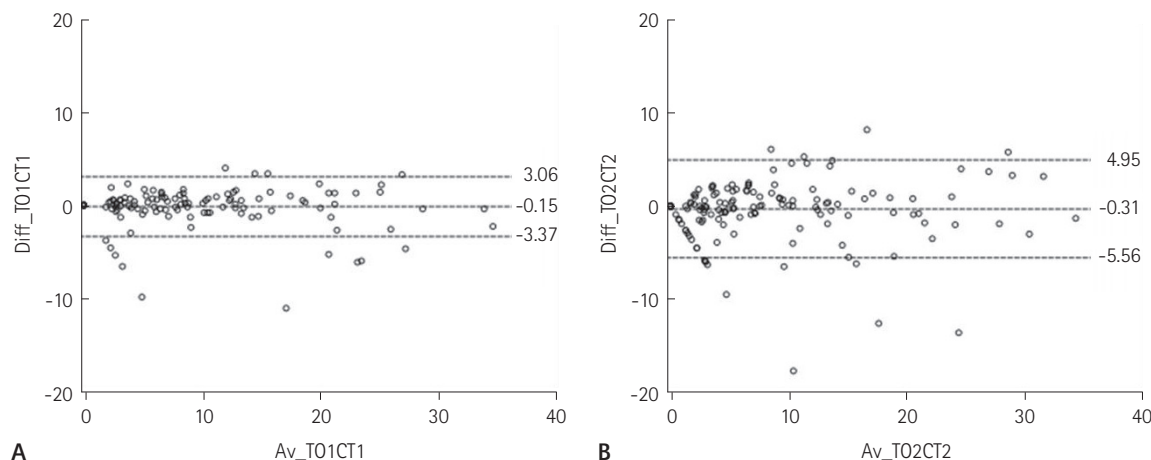
**Fig. 2.** Bland-Altman plots showing the difference in mean soft tissue thickness measurements between the observers' measurements as a function of the mean CT (A) and DT values (B). The dashed middle line represents the bias (mean difference between measurements). The dashed lower and upper lines represent the limits of agreement (mean  $\pm$  1.96 SD).

CT = computed tomography, DT = digital tomosynthesis, SD = standard deviation

**Table 3.** Mean Error for Maxillary Sinus Soft Tissue Thickness Measurements Using DT Compared to CT for All Observers with Intraobserver Agreement (mm)

	Difference in Mean Measurement	Standard Deviation	Lower LOA	Upper LOA	ICC (95% CI)
Observer 1	-0.15	1.64	-3.37	3.06	0.994 (0.992–0.995)
Observer 2	-0.31	2.68	-5.56	4.95	0.984 (0.979–0.987)

CT = computed tomography, DT = digital tomosynthesis, LOA = limits of agreement, ICC = intraclass correlation coefficient



**Fig. 3.** Bland-Altman plots showing the difference in measurements of soft tissue thickness between DT and CT as a function of the mean measurement according to the two modalities obtained by observer 1 (A) and observer 2 (B). The dashed middle line represents the bias (mean difference between measurements). The dashed lower and upper lines represent the limits of agreement (mean  $\pm$  1.96 SD).

CT = computed tomography, DT = digital tomosynthesis, SD = standard deviation



CT. Since fewer projections are needed to perform the reconstruction, radiation exposure and cost are reduced compared to CT (22). DT has been applied to a variety of clinical applications, including musculoskeletal imaging, mammographic imaging, vascular imaging, and chest imaging (8).

In musculoskeletal imaging, DT has been compared to both radiography and CT for the evaluation of fracture healing, especially in patients with an internal fixator. According to the study by Ha et al. (22), DT provides superior diagnostic information and reduces metal artifacts compared to radiography with an accompanying lower cost and radiation dose than CT (8). Unlike our study, which compares the visibility of soft tissue in the sinus cavity, their study assessed the visibility of fracture with DT compared to CT. According to their study, DT could be useful as a follow-up imaging technique in patients with facial bone fractures.

Johnsson et al. (8) showed that visibility and detectability with chest DT are comparable to the those with chest CT for the evaluation of a pulmonary nodule with a lower radiation dose. However, they noted that chest tomosynthesis has a limited depth resolution.

Tomosynthesis is approved by the Food and Drug Administration for use in breast cancer screening. Digital breast tomosynthesis provides a higher diagnostic accuracy for detecting a mass or architectural distortion compared to conventional mammography, especially in dense breast, by reducing overlapping breast tissue. In a breast section, the strength of DT is not associated with the radiation dose, but instead it is due to a higher detection rate of the lesion obscured by normal breast tissue and lesion localization (11). Our understanding and management of PNS infections has improved significantly since the introduction of nasal CT scans and MRI. However, clinical applications for DT have been growing steadily, and some researchers believe that sinus imaging should be added to the list (13). To test the suitability of DT for this application, Machida's team performed sinus MDCT and coronal tomosynthesis in 31 patients with suspected acute or chronic sinusitis (14). Images were then reviewed by two readers, who independently determined the presence of opacification, and results were compared between modalities. Results were assessed for each of the maxillary sinuses. Tomosynthesis afforded good detection of opacification in the maxillary sinuses, even among readers without any experience in interpreting such images. In addition, they reported that tomosynthesis requires approximately

1/300 th of the radiation dose of sinus MDCT (13).

There were several limitations to our study.

First, the two modalities were performed during different positions of the patients. DT was performed in an erect position, whereas CT was performed in a supine position. The fluid in the PNS moves according to the patient's posture, which can affect the point of maximum mucosal thickness. Furthermore, two observers selected the point of measurement as the thickest part of the maxillary sinus wall subjectively. Even though the point of measurement could not be exactly the same, it may be regarded as a relatively same point.

Secondly, the study did not assess other PNS besides the maxillary sinuses. In clinical practice, sinusitis can involve any sinus cavity. Therefore, it is difficult to directly apply our findings to a clinical setting.

Finally, we did not consider any anatomical problems. The DT images obtained by us had thicknesses that were too high to demonstrate the structural anatomy in detail. Patients with sinusitis often have underlying anatomic abnormalities of the sinus, which result in obstruction of the sinus cavity such as occlusion of drainage pathways or nasal septal deviation. Imaging studies are needed in the diagnosis and management of recurrent or chronic sinusitis, especially in order to define the anatomy of the sinuses prior to surgery. Unfortunately, our results did not show whether DT was comparable with CT in pre-operative anatomic evaluations. Thus, a further study on anatomical structure visibility with lesser DT slice thickness should be performed.

In conclusion, DT is comparable to CT for assessing wall thickening of the maxillary sinuses in patients with sinusitis. DT can be considered as a good alternative to CT for evaluation of paranasal sinusitis, although there are some disadvantages in obtaining information regarding detailed anatomy of the PNS with DT.

## REFERENCES

1. Chadha NK, Chadha R. 10-minute consultation: sinusitis. *BMJ* 2007;334:1165
2. Gliklich RE, Metson R. The health impact of chronic sinusitis in patients seeking otolaryngologic care. *Otolaryngol Head Neck Surg* 1995;113:104-109
3. McQuillan L, Crane LA, Kempe A. Diagnosis and manage-

- ment of acute sinusitis by pediatricians. *Pediatrics* 2009; 123:e193-e198
4. Momeni AK, Roberts CC, Chew FS. Imaging of chronic and exotic sinonasal disease: review. *AJR Am J Roentgenol* 2007;189(6 Suppl):S35-S45
5. Hoang JK, Eastwood JD, Tebbit CL, Glastonbury CM. Multi-planar sinus CT: a systematic approach to imaging before functional endoscopic sinus surgery. *AJR Am J Roentgenol* 2010;194:W527-W536
6. Aaløkken TM, Hagtvedt T, Dalen I, Kolbenstvedt A. Conventional sinus radiography compared with CT in the diagnosis of acute sinusitis. *Dentomaxillofac Radiol* 2003;32: 60-62
7. Dobbins JT 3rd, Godfrey DJ. Digital X-ray tomosynthesis: current state of the art and clinical potential. *Phys Med Biol* 2003;48:R65-R106
8. Johnsson AA, Vikgren J, Svalkvist A, Zachrisson S, Flinck A, Boijesen M, et al. Overview of two years of clinical experience of chest tomosynthesis at Sahlgrenska University Hospital. *Radiat Prot Dosimetry* 2010;139:124-129
9. Aoki T, Fujii M, Yamashita Y, Takahashi H, Oki H, Hayashida Y, et al. Tomosynthesis of the wrist and hand in patients with rheumatoid arthritis: comparison with radiography and MRI. *AJR Am J Roentgenol* 2014;202:386-390
10. Dalbeth N, Gao A, Roger M, Doyle AJ, McQueen FM. Digital tomosynthesis for bone erosion scoring in gout: comparison with plain radiography and computed tomography. *Rheumatology (Oxford)* 2014;53:1712-1713
11. Roth RG, Maidment AD, Weinstein SP, Roth SO, Conant EF. Digital breast tomosynthesis: lessons learned from early clinical implementation. *Radiographics* 2014;34:E89-E102
12. Shim SS, Oh YW, Kong KA, Ryu YJ, Kim Y, Jang DH. Pulmonary nodule size evaluation with chest tomosynthesis and CT: a phantom study. *Br J Radiol* 2015;88:20140040
13. Machida H, Yuhara T, Tamura M, Numano T, Abe S, Sabol JM, et al. Radiation dose of digital tomosynthesis for sinonasal examination: comparison with multi-detector CT. *Eur J Radiol* 2012;81:1140-1145
14. Yoo JY, Chung MJ, Choi B, Jung HN, Koo JH, Bae YA, et al. Digital tomosynthesis for PNS evaluation: comparisons of patient exposure and image quality with plain radiography. *Korean J Radiol* 2012;13:136-143
15. Machida H, Yuhara T, Ueno E, Yoda K, Sunose H, Kita K, et al. Detection of paranasal sinus opacification with digital tomosynthesis radiography: a clinical pilot study. *J Comput Assist Tomogr* 2013;37:252-256
16. Huda W, Ogden KM, Khorasani MR. Converting dose-length product to effective dose at CT. *Radiology* 2008;248: 995-1003
17. Gomi T. X-ray digital tomosynthesis imaging-comparison of reconstruction algorithms in terms of a reduction in the exposure dose for arthroplasty. In Bagaria V. *Arthroplasty - a comprehensive review*. Croatia: InTech, 2016
18. Czechowski J, Janeczek J, Kelly G, Johansen J. Radiation dose to the lens in sequential and spiral CT of the facial bones and sinuses. *Eur Radiol* 2001;11:711-713
19. Maillet M, Bowles WR, McClanahan SL, John MT, Ahmad M. Cone-beam computed tomography evaluation of maxillary sinusitis. *J Endod* 2011;37:753-757
20. Rak KM, Newell JD 2nd, Yakes WF, Damiano MA, Luethke JM. Paranasal sinuses on MR images of the brain: significance of mucosal thickening. *AJR Am J Roentgenol* 1991; 156:381-384
21. Low DE, Desrosiers M, McSherry J, Garber G, Williams JW Jr, Remy H, et al. A practical guide for the diagnosis and treatment of acute sinusitis. *CMAJ* 1997;156 Suppl 6:S1-S14
22. Ha AS, Lee AY, Hippe DS, Chou SH, Chew FS. Digital tomosynthesis to evaluate fracture healing: prospective comparison with radiography and CT. *AJR Am J Roentgenol* 2015;205:136-141

## 부비동 디지털 토모신테시스와 컴퓨터단층촬영을 이용한 상악동 벽 두께의 평가

변지은<sup>1</sup> · 심성신<sup>1\*</sup> · 김유경<sup>1</sup> · 공경애<sup>2</sup>

**목적:** 본 연구는 부비동을 평가하는 영상 도구로써 컴퓨터단층촬영과 디지털 토모신테시스를 비교분석하기 위해 상악동의 벽 두께 측정치를 비교하였다.

**대상과 방법:** 부비동염을 가지고 부비동 디지털 토모신테시스와 컴퓨터단층촬영을 모두 시행한 114명의 환자를 대상으로 후향적 연구를 진행하였다. 두 관찰자는 독립적으로 부비동 디지털 토모신테시스와 컴퓨터단층촬영을 모두 사용하여 양측 상악동 벽의 두께를 측정하였다.

**결과:** 각 관찰자에 의해 측정된 상악동 벽의 비후의 평균의 차이는 토모신테시스와 컴퓨터단층촬영에서 각각 -0.15 mm와 -0.31 mm로 측정되었다. 두 검사 방법을 이용한 측정치의 일치도를 평가하였을 때는 관찰자 1에서는 -3.36 mm에서 3.06 mm[intraclass correlation coefficient (이하 ICC), 0.994;  $p < 0.01$ ] 그리고 관찰자 2에서는 -5.56 mm에서 4.95 mm(ICC, 0.984;  $p < 0.01$ )의 95% limit of agreement를 보이는 높은 개체 내 상관관계를 보였다.

**결론:** 상악동 벽의 비후를 평가하기 위하여 디지털 토모신테시스는 컴퓨터단층촬영과 견줄 만한 영상 도구이다.

이화여자대학교 의과대학 목동병원 <sup>1</sup>영상의학과, <sup>2</sup>임상시험센터