

Sonographic Decreased Echogenicity of Thyroid Parenchyma in Asymptomatic Population: Correlation with Thyroid Function and Thyroid Autoimmune Activity

무증상 집단에서 갑상선 실질의 초음파 에코 감소: 갑상선 기능 및 갑상선 자가면역 활성도와와의 연관성

Ji Yeon Park, MD^{1,2}, Noh Hyuck Park, MD^{1*}, Chan Sub Park, MD¹, Ji Ye Lee, MD¹, Kyung Ah Chun, MD^{2,3}, Seong Yoon Yi, MD⁴, Hee Jin Park, MD⁵

¹Department of Radiology, Myongji Hospital, Seonam University College of Medicine, Goyang, Korea

²Department of Radiology, Catholic Kwandong University School of Medicine, Gangneung, Korea

³Department of Radiology, Catholic Kwandong University International St. Mary's Hospital, Incheon, Korea

⁴Division of Hematology-Oncology, Department of Internal Medicine, Inje University Ilsan Paik Hospital, Goyang, Korea

⁵Department of Radiology, Sungkyunkwan University School of Medicine, Kangbuk Samsung Hospital, Seoul, Korea

Purpose: The aim of the study was to evaluate the correlation between decreased echogenicity of thyroid and thyroid hormones or autoantibodies.

Materials and Methods: From January 2009 to December 2011, 543 patients with decreased parenchymal echogenicity [M:F = 133:410, median age: 42 years (range: 9–82 years)], who did not have solid nodule, symptom or medication related to thyroid and underwent thyroid function test were retrospectively reviewed. Images were classified based on the degree of hypoechoogenicity, heterogeneity or thyroid size. 1) Group A: mild decreased echogenicity, group B: marked decreased echogenicity, 2) group Ho: homogeneous echogenicity, group He: heterogeneous echogenicity, 3) group 1: decreased size, group 2: normal size, group 3: increased size. Differences in triiodothyronine (T3), free-thyroxine (fT4), thyrotropin (TSH), anti-thyroglobulin antibody (TgAb), thyroid peroxidase antibody (TPOAb), and anti-TSH receptor antibody (TSH-rAb) were evaluated among groups.

Results: T3, fT4, and TSH levels differed between groups A and B ($p < 0.001$, $p = 0.001$, $p < 0.001$). TgAb and TPOAb of group B were higher than group A ($p = 0.006$, $p < 0.001$). TPOAb of group He was higher than group Ho ($p < 0.001$). TSH-rAb and TPOAb of group 3 were higher than group 2 ($p = 0.017$, $p < 0.001$).

Conclusion: The patients with findings of markedly decreased, heterogeneous echogenicity or thyroid enlargement may have abnormal thyroid function and autoantibodies. These may facilitate the physicians' decision to order tests for thyroid function and autoimmune activity.

Index terms

Thyroid Gland
Ultrasonography
Thyroid Hormones
Autoantibodies

Received January 29, 2015

Revised April 1, 2015

Accepted March 22, 2016

***Corresponding author:** Noh Hyuck Park, MD
Department of Radiology, Myongji Hospital,
Seonam University College of Medicine,
55 Hwasu-ro 14beon-gil, Deogyang-gu,
Goyang 10475, Korea.
Tel. 82-31-810-7164 Fax. 82-31-810-6537
E-mail: nhpark904@gmail.com

This is an Open Access article distributed under the terms of the Creative Commons Attribution Non-Commercial License (<http://creativecommons.org/licenses/by-nc/3.0>) which permits unrestricted non-commercial use, distribution, and reproduction in any medium, provided the original work is properly cited.

INTRODUCTION

Ultrasonography is an established method for evaluation of tissue echogenicity in cases of suspected thyroid diseases such as Hashimoto's thyroiditis or Graves' disease and an effective tool for detection of focal lesions (1-4). On ultrasound (US), de-

creased echogenicity of thyroid parenchyma is commonly detected; in fact, it has been reported in cases of autoimmune thyroid diseases such as Hashimoto's thyroiditis or Graves' disease (2, 5-7). Many studies have correlated sonographic echogenicity of thyroid in patients with Hashimoto's thyroiditis or Graves' disease with thyroid function test results and thyroid autoim-

mune activity (2, 3, 8, 9). However, the relationship between decreased thyroid echogenicity and thyroid function test or autoimmune activity in the general population has rarely been studied (7, 10-12). Vejbjerg et al. (11) reported the association between hypoechogenicity or irregular echo pattern on thyroid US and thyroid function in the general population. Likewise, Dvoráková et al. (12), reported a correlation between echogenicity of the thyroid and autoimmune antibodies in a randomly selected population; however, their subject group did not include a large number of patients with decreased echogenicity, and the thyroid parenchyma size was not considered. To our knowledge, the associations of decreased echogenicity, heterogeneous echotexture and thyroid size with thyroid function and autoimmune activity, especially in an asymptomatic population, has not previously been reported.

The purpose of this study was to evaluate the relationships between the degree of decreased thyroid echogenicity, heterogeneity or size with function and autoimmune activity, in an asymptomatic population.

MATERIALS AND METHODS

This retrospective study was approved by our Institutional Review Board, and individual patient consent was waived.

From January 2009 to December 2011, 5611 thyroid US examinations were performed in our institution. The radiologic reports and Picture Archiving and Communication System images of thyroid US were retrospectively reviewed. The patients with images showing decreased parenchymal echogenicity were se-

lected ($n = 1457$). Decreased echogenicity was defined when more than two-thirds of whole thyroid parenchyma showed lower echogenicity than that of the individual patient's submandibular gland by visual assessment (7). When the echogenicity of submandibular gland was abnormal due to sialoadenitis or connective tissue disease, the echogenicity of parotid gland was considered as a standard. Patients with any focal solid nodule on their thyroid US ($n = 459$), previous treatment with medication related to thyroid ($n = 195$), or symptoms related to thyroid ($n = 126$) were excluded. Our study only included asymptomatic patients. Cases without serum triiodothyronine (T3), free-thyroxine (fT4), and thyrotropin (TSH) results ($n = 134$) were also excluded. Finally, a total of 543 asymptomatic patients with decreased parenchymal echogenicity were included in the study.

Thyroid US was performed using the HDI 5000 or IU 22 (Philips medical system, Best, the Netherlands) with a 7.5 MHz linear probe. Two radiologists with 5 and 15 years of experience in thyroid US interpreted the US results in consensus. The patients were classified into two groups based on the degree of hypoechogenicity i.e., group A: patients who were hypoechoic relative to the submandibular gland, but hyperechoic relative to strap muscle (Fig. 1A, B); and group B: patients who were isoechoic or hypoechoic relative to strap muscle (Fig. 1C) (7). We also divided the patients with decreased echogenicity into homogeneous (group Ho) and heterogeneous groups (group He) (Fig. 2). Group He was defined when the US showed multiple scattered small hypoechoic nodules in whole thyroid parenchyma. We then classified the patients into three groups based on thyroid size i.e., group 1: patients who had a decreased

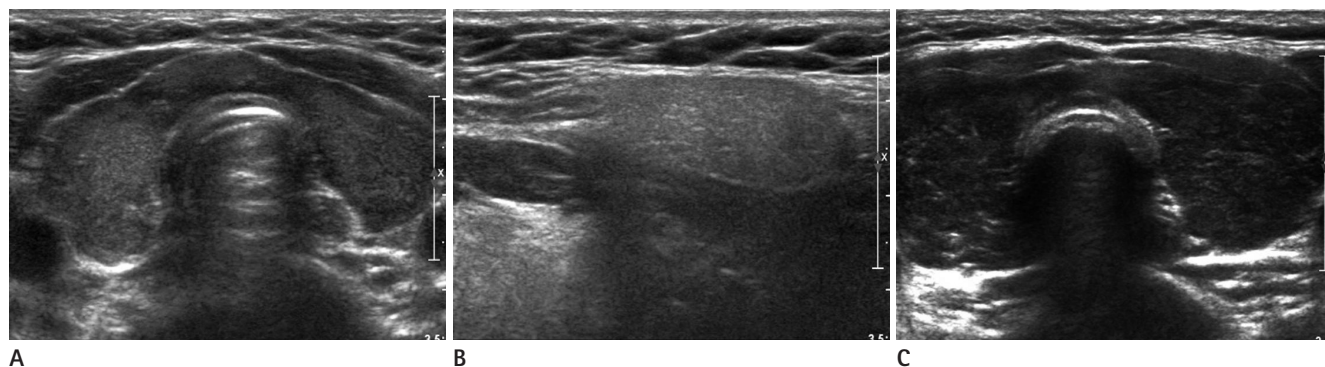


Fig. 1. Ultrasound (US) of group A and group B.

A, B. US of group A shows mild decreased echogenicity (**A**) of thyroid, which is lower than the echogenicity of submandibular gland (**B**), but higher than that of strap muscle.

C. US of group B shows the decreased echogenicity of thyroid, which is isoechoic to strap muscle.

thyroid size (< 1.2 cm at the thickest anteroposterior diameter); group 2: patients whose thyroid was within normal size range (1.3–1.8 cm anteroposterior diameter); and group 3: patients who had an increased thyroid size (> 1.9 cm at the thickest anteroposterior diameter) (Fig. 3). Normal thyroid dimension were reported as 13–18 mm anteroposterior diameter in adult population (13, 14). Additionally, we reviewed the serum levels of T3 (reference value: 0.89–1.68 ng/mL), fT4 (reference value: 0.88–1.44 ng/dL), TSH (reference value: 0.35–5.50 uIU/mL), anti-thyroglobulin antibody (TgAb) (reference value: ~40 IU/mL), thyroid peroxidase antibody (TPOAb) (reference value: ~35 IU/mL), and anti-TSH receptor antibody (TSH-rAb) (reference value: ~1.75 IU/L). T3, fT4, and TSH levels within the reference value were classified as normal, higher than upper limit of reference value were classified as elevated level, and

lower than lower limit of reference value were classified as low. TgAb, TPOAb, TSH-rAb levels within the reference value were defined as negative, and higher than reference were defined as positive.

The comparisons of the thyroid function test and anti-thyroid antibody levels among the groups were analyzed using the Pearson chi-square test. The statistical significance threshold value was considered as $p < 0.05$.

RESULTS

The 543 patients included 133 men and 410 women with a median age of 42 years (range: 9–82 years). The number of patients in group A was 448 (82.5%) and in group B, 95 (17.5%). Homogeneous decreased echotexture (group Ho) was observed

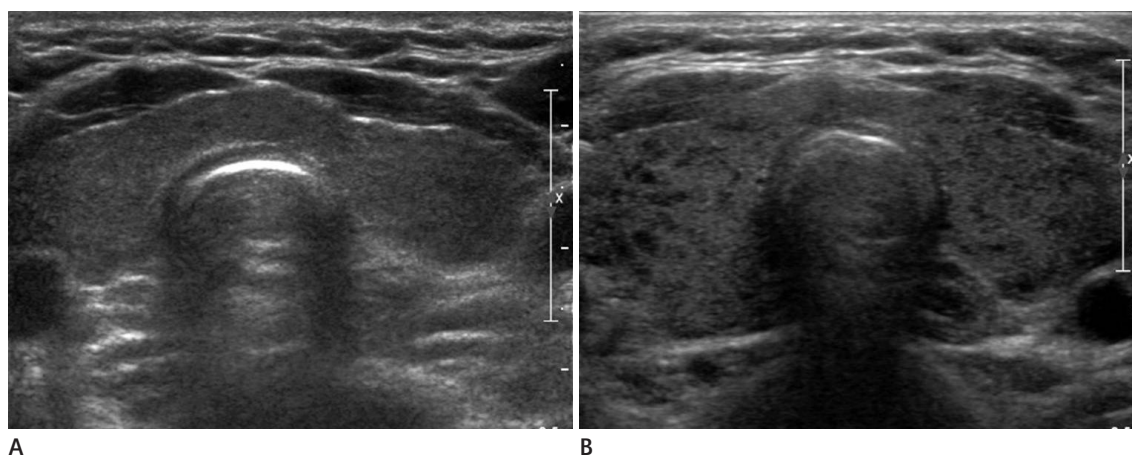


Fig. 2. Ultrasound (US) of group Ho and group He.

A. US of group Ho shows homogeneous decreased echogenicity of thyroid.

B. US of group He shows multiple scattered tiny hypoechoic nodules in whole thyroid.

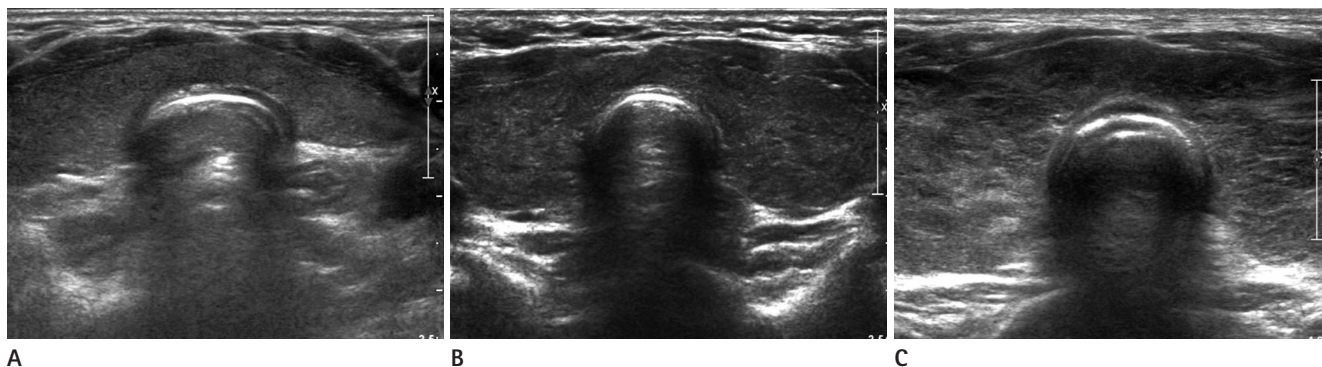


Fig. 3. Ultrasound (US) of group 1, 2, and 3.

A. US of group 1 shows decreased size of thyroid.

B. US of group 2 shows normal size of thyroid.

C. US of group 3 shows increased size of thyroid.

Table 1. Epidemiologic and Sonographic Characteristics of 543 Patients with Decreased Echogenicity

Gender (M:F)	133:410
Age (median)	42 (range: 9–82 years)
Decreased echogenicity	
Group A	448 (82.5%)
Group B	95 (17.5%)
Homogeneity/heterogeneity	
Group Ho	109 (20.1%)
Group He	434 (79.9%)
Size of thyroid	
Group 1	19 (3.5%)
Group 2	184 (33.9%)
Group 3	340 (62.6%)

Group A: patients with lower echogenicity than that of submandibular gland, but higher than that of strap muscle, Group B: patients with isoechoic or lower echogenicity than that of strap muscle, Group Ho: patients with homogeneous decreased echogenicity of thyroid, Group He: patients with multiple scattered small hypoechoic nodules in whole thyroid parenchyma, Group 1: decreased size, Group 2: normal size, Group 3: increased size

Table 2. Thyroid Function and Autoimmune Activity of 543 Patients with Decreased Echogenicity

T3	
Low	120 (22.1%)
Normal	321 (59.1%)
Elevated	102 (18.8%)
fT4	
Low	66 (12.2%)
Normal	339 (62.4%)
Elevated	138 (25.4%)
TSH	
Low	142 (26.2%)
Normal	308 (56.7%)
Elevated	93 (17.1%)
TgAb	200
Negative	121 (60.5%)
Positive	79 (39.5%)
TSH-rAb	176
Negative	113 (64.2%)
Positive	63 (35.8%)
TPOAb	306
Negative	177 (57.8%)
Positive	129 (42.2%)

Reference value: T3 (0.89–1.68 ng/mL), free T4 (0.88–1.44 ng/dL), TSH (0.35–5.50 uIU/mL), TgAb (~40 IU/mL), TPOAb (~35 IU/mL), TSH-rAb (~1.75 IU/L). fT4 = free-thyroxine, TgAb = anti-thyroglobulin antibody, TPOAb = thyroid peroxidase antibody, TSH = thyrotropin, TSH-rAb = anti-TSH receptor antibody, T3 = triiodothyronine

in 109 patients (20.1%) and heterogeneous echotexture (group He), in 434 patients (79.9%). Nineteen patients (3.5%) had a decreased thyroid size (group 1), 184 patients (33.9%) had size within the normal range (group 2), and 340 patients (62.6%) had an enlarged thyroid (group 3).

The characteristics of the patients were listed in Tables 1, 2.

T3, fT4, and TSH levels differed significantly between groups A and B ($p < 0.001$, $p = 0.001$, $p < 0.001$). In group B, T3 was low in 14.7%, elevated in 32.6% of the patients and fT4 was low in 17.9%, elevated in 36.8%; while TSH was low in 37.9%, and elevated in 26.3% of the patients. In group A, T3 was low in 23.7% and elevated in 15.8% of the patients; fT4 was low in 10.9% and elevated in 23.0%; while TSH was low in 23.7% and elevated in 15.2% of the patients. TSH-rAb levels did not differ between groups A and B ($p = 0.65$). TgAb and TPOAb levels in group B showed significant positivity, as compared with those in group A ($p = 0.006$, $p < 0.001$). Fifty-nine percent of group B showed a positive TgAb, and 67.6% showed positive TPOAb. On the other hand, 34.8% and 34.9% of group A showed positive TgAb and TPOAb (Table 3).

T3, fT4, TSH, TgAb, and TSH-rAb levels were not significantly different between groups He and Ho, though TPOAb level was significantly positive in group He ($p < 0.001$). 48.5 % of group He and 19.4% of group Ho showed positive TPOAb (Table 4).

Among groups 1, 2, and 3, the T3, fT4, and TSH levels were significantly different ($p < 0.001$), especially between groups 2 and 3. T3, fT4, and TSH levels were normal in 60.9%, 73.9%, and 70.7% of group 2, respectively; and in 58.2%, 56.2%, and 49.4% of group 3, respectively. In group 2, T3 was low in 33.2% and elevated in 6.0%; by contrast, in group 3, T3 was low in 15.3% and elevated in as many as 26.5%. In group 2, fT4 was elevated in 14.7%, but in group 3, it was elevated in 32.4%. In group 2, TSH was low in 12.0% of patients, but in group 3, it was low in 34.1%. TSH-rAb and TPOAb showed significant positivity in group 3 relative to group 2 ($p < 0.001$, $p = 0.017$); whereas, the TgAb level was not significantly different among groups 1, 2, and 3 ($p = 0.084$) (Table 5).

DISCUSSION

Diffusely decreased echogenicity of the thyroid parenchyma is a well known sonographic finding in autoimmune thyroid

disease such as Hashimoto's thyroiditis and Graves' disease (4, 5, 8, 15). Hypoechogenicity is caused by reduction of colloid content, increased intrathyroidal blood flow or lymphocytic tissue infiltration (8). Many studies have focused on the relationship of laboratory parameters to thyroid echogenicity in patients with Hashimoto's thyroiditis or Graves' disease (2, 3, 8, 9). Schiemann et al. (3) noted that decreased echogenicity was correlated with TSH and TSH-rAb levels in patients with Graves' disease; and Schiemann et al. (8) reported that high-grade hypoechogenicity was associated with increased TSH levels and highly elevated TPOAb in patients with Hashimoto's thyroiditis. However, these findings pertain only to specific conditions such as Hashimoto's thyroiditis or Graves' disease. More notably, Vejbjerg et al. (11) demonstrated an association between reduced echogenicity and/or irregular echo pattern and high values of

TSH and TgAb/TPOAb positivity in the general population. Moreover, in a randomly selected population, Dvoráková et al. (12), reported highly significant relationship between decreased echogenicity and TgAb/TPOAb. In the present study on asymptomatic population, cases with decreased thyroid echogenicity showed significantly positive TgAb and TPOAb; and significant TPOAb positivity was observed in patients with heterogeneous decreased echogenicity. The patients with enlarged thyroid showed significantly elevated levels of TSH-rAb and TPOAb. Additionally, T3, fT4, and TSH levels in the group with more severe decreased echogenicity were significantly abnormal (either decrease or increase) relative to those with mild decreased echogenicity. T3 were abnormal in 47.4% of the more decreased echogenicity group and in 39.5% of mild decreased echogenicity group. The fT4 and TSH levels were ab-

Table 3. Comparison of Thyroid Function Test or Thyroid Autoantibodies between Mildly Decreased Echogenicity (Group A) and Markedly Decreased Echogenicity (Group B)

	Group A	Group B	p-Value*
T3			< 0.001
Low	106 (23.7%)	14 (14.7%)	
Normal	271 (60.5%)	50 (52.6%)	
Elevated	71 (15.8%)	31 (32.6%)	
fT4			0.001
Low	49 (10.9%)	17 (17.9%)	
Normal	296 (66.1%)	43 (45.3%)	
Elevated	103 (23.0%)	35 (36.8%)	
TSH			< 0.001
Low	106 (23.7%)	36 (37.9%)	
Normal	274 (61.2%)	34 (35.8%)	
Elevated	68 (15.2%)	25 (26.3%)	
TPOAb			< 0.001
(-)	155 (65.1%)	22 (32.4%)	
(+)	83 (34.9%)	46 (67.6%)	
TgAb			0.006
(-)	105 (65.2%)	16 (41%)	
(+)	56 (34.8%)	23 (59%)	
TSH-rAb			0.650
(-)	86 (65.2%)	27 (61.4%)	
(+)	46 (34.8%)	17 (38.6%)	

Group A: patients with lower echogenicity than that of submandibular gland, but higher than that of strap muscle, Group B: patients with isoechoic or lower echogenicity than that of strap muscle.

*Pearson chi-square test was used.

fT4 = free-thyroxine, TgAb = anti-thyroglobulin antibody, TPOAb = thyroid peroxidase antibody, TSH = thyrotropin, TSH-rAb = anti-TSH receptor antibody, T3 = triiodothyronine

Table 4. Comparison of Thyroid Function Test or Thyroid Autoantibodies between Homogeneous (Group Ho) and Heterogeneous Group (Group He)

	Group Ho	Group He	p-Value*
T3			0.635
Low	25 (22.9%)	95 (21.9%)	
Normal	67 (61.5%)	254 (58.5%)	
Elevated	17 (15.6%)	85 (19.6%)	
fT4			0.137
Low	11 (10.1%)	55 (12.7%)	
Normal	77 (70.6%)	262 (60.3%)	
Elevated	21 (19.3%)	117 (27%)	
TSH			0.278
Low	23 (21.1%)	119 (27.4%)	
Normal	69 (63.3%)	239 (55.1%)	
Elevated	17 (15.6%)	76 (17.5%)	
TPOAb			< 0.001
(-)	54 (80.6%)	123 (51.5%)	
(+)	13 (19.4%)	116 (48.5%)	
TgAb			0.119
(-)	33 (70.2%)	88 (57.5%)	
(+)	14 (29.8%)	65 (42.5%)	
TSH-rAb			0.159
(-)	24 (75%)	89 (61.8%)	
(+)	8 (25%)	55 (38.2%)	

Group Ho: patients with homogeneous decreased echogenicity of thyroid, Group He: patients with multiple scattered small hypoechoic nodules in whole thyroid parenchyma.

*Pearson chi-square test was used.

fT4 = free-thyroxine, TgAb = anti-thyroglobulin antibody, TPOAb = thyroid peroxidase antibody, TSH = thyrotropin, TSH-rAb = anti-TSH receptor antibody, T3 = triiodothyronine

Table 5. Comparison of Thyroid Function Test or Thyroid Autoantibodies among Decreased (Group 1), Normal (Group 2), and Increased Size of Thyroid (Group 3)

	Group 1	Group 2	Group 3	<i>p</i> -Value*	1 vs. 2*	1 vs. 3*	2 vs. 3*
T3				< 0.001	0.946	0.016	< 0.001
Low	7 (36.8%)	61 (33.2%)	52 (15.3%)				
Normal	11 (57.9%)	112 (60.9%)	198 (58.2%)				
Elevated	1 (5.3%)	11 (6.0%)	90 (26.5%)				
fT4				< 0.001	0.036	0.006	< 0.001
Low	6 (31.6%)	21 (11.4%)	39 (11.5%)				
Normal	12 (63.2%)	136 (73.9%)	191 (56.2%)				
Elevated	1 (5.3%)	27 (14.7%)	110 (32.4%)				
TSH				< 0.001	0.262	0.371	< 0.001
Low	4 (21.1%)	22 (12.0%)	116 (34.1%)				
Normal	10 (52.6%)	130 (70.7%)	168 (49.4%)				
Elevated	5 (26.3%)	32 (17.4%)	56 (16.5%)				
TPOAb				0.002	0.632	0.290	< 0.001
(-)	8 (66.7%)	63 (73.3%)	106 (51%)				
(+)	4 (33.3%)	23 (26.7%)	102 (49%)				
TgAb				0.215	0.711	0.304	0.127
(-)	6 (75%)	37 (68.5%)	78 (56.5%)				
(+)	2 (25%)	17 (31.5%)	60 (43.5%)				
TSH-rAb				0.025	0.399	0.153	0.017
(-)	3 (100%)	29 (80.6%)	81 (59.1%)				
(+)	0 (0%)	7 (19.4%)	56 (40.9%)				

Group 1: decreased size, Group 2: normal size, Group 3: increased size.

*Pearson chi-square test was used.

fT4 = free-thyroxine, TgAb = anti-thyroglobulin antibody, TPOAb = thyroid peroxidase antibody, TSH = thyrotropin, TSH-rAb = anti-TSH receptor antibody, T3 = triiodothyronine

normal in 54.7% and 64.2%, respectively, of the more decreased echogenicity group. These results differed from Vejbjerg et al.'s (11), possibly due to a difference in the analysis of T3, T4, and TSH levels. We divided the T3, T4, and TSH levels into low, normal and elevated groups, whereas Vejbjerg et al. used the mean serum TSH level. The difference might also have been caused by our inclusion of questionable Graves' disease and Hashimoto's thyroiditis, which could have shown decreased echogenicity on thyroid US. In our study, 59% and 67.6% of the patients with severe decreased echogenicity showed positive levels of TgAb and TPOAb. Of the patients with heterogeneous decreased echogenicity, 48.5% showed TPOAb positivity, very similar to the result of Vejbjerg et al. (48.5%). Additionally, in our study, patients with decreased echogenicity and thyroid enlargement showed significantly increased levels of TPOAb and TSH-rAb.

The key to the diagnosis of autoimmune thyroid disease is detection of elevated anti-thyroid antibody titers, which include

TgAb, TPOAb, and TSH-rAb (16, 17). Ultrasonography, while not a diagnostic method for autoimmune thyroid disease, is nonetheless helpful for evaluation of thyroid echogenicity. Considering our results, each US findings of markedly decreased, heterogeneous echogenicity and thyroid enlargement in an asymptomatic population can be helpful for predicting autoimmune thyroid disease. In such cases, an asymptomatic population might also show abnormal T3, fT4, and TSH levels, as compared to mild decreased echogenicity, homogeneous echogenicity or normal thyroid size. Therefore, when an asymptomatic population shows markedly decreased echogenicity or heterogeneous decreased echogenicity or decreased echogenicity with thyroid enlargement, the possibility of autoimmune thyroid disease can be predicted, and further evaluation such as thyroid function test and anti-thyroid antibody test can be recommended.

Our study has several limitations. First, it was a retrospective analysis, hence, a more controlled and prospective trial is needed to determine the exact significance of thyroid US in the pre-

diction of autoimmune thyroid disease. Second, since the gray scale score was not used in measuring sonographic echogenicity, this study cannot be considered as objective. However, our experts reached a consensus on echogenicity (degree of decreased echogenicity and heterogeneity) and thyroid size measurement results. Studies employing a more standardized gray scale are needed. Third, ultrasonographic thyroid volume was not measured objectively due to the retrospective nature of the study. In most adults, the thyroid measures between 1.3 and 1.8 cm at the thickest anteroposterior dimension. The thyroid gland with an anteroposterior diameter of > 2 cm is considered as enlarged (13, 14). Fourth, because the population of this study was asymptomatic, it was heterogeneous including cases of both Hashimoto's thyroiditis and Graves' disease. Correspondingly, the serum levels of T3, fT4, and TSH showed no significant linear correlation, and therefore, statistical interpretation was very difficult. Because T3, fT4, and TSH levels were highly variable, ranging from extremely low to extremely high, we concluded that comparison of the median values among the groups would not be effective. Fifth, we did not compare the patients showing decreased echogenicity with those showing normal echogenicity. Many papers have already reported that patients with decreased echogenicity manifested significantly different thyroid function and autoimmune activity from those of patients with normal echogenicity (11, 12). Therefore, we focused on patients with varying degrees of decreased echogenicity.

The role of thyroid US in asymptomatic population is uncertain. However, the widespread use of US may lead to increased detection of decreased echogenicity on thyroid US. In conclusion, although they had no symptom related to the thyroid, the patients with each sonographic findings of markedly decreased, heterogeneous echogenicity or thyroid enlargement may have abnormal thyroid function test and autoimmune activity. These findings may facilitate the physicians' decision to order tests for thyroid function and autoimmune activity.

REFERENCES

- Blum M, Goldman AB, Herskovic A, Hernberg J. Clinical applications of thyroid echography. *N Engl J Med* 1972;287:1164-1169
- Loy M, Cianchetti ME, Cardia F, Melis A, Boi F, Mariotti S. Correlation of computerized gray-scale sonographic findings with thyroid function and thyroid autoimmune activity in patients with Hashimoto's thyroiditis. *J Clin Ultrasound* 2004;32:136-140
- Schiemann U, Gellner R, Riemann B, Schierbaum G, Menzel J, Domschke W, et al. Standardized grey scale ultrasonography in Graves' disease: correlation to autoimmune activity. *Eur J Endocrinol* 1999;141:332-336
- Nordmeyer JP, Shafah TA, Heckmann C. Thyroid sonography in autoimmune thyroiditis. A prospective study on 123 patients. *Acta Endocrinol (Copenh)* 1990;122:391-395
- Hayashi N, Tamaki N, Konishi J, Yonekura Y, Senda M, Kasagi K, et al. Sonography of Hashimoto's thyroiditis. *J Clin Ultrasound* 1986;14:123-126
- Vitti P. Grey scale thyroid ultrasonography in the evaluation of patients with Graves' disease. *Eur J Endocrinol* 2000;142:22-24
- Raber W, Gessl A, Nowotny P, Vierhapper H. Thyroid ultrasound versus antithyroid peroxidase antibody determination: a cohort study of four hundred fifty-one subjects. *Thyroid* 2002;12:725-731
- Schiemann U, Avenhaus W, Konturek JW, Gellner R, Hengst K, Gross M. Relationship of clinical features and laboratory parameters to thyroid echogenicity measured by standardized grey scale ultrasonography in patients with Hashimoto's thyroiditis. *Med Sci Monit* 2003;9:MT13-MT17
- Mazziotti G, Sorvillo F, Iorio S, Carbone A, Romeo A, Piscopo M, et al. Grey-scale analysis allows a quantitative evaluation of thyroid echogenicity in the patients with Hashimoto's thyroiditis. *Clin Endocrinol (Oxf)* 2003;59:223-229
- Rago T, Chiovato L, Grasso L, Pinchera A, Vitti P. Thyroid ultrasonography as a tool for detecting thyroid autoimmune diseases and predicting thyroid dysfunction in apparently healthy subjects. *J Endocrinol Invest* 2001;24:763-769
- Vejbjerg P, Knudsen N, Perrild H, Laurberg P, Pedersen IB, Rasmussen LB, et al. The association between hypoechogenicity or irregular echo pattern at thyroid ultrasonography and thyroid function in the general population. *Eur J Endocrinol* 2006;155:547-552
- Dvoráková M, Hill M, Cerovská J, Novák Z, Sterzl I. [Is decreased thyroid echogeneity a good indicator of thyroid autoimmune disorder?]. *Vnitr Lek* 2006;52:900-905

13. Chaudhary V, Bano S. Thyroid ultrasound. *Indian J Endocrinol Metab* 2013;17:219-227
14. Solbiati L, Charboneau JW, Osti V, James EM, Hay ID. *The thyroid gland*. In Rumack CM, Wilson SR, Charboneau JW. *Diagnostic ultrasound*. St. Louis: Elsevier Mosby, 2005:735-770
15. Marcocci C, Vitti P, Cetani F, Catalano F, Concetti R, Pinchera A. Thyroid ultrasonography helps to identify patients with diffuse lymphocytic thyroiditis who are prone to develop hypothyroidism. *J Clin Endocrinol Metab* 1991;72:209-213
16. Bahn Chair RS, Burch HB, Cooper DS, Garber JR, Greenlee MC, Klein I, et al. Hyperthyroidism and other causes of thyrotoxicosis: management guidelines of the American Thyroid Association and American Association of Clinical Endocrinologists. *Thyroid* 2011;21:593-646
17. Garber JR, Cobin RH, Gharib H, Hennessey JV, Klein I, Mechanick JL, et al. Clinical practice guidelines for hypothyroidism in adults: cosponsored by the American Association of Clinical Endocrinologists and the American Thyroid Association. *Thyroid* 2012;22:1200-1235

무증상 집단에서 갑상선 실질의 초음파 에코 감소: 갑상선 기능 및 갑상선 자가면역 활성도와의 연관성

박지연^{1,2} · 박노혁^{1*} · 박찬섭¹ · 이지예¹ · 천경아^{2,3} · 이성운⁴ · 박희진⁵

목적: 무증상인 갑상선 초음파에서 갑상선 에코 감소와 갑상선 호르몬 및 자가항체 간의 연관성을 평가하였다.

대상과 방법: 2009년 1월부터 2011년 12월까지의 초음파상 갑상선 에코가 감소된 543명의 환자를 후향적으로 분석하였다. 에코 감소의 정도와, 불균일성, 갑상선 크기를 기준으로 여러 군으로 나누었다. 1) A군: 약간 감소된 에코, B군: 현저히 감소된 에코, 2) Ho군: 균일 에코, He군: 불균일 에코, 3) 1군: 크기 감소, 2군: 정상, 3군: 크기 증가. 각 군 사이의 triiodothyronine (이하 T3), 유리 thyroxine (이하 T4), 갑상선자극호르몬(thyrotropin; 이하 TSH), 갑상선글로불린 항체(anti-thyroglobulin antibody; 이하 TgAb), 갑상선 과산화효소 항체(thyroid peroxidase antibody; 이하 TPOAb), 갑상선자극호르몬 수용체 항체(anti-TSH receptor antibody; 이하 TSH-rAb)의 혈청수치를 비교 평가하였다.

결과: A군과 B군 사이 T3, 유리 T4, TSH 수치가 달랐다($p < 0.001$, $p = 0.001$, $p < 0.001$). B군의 TgAb, TPOAb 수치가 A군보다 높았다($p = 0.006$, $p < 0.001$). He군의 TPOAb 수치가 Ho군보다 높았다($p < 0.001$). 3군의 TSH-rAb, TPOAb 수치가 2군보다 높았다($p = 0.017$, $p < 0.001$).

결론: 갑상선의 현저한 에코 감소, 불균일 에코, 또는 크기 증가가 있는 경우 갑상선 기능 및 자가면역항체의 이상 소견을 가질 가능성이 있다. 따라서 이러한 초음파 소견이 있을 때 갑상선 기능 및 자가면역항체 검사를 시행해보기를 추천해 볼 수 있겠다.

¹서남대학교 의과대학 명지병원 영상의학과, ²가톨릭관동대학교 의과대학 영상의학과,

³가톨릭관동대학교 국제성모병원 영상의학과, ⁴인제대학교 일산백병원 혈액종양내과,

⁵성균관대학교 의과대학 강북삼성병원 영상의학과