



## Acute Aortic Thrombosis Following Capecitabine Chemotherapy in a Patient with Colon Cancer

### Capecitabine 항암요법 후 발생한 급성 대동맥 혈전

Min Kyung Lee, MD<sup>1†</sup>, Eun Young Kim, MD<sup>1†</sup>, Young Saing Kim, MD<sup>2\*</sup>, Sun Jin Sym, MD<sup>2</sup>, Jeong Ho Kim, MD<sup>1</sup>

Departments of <sup>1</sup>Radiology, <sup>2</sup>Internal Medicine, Gachon University Gil Medical Center, Incheon, Korea

The elevated risk for thromboembolic events in cancer patients has been well documented. Chemotherapy is considered to be one of the most important risk factors for cardiovascular complications such as arrhythmias, cardiomyopathy, angina, and myocardial infarction. However, acute aortic thrombosis is an extremely rare complication in patients receiving chemotherapy. The authors report a case of acute aortic thrombosis after adjuvant capecitabine chemotherapy for colon cancer.

#### Index terms

Capecitabine

Acute Mesenteric Arterial Thrombosis

5-FU

Received January 31, 2018

Revised March 12, 2018

Accepted May 1, 2018

\*Corresponding author: Young Saing Kim, MD  
Department of Internal Medicine, Gachon University  
Gil Medical Center, 21 Namdong-daero 774beon-gil,  
Namdong-gu, Incheon 21565, Korea.  
Tel. 82-32-460-3060 Fax. 82-32-460-3065  
E-mail: zoomboom@hanmail.net

This is an Open Access article distributed under the terms of the Creative Commons Attribution Non-Commercial License (<http://creativecommons.org/licenses/by-nc/4.0>) which permits unrestricted non-commercial use, distribution, and reproduction in any medium, provided the original work is properly cited.

<sup>†</sup>These authors contributed equally to this work.

## INTRODUCTION

Patients with malignancy are at increased risk for vascular thromboembolism; thromboembolic events are a significant cause of morbidity and mortality (1). In patients undergoing chemotherapy, the risk for thromboembolism is approximately six times higher than that in the non-cancer population (1), and most of these thrombotic events occur in the venous system. Although the incidence of arterial thromboembolism is lower, it has, nevertheless, been reported to be 3.8% among cancer patients (2).

Capecitabine is an oral prodrug of 5-fluorouracil (5-FU), which is commonly used to treat gastric, colon, and breast cancers. The most common complications associated with capecitabine administration are hand-foot syndrome, neutropenia, fatigue and gastrointestinal symptoms, such as, diarrhea,

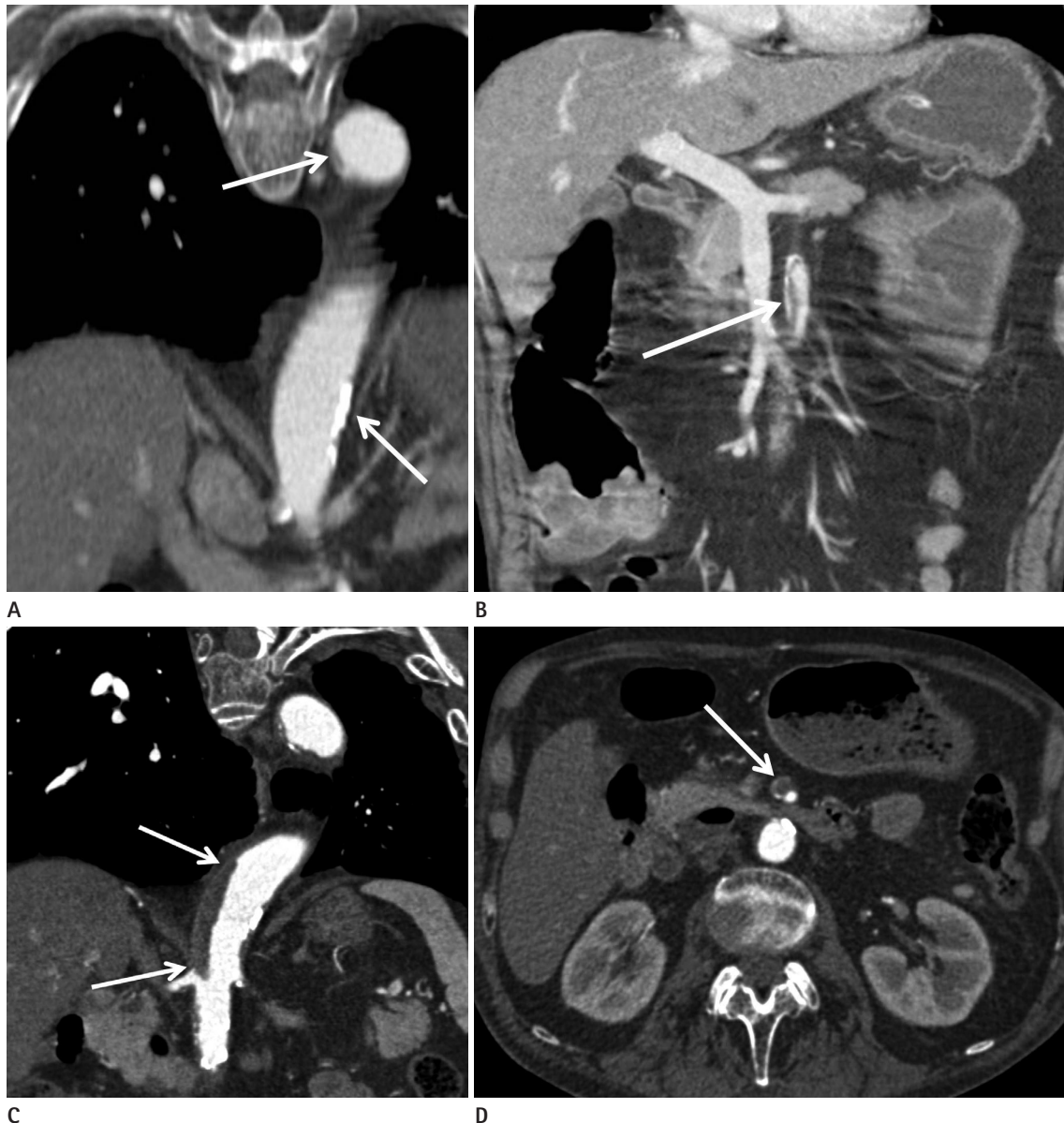
vomiting, nausea, and abdominal pain (3). Cardiovascular complications are uncommon; however, cardiac toxicities, such as arrhythmias, cardiomyopathy, angina, and myocardial infarction, have been reported (4). However, acute aortic thrombus is an extremely rare toxicity that requires early diagnosis and prompt treatment because it can be a potential source of cerebral, visceral, or lower extremity emboli. We report a case of acute aortic thrombosis in a patient who underwent capecitabine treatment for colon cancer.

## CASE REPORT

A 63-year-old man was diagnosed with adenocarcinoma in the ascending colon and associated bowel obstruction. Right hemicolectomy was performed and pathologic staging revealed stage IIA (pT3N0M0) disease. His medical history included hy-

pertension, pulmonary tuberculosis, and chronic obstructive pulmonary disease. Two months after surgery, he underwent adjuvant chemotherapy with capecitabine monotherapy (1250 mg/m<sup>2</sup> twice daily on days 1–14, every 3 weeks). At the time of colon cancer diagnosis, initial computed tomography (CT) revealed atherosclerotic change in the aorta and superior mesenteric artery (SMA) (Fig. 1A, B). After the second cycle of chemotherapy, he developed anorexia and asthenia. Physical

examination revealed only ulcers in the oral cavity, and laboratory findings revealed mild leukocytosis (white cell count, 10520/mm<sup>3</sup>) and a slightly increased prothrombin time (PT, 16.6 sec). At a routine surveillance CT examination, long segmental, irregular, low-attenuation was observed in the right wall of the descending thoracic aorta and suprarenal abdominal aorta, suggestive of *in situ* arterial thrombosis (Fig. 1C), with acute thrombosis evident in the SMA (Fig. 1D). There was no



**Fig. 1.** Acute aortic thrombosis following capecitabine chemotherapy in a 63-year-old man with colon cancer.

**A, B.** At the time of diagnosis, contrast-enhanced CT imaging revealed mild atherosclerosis in the aorta (arrows in **A**) and superior mesenteric artery (arrows in **B**).

**C, D.** After the second cycle of capecitabine chemotherapy (**C**), contrast-enhanced coronal CT imaging revealed a long segmental thrombus (arrows) at the right aortic wall involving a region from the distal descending thoracic to the suprarenal abdominal aorta. (**D**) Contrast-enhanced axial CT image revealing thrombus (arrow) at the superior mesenteric artery.

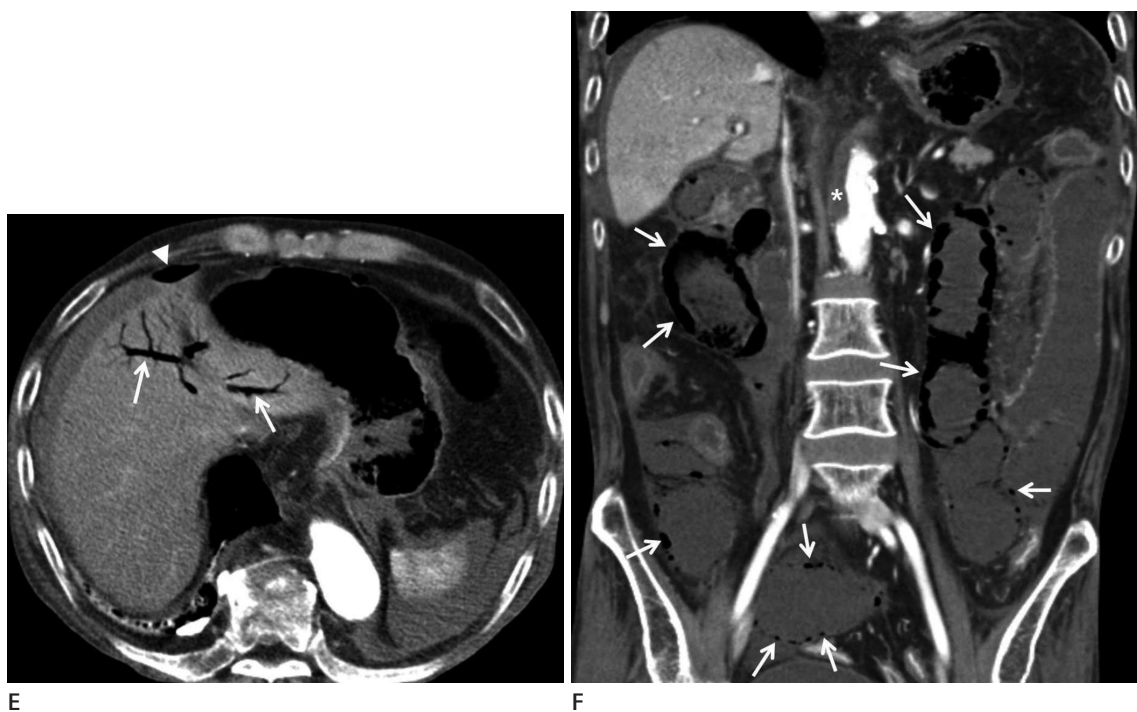
evidence of perfusion abnormality in the abdominal solid organs or bowel. The patient was treated conservatively with acetylsalicylic acid and clopidogrel, and continued to take capecitabine.

After 2 months of further treatment, the patient visited the emergency department of the authors' institution complaining of severe abdominal pain and distension. At the time of admission, his systolic blood pressure was 80 mm Hg. Complete blood count revealed a white cell count of 1760/ $\mu$ L, a hemoglobin level of 10.9 g/dL, and a platelet count of  $46 \times 10^3/\mu$ L. Coagulation tests revealed a prolonged PT (32.4 sec), an elevated activated partial thromboplastin time (57.7 sec), normal fibrinogen levels, an increased D-dimer concentration (3.02 ug/mL), and decreased antithrombin III activity (21%). An abdominal CT scan revealed diffuse small bowel wall necrosis with pneumatosis intestinalis (Fig. 1E, F). At emergency exploratory laparotomy, the entire small bowel was necrotic and nonviable; consequently, an open-and-close operation was performed. The patient was then treated conservatively but died four days later.

## DISCUSSION

We report a case of long segmental, acute aortic thrombus that developed in a patient with colon cancer after a second cycle of capecitabine chemotherapy. Arterial thrombosis is rare, and is usually associated with underlying atherosclerosis and/or aneurysmal change (5). At the time of colon cancer diagnosis, baseline CT revealed atherosclerotic changes in the aorta and SMA, presumably related to older age, hypertension, and tobacco smoking. Mesenteric artery stenosis is usually due to atherosclerosis, and results in insufficient blood flow to the small intestine, causing chronic intestinal ischemia (5).

Chemotherapy is a well-known risk factor for thromboembolism in cancer patients; however, in most cases, it involves the venous system (1). *In situ* arterial thrombosis is rarely associated with cytotoxic chemotherapy, and is regarded to be a potential side effect of anti-angiogenic therapies. The risk for arterial thrombosis in patients undergoing vascular endothelial growth factor (VEGF) receptor-targeted therapy has been reported to be approximately twice that of control patients (6, 7). Bevac-



**Fig. 1.** Acute aortic thrombosis following capecitabine chemotherapy in a 63-year-old man with colon cancer.

**E, F.** Follow-up CT imaging performed after 2 months of treatment with anticoagulant and capecitabine chemotherapy. At this time, the patient visited the emergency department complaining of severe abdominal pain and distension. **(E)** Contrast-enhanced axial image revealing portal vein gas (arrows) and pneumoperitoneum (arrowhead). **(F)** Coronal image revealing gas tracks along the bowel wall, appearing as either linear or rounded cystic collections (arrows), suggestive of pneumatosis intestinalis. Long segmental thrombus (asterisk) remained present in the aorta.

zumab is a recombinant humanized monoclonal antibody against VEGF, and is used in combination chemotherapy for metastatic colorectal cancer. Although the exact mechanism has not been documented, VEGF acts to maintain the integrity of the vascular endothelium (6, 7).

Capecitabine is an anti-metabolite, oral prodrug of 5-FU, and arterial thrombosis has been reported to be an uncommon adverse event following 5-FU chemotherapy (4). Furthermore, 5-FU can increase fibrinopeptide A levels and reduce protein C activity and, thus, render blood vessels more susceptible to thrombus formation. In addition, the vascular endothelium is susceptible to free radicals generated by 5-FU, and several animal studies have reported endothelial damage caused by 5-FU (8).

Because complications of arterial thromboembolism (abdominal organ and limb ischemia) are usually fatal, early diagnosis and treatment is imperative. The use of low-dose acetylsalicylic acid is recommended for prophylaxis in high-risk patients without contraindications to its use (9). Thrombolysis, anticoagulation, and surgery could be considered treatment options for arterial thromboembolism; however, the continuance of chemotherapy in patients with chemotherapy-induced thrombosis is controversial. Clinical decision making based on considerations of risks and benefits of further chemotherapy is difficult. Previous study suggested that arterial embolism can often be managed successfully using conservative management, and that further treatment with the same chemotherapy regimen is possible with minimal interruption (10). However, considering the fatal outcome of arterial thrombosis in our case, further evidence supporting the safety of ongoing treatment is still needed.

In conclusion, capecitabine-induced aortic thrombosis is a rare but important complication. Physicians who treat patients with capecitabine need to be mindful of the possibility of arterial thrombosis, especially in patients with underlying atherosclerosis.

## REFERENCES

1. Heit JA, Silverstein MD, Mohr DN, Petterson TM, O'Fallon WM, Melton LJ 3rd. Risk factors for deep vein thrombosis and pulmonary embolism: a population-based case-control study. *Arch Intern Med* 2000;160:809-815
2. Doganci S, Kadan M, Kaya E, Erol G, Gunay C, Demirkilic U. Acute arterial thrombosis following chemotherapy in a patient with a gastric carcinoma. *Cardiovasc J Afr* 2013;24:e7-e9
3. Ilich AI, Danilak M, Kim CA, Mulder KE, Spratlin JL, Ghosh S, et al. Effects of gender on capecitabine toxicity in colorectal cancer. *J Oncol Pharm Pract* 2016;22:454-460
4. Sorrentino MF, Kim J, Foderaro AE, Truesdell AG. 5-fluorouracil induced cardiotoxicity: review of the literature. *Cardiol J* 2012;19:453-458
5. Previtali E, Bucciarelli P, Passamonti SM, Martinelli I. Risk factors for venous and arterial thrombosis. *Blood Transfus* 2011; 9:120-138
6. Eskens FA, Verweij J. The clinical toxicity profile of vascular endothelial growth factor (VEGF) and vascular endothelial growth factor receptor (VEGFR) targeting angiogenesis inhibitors; a review. *Eur J Cancer* 2006;42:3127-3139
7. Scappaticci FA, Skillings JR, Holden SN, Gerber HP, Miller K, Kabbinavar F, et al. Arterial thromboembolic events in patients with metastatic carcinoma treated with chemotherapy and bevacizumab. *J Natl Cancer Inst* 2007;99:1232-1239
8. Cwikiel M, Zhang B, Eskilsson J, Wieslander JB, Albertsson M. The influence of 5-fluorouracil on the endothelium in small arteries. An electron microscopic study in rabbits. *Scanning Microsc* 1995;9:561-576
9. Patrono C, Collier B, FitzGerald GA, Hirsh J, Roth G. Platelet-active drugs: the relationships among dose, effectiveness, and side effects: the Seventh ACCP Conference on antithrombotic and thrombolytic therapy. *Chest* 2004;126(3 Suppl):234S-264S
10. Tait CD, Rankin EM. Arterial emboli complicating cisplatin therapy. *Case Rep Oncol Med* 2012;2012:276385

## Capecitabine 항암요법 후 발생한 급성 대동맥 혈전

이민경<sup>1</sup> · 김은영<sup>1</sup> · 김영생<sup>2\*</sup> · 심선진<sup>2</sup> · 김정호<sup>1</sup>

암 환자에서 혈전 색전증의 위험이 증가하며, 항암 화학 치료는 심혈관 합병증(부정맥, 심근증, 협심증, 심근경색 등)의 중요한 위험 요인 중 하나이다. 급성 대동맥 혈전증은 항암 화학 요법을 받고 있는 암 환자에게 극히 드물게 나타나는 합병증이다. 저자는 대장암에 대한 보조 항암 화학요법으로 capecitabine 경구 치료 중 급성 대동맥 혈전증이 발생한 경우를 보고한다.

가천대학교 길병원 <sup>1</sup>영상의학과, <sup>2</sup>내과