

## Nodo-Colonic Fistula Caused by Intra-Abdominal Tuberculous Lymphadenitis during Treatment with Anti-Tuberculous Medication: A Case Report

항결핵제 치료 중 복강 내 결핵성 림프절병증에서 발생한 림프절-대장 누공: 증례 보고

Kyungsun Nam, MD, Kyung Eun Bae, MD\*, Myeong Ja Jeong, MD, Ji Hae Lee, MD, Mi-Jin Kang, MD, Jae Hyung Kim, MD, Soo Hyun Kim, MD

Department of Radiology, Sanggye Paik Hospital, Inje University College of Medicine, Seoul, Korea

Recently, the overall incidence of tuberculosis has decreased, but the incidence of an extrapulmonary manifestation in patients with tuberculosis has increased in the Republic of Korea. Although intestinal tuberculosis is not infrequent, a fistula caused by tuberculosis is a rare condition. A 23-year-old man presented with fever, diarrhea and right lower quadrant pain. A computed tomography (CT) scan revealed a lobulated, peripherally enhancing, low density mass in the mesentery. The patient underwent laparoscopic biopsy for necrotic lymph node, and intra-abdominal tuberculous lymphadenitis was diagnosed. Four months after initiating treatment with anti-tuberculous medication, the patient developed fever together with lower abdominal pain. A follow-up CT scan revealed a fistulous tract that had developed between the initially noted lymphadenopathy and the proximal ascending colon. Laparoscopic right hemicolectomy was performed as a curative treatment. This case suggests that a nodo-colonic fistula may occur as a paradoxical response in patients with intra-abdominal tuberculous lymphadenitis during treatment with anti-tuberculous medication.

### Index terms

Tuberculosis  
Fistula  
Lymph Node  
Colon  
Lymphadenitis

Received February 19, 2016

Revised March 25, 2016

Accepted April 8, 2016

\*Corresponding author: Kyung Eun Bae, MD  
Department of Radiology, Sanggye Paik Hospital,  
Inje University College of Medicine,  
1342 Dongil-ro, Nowon-gu, Seoul 01757, Korea.  
Tel. 82-2-950-1184 Fax. 82-2-950-1220  
E-mail: s2671@paik.ac.kr

This is an Open Access article distributed under the terms of the Creative Commons Attribution Non-Commercial License (<http://creativecommons.org/licenses/by-nc/3.0>) which permits unrestricted non-commercial use, distribution, and reproduction in any medium, provided the original work is properly cited.

## INTRODUCTION

In the Republic of Korea, the incidence of tuberculosis has decreased due to early diagnosis and treatment of pulmonary tuberculosis, improvement of nutritional status, and better public health (1). The incidence of extrapulmonary manifestation in patients with tuberculosis has increased compared to that in the past with 13.7 patients for every 100000 people in 2014 (2, 3). Abdominal tuberculosis is the most common condition of extra-

pulmonary tuberculosis, and lymphadenopathy is the most common form of abdominal tuberculosis (4). Fistulous tract formation caused by intestinal tuberculosis is rare, and fistula formation due to intra-abdominal lymphadenitis is even rarer. We report a case of nodo-colonic fistula caused by intra-abdominal tuberculous lymphadenitis during treatment with anti-tuberculous medication.

## CASE REPORT

A 23-year-old man was referred to our hospital because of right lower quadrant pain and diarrhea. The patient presented with complaints of fever and abdominal pain for about two weeks prior. No abnormality was detected on colonoscopy, which was performed at another hospital. The patient presented with a blood pressure of 120/80 mm Hg, pulse rate of 88/min, and body temperature of 38.1°C. Laboratory findings showed mild elevation of inflammatory markers such as the erythrocyte sedimentation rate and C-reactive protein level. Culture of blood and urine samples showed negative results. Findings suggestive of pulmonary tuberculosis were not detected on plain radiographs of the chest or on a sputum smear and culture for acid-fast bacilli.

An abdominal computed tomography (CT) scan revealed a lobulated, peripherally enhancing, low density mass in the mesentery of the right lower quadrant, indicating necrotic lymphadenopathy (Fig. 1A). The patient underwent a laparoscopic biopsy to confirm the diagnosis. Laparoscopic excision was not feasible because of the presence of severe adhesions. Moreover, examination of intraoperative frozen sections revealed a granuloma, suggestive of tuberculosis. Histopathological examination showed chronic granulomatous inflammation with necrosis, and a polymerase chain reaction test for *Mycobacterium tuberculosis* was positive. The diagnosis was confirmed as tuberculous lymphadenitis, and anti-tuberculous treatment with isoniazid, rifampicin, ethambutol, and pyrazinamide was administered.

Symptoms improved initially, but after four months, the patient suddenly developed fever, chills, and lower abdominal pain. The patient underwent a follow-up CT scan for evaluation of the previous lymphadenopathy. The CT scan showed that the previous tuberculous lymphadenopathy had increased in size and now contained tiny air bubbles. Fistula formation was noted between the lymphadenopathy and the proximal ascending colon (Fig. 1B, C). The patient underwent laparoscopic right hemicolectomy. Histopathological examination revealed chronic granulomatous inflammation with necrosis associated with tuberculosis and its involvement with the intestinal wall, pericolic soft tissue, and lymph nodes (Fig. 1D-F). The fistulous tract between the tuberculous lymphadenopathy and the proximal ascending colon was also observed on the gross specimen. After a few weeks, the symptoms were relieved. They were attributed to the abscess and

the fistula. The patient took anti-tuberculous medication for 6 months and was followed clinically.

## DISCUSSION

In 2014, the number of newly notified patients with tuberculosis in the Republic of Korea was 34869 cases (68.7 patients per every 100000 persons) and about one-fifth of them (6963 cases; 13.7 patients per every 100000 persons) had extrapulmonary manifestations (3, 5). Abdominal tuberculosis is the most common form of extrapulmonary tuberculosis, and lymphadenopathy is the most common manifestation of abdominal tuberculosis (4). On the CT scans, the majority with lymphadenitis showed enlarged lymph nodes with central low attenuation and a peripheral enhancing rim. Other observations include a conglomerate mass, enlarged homogeneous attenuated lymph nodes, and several small homogeneous lymph nodes. This case was considered primary intra-abdominal tuberculous lymphadenitis with no evidence of pulmonary tuberculosis.

Nagi et al. (6) reported that 7.6 percent of patients with gastrointestinal tuberculosis had localized perforation and fistula. Fistula may form anywhere near the site of gastrointestinal tuberculosis, but the most common location is the ileum. Rare cases of tuberculous fistulas have been seen in the Republic of Korea. A case of choledocho-duodenal fistula, two cases of intestinal tuberculosis with a duodenal fistula, and two cases of nododuodenal fistula have been reported (7, 8).

In this case, the diagnosis was a confirmed tuberculous lymphadenitis by the initial biopsy examination, and clinical improvement with anti-tuberculous medication was expected. Although the symptoms were relieved initially, the patient subsequently developed severe abdominal pain. The follow-up CT scan showed the formation of an intra-abdominal abscess and fistula which were managed surgically.

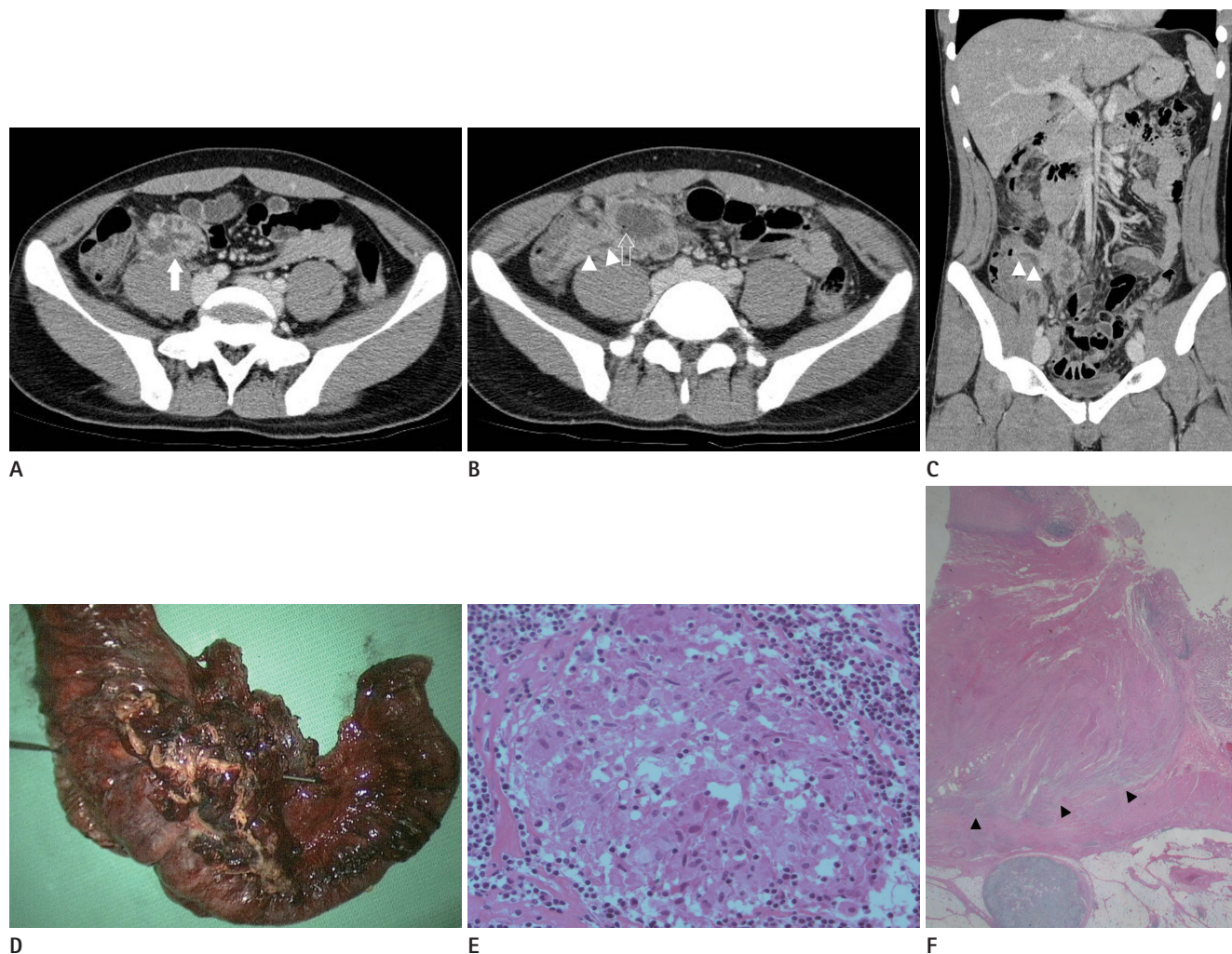
Cho et al. (9) reported paradoxical responses in non-HIV-infected patients with peripheral lymph node tuberculosis. Although these patients did not have intra-abdominal tuberculous lymphadenitis, 20% of patients with lymphadenopathy in the cervical, submandibular, axillary and inguinal areas showed paradoxical responses after receiving anti-tuberculous medication. Increasing size of the enlarged lymph nodes, discharging sinuses, and new enlarged lymph nodes were noted. In this case, it was

presumed that the tuberculous lymphadenitis, in the healing process, lead to the formation of the intra-abdominal abscess and the fistulous tract to the proximal ascending colon. This observation, corresponding to the two cases of nododuodenal fistula during anti-tuberculous treatment, was regarded as a paradoxical response of tuberculous lymphadenitis to the medication.

Generally, the mainstay of treatment for a fistula caused by intestinal tuberculosis is conservative management, including anti-

tuberculous medication. Surgical management may be considered based on clinical symptoms. Spontaneous closure of the fistula may not occur even after four or six weeks of treatment (10).

In conclusion, this is a rare case of fistula formation, extending from intra-abdominal tuberculous lymphadenitis to the proximal ascending colon during anti-tuberculous treatment. To the best of our knowledge, there is no published literature describing a nodo-colonic fistula. It is crucial for radiologists to know the



**Fig. 1.** A 23-year-old male patient with a diagnosis of intra-abdominal tuberculous lymphadenitis.

**A.** Initial abdominal CT scan demonstrates a lobulated, peripherally enhancing low-density mass (arrow) in the mesentery of the right lower quadrant.

**B.** Follow-up abdominal CT scan obtained four months later, shows an increase in the size of the mass, development of internal tiny air bubbles (empty arrow), and a fistulous tract (arrowheads).

**C.** Coronal reconstructed CT scan shows a fistulous tract extending to the proximal ascending colon (arrowheads).

**D.** Gross specimen obtained in the operation room shows a penetrating rod in accordance with the fistulous tract.

**E.** Histopathologic feature on this photomicrograph shows a pink, amorphous region in the center of a granuloma ringed by epithelioid cells, suggesting caseous necrosis (hematoxylin-eosin stain; high power field).

**F.** Another macroscopic view shows mural defects (arrowheads) suggesting fistula formation in the proximal ascending colon (hematoxylin-eosin stain; low power field).

CT = computed tomography

various manifestations of tuberculosis in a country where it is endemic. A tuberculous fistula could be cured by conservative treatment. Therefore, radiologists might advise surgeons regarding the treatment options, thus preventing unnecessary surgeries.

## REFERENCES

1. Kwon DY, Park HW, Seo SH, Jang BK, Hwang JY, Lee JM, et al. A case of duodenal fistula caused by intestinal tuberculosis. *Korean J Gastrointest Endosc* 2004;28:131-135
2. Kim HJ. Current status of tuberculosis in Korea. *Korean J Med* 2012;82:257-262
3. Korea Centers for Disease Control and Prevention. *Annual report on the notified tuberculosis in Korea, 2014. Notified tuberculosis status in Korea, 2014*. Cheongju: Korea Centers for Disease Control and Prevention, 2015
4. Burrill J, Williams CJ, Bain G, Conder G, Hine AL, Misra RR. Tuberculosis: a radiologic review. *Radiographics* 2007;27:1255-1273
5. Kim KS, Cha SH, Ahn JH, Cho MY. A large tuberculous abscess mimicking a retroperitoneal cystic mass: a case report. *J Korean Soc Radiol* 2015;72:202-205
6. Nagi B, Lal A, Kochhar R, Bhasin DK, Thapa BR, Singh K. Perforations and fistulae in gastrointestinal tuberculosis. *Acta Radiol* 2002;43:501-506
7. Lee KR, Seo KS, Cheo JH, Choi SC, Kim K, Yim YG, et al. A case of duodenal fistula caused by intra-abdominal tuberculous lymphadenopathy during anti-tuberculous medication. *Korean J Gastrointest Endosc* 2008;37:433-437
8. Lee DG, Kim GH. Nododuodenal fistula caused by tuberculosis. *Korean J Intern Med* 2011;26:477
9. Cho OH, Park KH, Kim T, Song EH, Jang EY, Lee EJ, et al. Paradoxical responses in non-HIV-infected patients with peripheral lymph node tuberculosis. *J Infect* 2009;59:56-61
10. Wong WM, Lai KC, Yiu WC, Wong BC, Chan FL, Lai CL. Intestinal tuberculosis mimicking fistulizing Crohn's disease. *J Gastroenterol Hepatol* 2007;22:137-139

## 항결핵제 치료 중 복강 내 결핵성 림프절병증에서 발생한 림프절-대장 누공: 증례 보고

남경선 · 배경은\* · 정명자 · 이지혜 · 강미진 · 김재형 · 김수현

최근 결핵의 전반적인 발병률은 감소하고 있으나 폐외결핵 환자의 비율은 한국에서 증가하고 있다. 장결핵은 드물지 않게 발생하지만 결핵으로 인한 누공은 흔하지 않다. 23세 남자가 발열, 설사, 우하복부 통증을 보였다. CT에서 과사성 림프절이 관찰되었고 복강경을 이용한 조직생검에서 복강내 결핵성 림프절염으로 진단되었다. 항결핵제 치료를 시작하고 4개월 뒤 환자는 갑자기 열감과 하복부 통증을 호소하였다. CT에서는 이전에 있던 림프절병증과 근위 상행결장 간의 누공이 관찰되었다. 복강경하 우측 대장절제술을 시행한 후 증상은 호전되었다. 본 증례는 항결핵제 복용 중 복강내 결핵성 림프절병증 환자에서 역설적으로 림프절-대장 누공이 발생할 수 있다는 것을 보여준다.

인제대학교 의과대학 상계백병원 영상의학과