

Primary Diffuse Large B Cell Lymphoma Developing at the Ileocolonic Anastomosis Site after Right Hemicolectomy for Adenocarcinoma: A Case Report

대장암으로 우반결장절제술을 시행한 환자의 회장-결장문합부위에서 생긴 원발성 미만성 대세포 B형 임파종 1예: 증례 보고

Hye Yeon Oh, MD, Seung Joon Choi, MD, Hyung Sik Kim, MD, Jeong Ho Kim, MD, Hye-Young Choi, MD

Department of Radiology, Gachon University Gil Hospital, Incheon, Korea

Lymphoma is rarely associated with ileocolonic surgery. We report the imaging findings of primary diffuse large B-cell lymphoma arising in an ileocolonic anastomosis site, found five years after a right hemicolectomy for adenocarcinoma in the ascending colon.

Index terms

Diffuse Large B Cell Lymphoma
Right Hemicolectomy
Adenocarcinoma

Received December 9, 2013; Accepted January 7, 2014

Corresponding author: Seung Joon Choi, MD
Department of Radiology, Gachon University Gil Hospital, 21 Namdong-daero 774beon-gil, Namdong-gu, Incheon 405-760, Korea.
Tel. 82-32-460-3060 Fax. 82-32-460-3065
E-mail: sjchoi@gilhospital.com

This is an Open Access article distributed under the terms of the Creative Commons Attribution Non-Commercial License (<http://creativecommons.org/licenses/by-nc/3.0>) which permits unrestricted non-commercial use, distribution, and reproduction in any medium, provided the original work is properly cited.

INTRODUCTION

Lymphoma is rarely associated with pouch surgery. To date, only five reports in the literature described lymphoma in an ileal pouch for ulcerative colitis (1-5) and only two papers reported about lymphoma in the anastomosis site for colonic adenocarcinoma which were anaplastic large cell lymphoma and T-cell lymphoma (6, 7). We report a very rare case of primary diffuse large B-cell lymphoma (DLBL) arising in an ileocolonic anastomosis site which was found five years after a right hemicolectomy for adenocarcinoma in the ascending colon.

CASE REPORT

A 72-year-old man underwent a right hemicolectomy for adenocarcinoma of the ascending colon in 2007. During the surgery a 2.5 × 1.5 cm fungating mass was revealed 8 cm below the

ileocecocolic valve. The pathology report described a well-differentiated adenocarcinoma arising in a villous adenoma with 3.0 × 2.0 cm size and the involvement of ascending colon, terminal ileum and appendix and also with an invasion to the submucosa without lymph node metastasis.

In 2012, the patient presented for his annual endoscopy without any symptoms. However, the endoscopy revealed an ulcerofungating mass at the ileocolonic anastomosis site (Fig. 1A) and the computed tomography (CT) scan showed an enhancing mass with regional enlarged lymph nodes in the anastomosis site (Fig. 1B). Additionally, positron emission tomography showed hypermetabolism in the anastomosis site. However, no hypermetabolism was found in other organs or lymph nodes. Histological results of the endoscopic biopsy revealed massive infiltration by large lymphoid elements diagnosed as a malignant lesion (Fig. 1C, D). Immunohistochemistry was positive for the B-cell marker CD20 (Fig. 1E), but negative for the T-cell marker CD3

(Fig. 1F). The immunohistochemical features were compatible with a diagnosis of DLBL.

The patient underwent a combined chemotherapy with a 12 months treatment duration, starting with the rituximab, cyclophosphamide, doxorubicin, vincristine and prednisolone schedule for DLBL (Ann-Arbor stage IIEA). Follow-up colonoscopy and CT scan revealed over intervals a marked decrease of the lymphoma size and a nearly complete remission at the anastomo-

sis site (Fig. 1G, H).

DISCUSSION

Usually, a recurrent tumor in an anastomotic site is the same kind of primary malignant tumor as at the resection site. Almost all recurrent malignant tumors presenting in the colectomy are adenocarcinoma, whereas the occurrence of primary

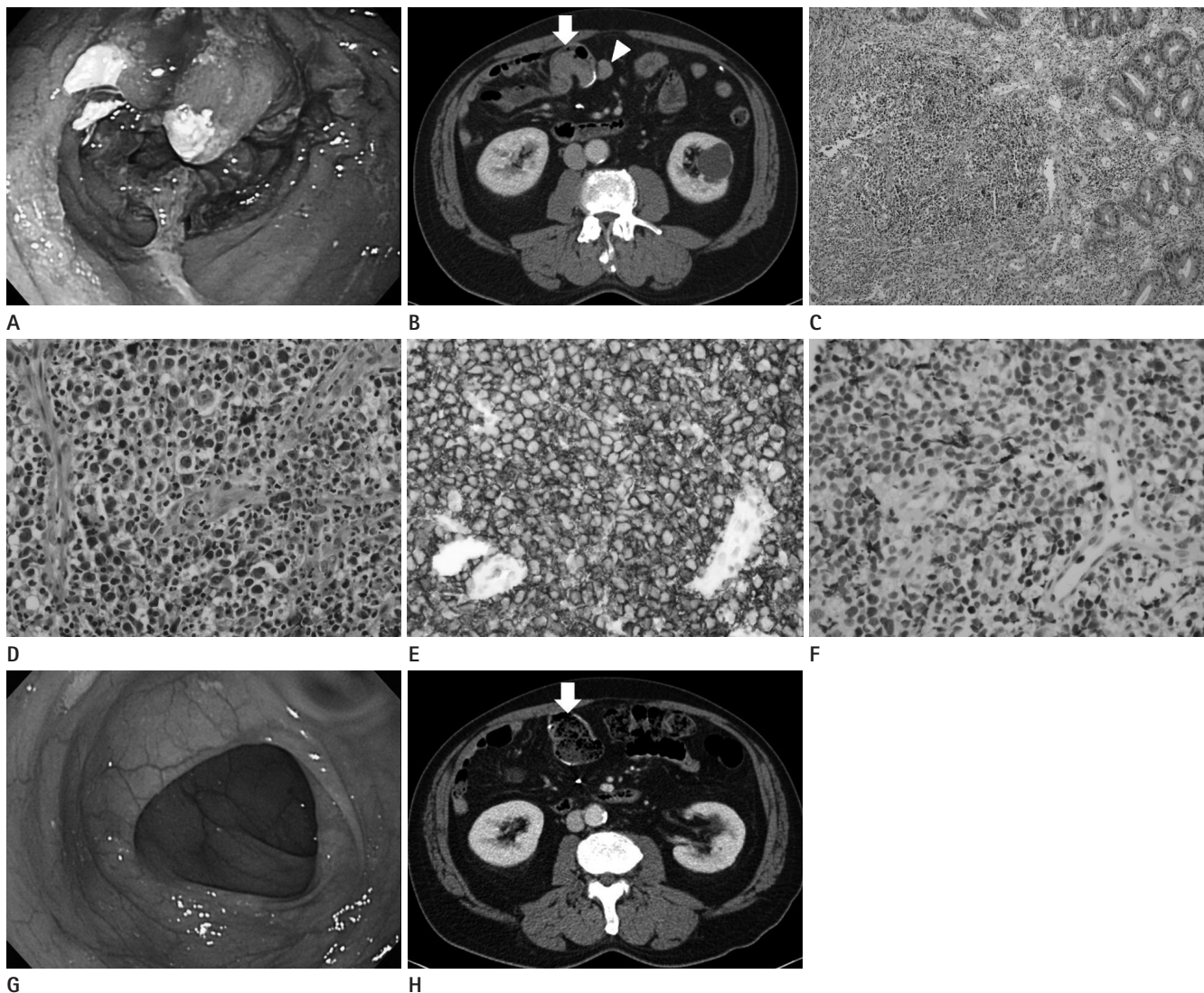


Fig. 1. A 72-year-old man underwent a right hemicolectomy for adenocarcinoma of the ascending colon five years ago.

A. Colonoscopy shows ulcerofungating mass at the ileocolonic anastomosis site.

B. Contrast-enhanced CT shows enhancing mass within the colon at the ileocolonic anastomosis site (arrow) with regional enlarged lymph node (arrowhead).

C-F. Microscopic examination shows diffuse infiltration of large lymphoid cells with small multiple nucleoli [H&E, x 100 (**C**), x 400 (**D**)], which were positive at B-cell marker for CD20 (**E**) and negative at T-cell marker, CD3 (**F**).

G. Colonoscopy after combination chemotherapy shows nearly complete remission state of the tumor at the ileocolonic anastomosis site.

H. Contrast-enhanced CT after combination chemotherapy shows marked regression of the tumor at the anastomosis site (arrow) with resolution of adjacent lymph node.

lymphoma is exceptionally rare. Recurrences are presumably caused by implantation of exfoliated cancer cells liberated at the time of operation and metachronous carcinogenesis. These recurrent tumors are invariably adenocarcinoma (1, 8).

The gastrointestinal tract is the most common site of all primary extranodal lymphoma, accounting for roughly 5% of non-Hodgkin's lymphoma. Gastrointestinal lymphoma is nonetheless a rare tumor, with an incidence of 1.6 per million annually (9). It is well known that inflammatory conditions such as ulcerative colitis (UC) can provide a basis for the development of colon cancer. Lymphoma occurring with underlying inflammatory bowel disease (IBD) have been well documented in the literature (9). Acquired immunodeficiency syndrome, immunosuppression and inflammatory bowel disease are predisposing conditions for gastrointestinal lymphoma (1, 3, 5, 9).

The literature of five cases in which lymphomas arose at the ileal pouch after UC surgery and of two cases at the ileal pouch after adenocarcinoma surgery was reviewed. The histologic types of lymphoma underlying UC were large cell lymphoma, low and high grade B-cell lymphoma and two cases of DLBL. In 2001, Cooperberg and Fiedler (6) reported about lymphoma in the ileal pouch 10 years after surgery for adenocarcinoma. The histological type of the lymphoma was an anaplastic large cell carcinoma. Ikeda et al. (7) described peripheral T-cell lymphoma developing after surgery for adenocarcinoma at the ileocolonic anastomosis site. There was no evidence of an underlying IBD or a recurrent colonic adenocarcinoma. In our case, the histologic type of lymphoma was DLBL without pouchitis or underlying IBD. The patient was not immunosuppressed and received surgery for ascending colon cancer only. There was no involvement of any other organs in the lymphoma, so the primary lymphoma was diagnosed at the ileocolonic anastomosis site.

Lymphoma developing at the gastrectomy site for benign ulcer or adenocarcinoma usually is a high grade B-cell lymphoma associated with *Helicobacter pylori* (*H. pylori*). Where the infection is negative for *H. pylori*, chronic exposure of bile and duodenal reflux developing after distal gastrectomy seems associated with chronic gastritis and is replaced by intestinal metaplasia and gives rise to a gastric neoplasm often (10). However, the mechanism of lymphoma developing at the ileal pouch anal anastomosis after colonic adenocarcinoma remains still unclear.

In summary, an extremely rare case of DLBL at the site of ileo-

colonic anastomosis was presented by us. This case is not associated with UC and was found five years after the complete resection of a colonic adenocarcinoma. Adequate attention should be given to the potential occurrence of malignant lymphoma during the examination of a residual colon after colectomy.

REFERENCES

1. Nyam DC, Pemberton JH, Sandborn WJ, Savchenko M. Lymphoma of the pouch after ileal pouch-anal anastomosis: report of a case. *Dis Colon Rectum* 1997;40:971-972
2. Frizzi JD, Rivera DE, Harris JA, Hamill RL. Lymphoma arising in an S-pouch after total proctocolectomy for ulcerative colitis: report of a case. *Dis Colon Rectum* 2000;43:540-543
3. Jones OM, McCutcheon J, Herieka E, Fozard JB. High-grade lymphoma of the ileoanal pouch in an HIV-positive patient. *Colorectal Dis* 2007;9:184-185
4. Cosentino JS, Davies RJ, McLeod RS, Cohen Z. Lymphoma following ileal pouch anal anastomosis. *Can J Surg* 2009;52:E123-E126
5. Schwartz LK, Kim MK, Coleman M, Lichtiger S, Chadburn A, Scherl E. Case report: lymphoma arising in an ileal pouch anal anastomosis after immunomodulatory therapy for inflammatory bowel disease. *Clin Gastroenterol Hepatol* 2006;4:1030-1034
6. Cooperberg MR, Fiedler PN. Ki-1 anaplastic large-cell lymphoma occurring at the site of ileocolonic anastomosis in a patient treated surgically for colonic adenocarcinoma: case report and review of the literature. *Ann Diagn Pathol* 2001;5:162-167
7. Ikeda J, Yamauchi A, Hoshida Y, Okamura S, Hashimoto K, Aozasa K, et al. Peripheral T-cell lymphoma developing at ileocolonic anastomosis site after colectomy for adenocarcinoma. *Pathol Res Pract* 2010;206:376-378
8. Umpleby HC, Williamson RC. Anastomotic recurrence in large bowel cancer. *Br J Surg* 1987;74:873-878
9. Richards MA. Lymphoma of the colon and rectum. *Postgrad Med J* 1986;62:615-620
10. Greco L, Marino F, Troilo VL, Marzullo A, Gentile A. Gastric stump lymphoma after distal gastrectomy for benign peptic ulcer: report of a case. *Surg Today* 2006;36:985-988

대장암으로 우반결장절제술을 시행한 환자의 회장-결장문합부위에서 생긴 원발성 미만성 대세포 B형 임파종 1예: 증례 보고

오혜연 · 최승준 · 김형식 · 김정호 · 최혜영

회장-결장 수술 부위에서 생긴 임파종은 매우 드물게 보고되고 있다. 저자들은 5년 전 상행결장에 생긴 대장암으로 우반결장절제술을 시행한 환자의 회장-결장문합부위에서 생긴 원발성 미만성 대세포 B형 임파종 1예를 경험하였기에 영상소견을 보고하고자 한다.

가천대학교 의학전문대학원 길병원 영상의학과