

CT, MRI, and ^{18}F -Fluorodeoxyglucose Positron Emission Tomography/CT Features of Primary Mucosal Melanoma Involving the Lacrimal Drainage Apparatus: A Case Report¹

누액배출기관을 침범한 원발성 점막형 흑색종의 전산화단층촬영, 자기공명영상 및 ^{18}F -Fluorodeoxyglucose Positron Emission Tomography/CT Features 소견: 증례 보고¹

Sang Kwon Lee, MD¹, Mi Sun Choe, MD²

Departments of ¹Radiology, ²Pathology, Keimyung University School of Medicine, Daegu, Korea

We report CT, MRI, and initial and follow-up ^{18}F -fluorodeoxyglucose positron emission tomography/CT (^{18}F -FDG PET/CT) features of a case of primary mucosal melanoma of the lacrimal drainage apparatus in a 76-year-old man. The lesion was identified as an enhancing mass of the right lacrimal sac with extension into the inferior meatus through the nasolacrimal duct on CT. It was hyperintense and hypointense compared with gray matter on T1- and T2-weighted images, respectively, and intensely enhanced on gadolinium-enhanced T1-weighted images. Initial ^{18}F -FDG PET/CT demonstrated mild fluorodeoxyglucose uptake of the mass. Surgical biopsy confirmed the diagnosis. Periodic follow-up ^{18}F -FDG PET/CT demonstrated recurrent disease 18 months after surgery and its progression thereafter. In primary mucosal melanoma of the lacrimal drainage apparatus, CT, MRI, and initial and follow-up ^{18}F -FDG PET/CT may be useful for early detection of the lesion and associated bony changes, lesion characterization, initial staging, and surveillance of recurrent and metastatic diseases, respectively.

Index terms

Lacrimal Drainage Apparatus
Primary Mucosal Melanoma
Tomography, X-Ray Computed
Magnetic Resonance Imaging
Positron-Emission Tomography and Computed Tomography

INTRODUCTION

Primary mucosal melanoma of the lacrimal drainage apparatus is an extremely rare entity; only 26 cases have been reported in the literature to date (1-4). It is difficult to distinguish primary mucosal melanoma of the lacrimal drainage apparatus from more common chronic dacryocystitis. As such, early detection of the mass by using imaging is important for improving the chance for survival of the patients with primary mucosal melanoma of the lacrimal drainage apparatus.

The imaging features of primary mucosal melanoma of the lacrimal drainage apparatus reported in the literature are limited to those of one or two modalities only (1-4). As such, imaging features of this rare entity from CT, MRI, and initial and follow-up ^{18}F -fluorodeoxyglucose positron emission tomography/computed tomography (^{18}F -FDG PET/CT) altogether in a single case have not appeared in the literature. We report here a case of primary mucosal melanoma of the lacrimal drainage apparatus in a 76-year-old man, and we include CT, MRI, and initial and periodic follow-up ^{18}F -FDG PET/CT features.

Received June 29, 2013; Accepted November 8, 2013

Corresponding author: Sang Kwon Lee, MD
Department of Radiology, Keimyung University School of Medicine, 56 Dalseong-ro, Jung-gu, Daegu 700-712, Korea.
Tel. 82-53-250-7735 Fax. 82-53-250-7766
E-mail: sklee@dsmc.or.kr

This is an Open Access article distributed under the terms of the Creative Commons Attribution Non-Commercial License (<http://creativecommons.org/licenses/by-nc/3.0>) which permits unrestricted non-commercial use, distribution, and reproduction in any medium, provided the original work is properly cited.

CASE REPORT

A 76-year-old man presented with a mass in the right nasal cavity that had developed 2 months ago. He had experienced right nasal stuffiness, hyposmia, and intermittent posterior nasal drip for 5 months. Approximately 2 months ago, a mass had been detected in the right nasal cavity by an otolaryngologist during rhinologic evaluation for the patient's nasal symptoms at a local medical clinic. The patient denied visual symptoms, and the motion of extraocular muscles was intact. Detailed ophthalmologic investigations were omitted by the otolaryngologist. His past history was unremarkable. Intranasal examination revealed a black, pigmented mass in the right nasal cavity, just below the right inferior turbinate. CT of the sinonasal area, performed using a Sensation 64 scanner (Siemens Healthcare, Forchheim, Germany) with a slice thickness of 2.0 mm revealed a fairly well-demarcated, homogeneously hyperattenuating (compared with brain) soft tissue mass involving the right lacrimal sac, nasolacrimal duct, and inferior meatus (Fig. 1A, B). The involved nasolacrimal duct was widened and eroded (Fig. 1A), and the inferior turbinate was elevated (Fig. 1B) by the mass. While the mass was in direct contact with orbital fat and with the medial wall of the right maxillary sinus and the lateral wall of the right anterior ethmoid sinus, there was no detectable invasion of other orbital structures, maxillary or anterior ethmoid sinus (Fig. 1A-D). The mass showed homogeneous, solid enhancement, following intravenous administration of contrast material (Fig. 1C, D). In view of CT features, our tentative diagnoses were lymphoma; primary mucosal melanoma; minor salivary gland tumor, including mucoepidermoid carcinoma and adenoid cystic carcinoma; and papillomas. Intranasal biopsy demonstrated mucosal melanoma. Preoperative MRI of the head and neck was performed by using a 3.0-T unit (Signa Excite; GE Medical System, Milwaukee, WI, USA). The mass was hypointense to gray matter on fast spin echo T2-weighted images (T2WI) [repetition time (TR)/echo time (TE) = 4000/106; echo train length = 22; matrix number/number of excitation = $512 \times 224/2.0$; slice thickness = 6.0 mm] (Fig. 1E), and hyperintense to gray matter on spine echo (SE) T1-weighted images (T1WI) (TR/TE = 616.7/11.0; matrix number/number of excitation = $320 \times 160/1.0$; slice thickness = 6.0 mm) (Fig. 1F). Intense enhancement was noted on gadolinium-enhanced SE T1WI (TR/TE = 816.7/18.0; matrix number/num-

ber of excitation = $320 \times 128/0.8$; slice thickness = 8.0 mm) with fat saturation (Fig. 1G). Initial staging ^{18}F -FDG PET/CT, performed by using Discovery STE (GE Healthcare, Milwaukee, WI, USA), demonstrated slightly increased fluorodeoxyglucose (FDG) uptake (maximum standardized uptake value = 3.2 g/mL) of the mass at the lacrimal sac (Fig. 1H) and inferior meatus. There were no findings of primary or metastatic melanoma elsewhere in the body on MRI and ^{18}F -FDG PET/CT. He underwent en bloc resection of the mass in the lacrimal drainage apparatus via medial maxillectomy, partial ethmoidectomy, dacryocystectomy, and partial resection of medial orbital floor, lateral nasal wall, and nasal bone. Surgical margins were free of malignant cells. Histological examination revealed that the tumor was composed of large polygonal cells with prominent nucleoli and brownish melanin pigments (Fig. 1I). Immunohistochemically, tumor cells were positive for S-100 protein and HMB-45, consistent with malignant melanoma. The head and neck surgeon decided to follow-up without additional adjuvant radiotherapy, because he was confident of complete removal of the tumor and the surgical margins were negative for residual tumor. There were no definite findings of recurrence until 18 months after surgery at follow-up ^{18}F -FDG PET/CT revealed faint FDG uptake at the anterior wall of the right maxillary sinus (Fig. 1J). He was given fractionated radiotherapy at a total dose of 40 Gy (500 cGy/fraction, 2 fractions/week for 4 weeks) directed at the anterior wall of his right maxillary sinus. Despite adjuvant radiotherapy, the recurrent disease progressed thereafter on periodic follow-up ^{18}F -FDG PET/CT (Fig. 1J). The patient refused further management at our hospital and was lost to follow-up.

DISCUSSION

Our case represents primary mucosal melanoma of the lacrimal sac with extension into the inferior meatus through the nasolacrimal duct.

Primary mucosal melanoma, a very rare neoplasm accounting for 0.8-1.3% of all melanoma, most commonly occurs in the head and neck, mainly in the sinonasal area (5). Primary mucosal melanomas of the lacrimal drainage apparatus are extremely rare, and the majority of them arise from the lacrimal sac (1-4). Given that melanocytes are not usually present in the lacrimal

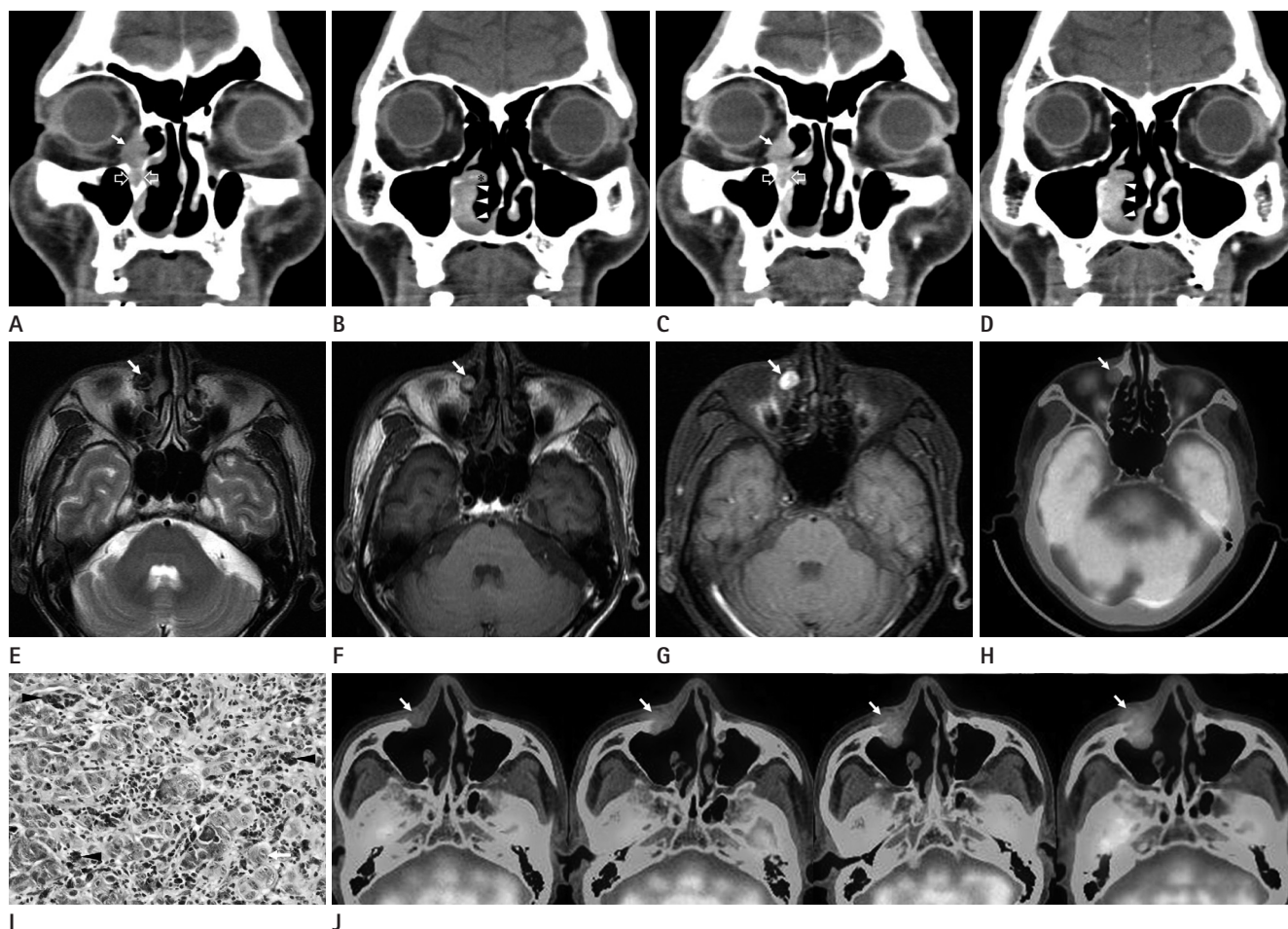


Fig. 1. CT, MRI, initial and follow-up ¹⁸F-fluorodeoxyglucose positron emission tomography/computed tomography (¹⁸F-FDG PET/CT), and pathologic features of primary mucosal melanoma of the lacrimal drainage apparatus in a 76-year-old man.

A, B. Coronal non-enhanced CT images show a soft tissue mass in the right lacrimal sac (arrow) extending to the right inferior meatus (arrowheads) through the nasolacrimal duct. Note widening and erosion of the walls of the nasolacrimal duct (open arrows), and upwardly displaced right inferior turbinate (asterisk) by the mass.

C, D. Coronal contrast-enhanced CT images reveal mild homogeneous enhancement of the mass in the lacrimal sac (arrow), nasolacrimal duct (open arrows), and inferior meatus (arrowheads).

E-G. Fast spin echo T2-weighted image (**E**) shows a heterogeneous hypointense (compared with gray matter) mass in the right lacrimal sac (arrow). Spin echo (SE) T1-weighted image (T1WI) (**F**) reveals a hyperintense (compared with gray matter) mass in the right lacrimal sac (arrow). Gadolinium-enhanced SE T1WI (**G**) demonstrates homogeneous intense enhancement of the mass in the right lacrimal sac (arrow).

H. ¹⁸F-FDG PET/CT reveals mild fluorodeoxyglucose (FDG) uptake (maximum standardized uptake value = 3.2 g/mL) of the mass in the right lacrimal sac (arrow).

I. Histological examination of the specimen obtained by en bloc resection demonstrates that the tumor is composed of large polygonal cells with prominent nucleoli (arrow) and brownish melanin pigments (arrowheads) (H&E stain, × 400).

J. Follow-up ¹⁸F-FDG PET/CT obtained 6 months after en bloc resection shows no abnormal FDG uptake (first image). Periodic follow-up ¹⁸F-FDG PET/CT obtained 18 (second image), 22 (third image), and 26 months (fourth image) after surgery demonstrate progressive enlargement and increment of FDG uptake of the recurrent mass (arrow) at the anterior wall of the right maxillary sinus.

sac, it has been hypothesized that primary mucosal melanoma of the lacrimal sac originates from the melanotic cells that may be inadvertently laid down beneath the lacrimal sac mucosa during embryogenesis or that may migrate into the lacrimal sac from adjacent conjunctiva (6, 7).

Early diagnosis of primary mucosal melanoma of the lacrimal

drainage apparatus would yield the greatest chance of survival. However, it is not easy to distinguish primary mucosal melanoma of the lacrimal drainage apparatus from more common chronic dacryocystitis clinically. As such, imaging is important not only for the diagnosis but for the evaluation of the extent of primary mucosal melanoma of the lacrimal drainage apparatus. The Pu-

jari et al. (1) reported a case of primary mucosal melanoma of the lacrimal sac, which was seen as a fairly well-defined, isoattenuating mass with invasion of the adjacent bone on CT. Sitole et al. (2) described CT features of a case of lacrimal sac melanoma, which was seen as a nonenhancing soft tissue mass of the left lacrimal sac with widening and erosion of the nasolacrimal duct. In contrast, Nam et al. (3) noticed that intense enhancement of the primary mucosal melanoma of the lacrimal sac on CT. In our case, solidly enhancing primary mucosal melanoma of the lacrimal drainage apparatus and bony changes of the nasolacrimal duct and inferior turbinate were well demonstrated on CT.

The differential diagnoses of a solidly enhancing mass involving the lacrimal drainage apparatus on CT include epithelial tumors comprising squamous cell carcinoma, transitional cell carcinoma, and minor salivary gland tumors (mucoepidermoid carcinoma and adenoid cystic carcinoma), and nonepithelial tumors comprising mesenchymal tumors, lymphoma (diffuse large B-cell lymphoma and extranodal marginal zone B-cell lymphoma of mucosa-associated lymphoid tissue), and primary mucosal melanoma. The literature reports 300-500 cases of tumors involving the lacrimal drainage apparatus, most as isolated case studies, with rare series (8). Because of the rarity of the tumors involving the lacrimal drainage apparatus, the characteristic imaging features of individual tumors of the lacrimal drainage apparatus have not been fully discussed. Our literature review reveals that the bony destruction and invasion of adjacent structures tend to be frequent in the squamous and transitional cell carcinomas, the two most common tumors involving the lacrimal drainage apparatus. In our case, the primary mucosal melanoma involving the lacrimal drainage apparatus was seen as a well-demarcated, solidly enhancing mass with bony remodeling, but without bony destruction or invasion of adjacent structures. The mass was homogeneously hyperattenuating, compared with brain parenchyma, and it showed homogeneous enhancement on contrast-enhanced CT. Accordingly, lymphoma, especially B-cell phenotype, and primary mucosal melanoma were the first diagnostic considerations. However, minor salivary gland tumors and papillomas could not be definitively excluded. We recommended MRI for the next step of evaluation.

Melanotic melanoma of the head and neck is expected to show high signal intensity (SI) on T1WI and low SI on T2WI owing to

the paramagnetic property of melanin pigment, although hemorrhage and other substances may masquerade melanin, and amelanotic melanoma may not show such characteristic findings (9). In the one and only case report presenting MRI findings of malignant melanoma of the lacrimal sac, Billing et al. (4) noticed that the mass involving the lacrimal sac and nasolacrimal duct showed intermediate SI on both T1WI and T2WI, and was enhanced following intravenous administration of gadolinium. In our case of primary mucosal melanoma of the lacrimal drainage apparatus, MRI showed characteristic features of melanotic melanoma, in that the mass was hyperintense on T1WI and hypointense on T2WI, compared with gray matter, and intensely enhanced on Gd-enhanced T1WI, which thus helped us to predict a histological diagnosis.

¹⁸F-FDG PET/CT findings of primary mucosal melanoma of the lacrimal drainage apparatus have not been presented in the literature. Initial and periodic follow-up ¹⁸F-FDG PET/CT would enable initial staging and early detection of the locoregional recurrence and metastasis of the primary mucosal melanoma of the lacrimal drainage apparatus, as in other areas of the head and neck (10). In our case, the initial ¹⁸F-FDG PET/CT revealed a mass with mild FDG uptake. Recurrent disease occurring at the anterior wall of the right maxillary sinus was seen as a mass with mild FDG uptake on follow-up ¹⁸F-FDG PET/CT obtained 18 months after surgery, and progressive enlargement and increment of FDG uptake of the recurrent disease thereafter were excellently demonstrated on periodic follow-up ¹⁸F-FDG PET/CT.

In summary, imaging is crucial for early diagnosis of primary mucosal melanoma of the lacrimal drainage apparatus, and thus it improves the chance of patient survival. CT seems to be valuable for early detection of the mass and associated bony changes of the lacrimal drainage apparatus; MRI, for lesion characterization; and initial and follow-up ¹⁸F-FDG PET/CT, for initial staging and surveillance of recurrent and metastatic diseases following surgery, respectively.

REFERENCES

1. Pujari A, Ali MJ, Mulay K, Naik MN, Honavar SG. The black lacrimal sac: a clinicopathological correlation of a malignant melanoma with anterior lacrimal crest infiltration. *Int Ophthalmol* 2013 [Epub ahead of print]

2. Sitole S, Zender CA, Ahmad AZ, Hammadeh R, Petruzzelli GJ. Lacrimal sac melanoma. *Ophthal Plast Reconstr Surg* 2007;23:417-419
3. Nam JH, Kim SM, Choi JH, Lee YK, Baek JH, Jang TJ, et al. Primary malignant melanoma of the lacrimal sac: a case report. *Korean J Intern Med* 2006;21:248-251
4. Billing K, Malhotra R, Selva D, Saloniklis S, Taylor J, Krishnan S. Magnetic resonance imaging findings in malignant melanoma of the lacrimal sac. *Br J Ophthalmol* 2003;87:1187-1188
5. Chang AE, Karnell LH, Menck HR. The National Cancer Data Base report on cutaneous and noncutaneous melanoma: a summary of 84,836 cases from the past decade. The American College of Surgeons Commission on Cancer and the American Cancer Society. *Cancer* 1998;83:1664-1678
6. Lloyd WC 3rd, Leone CR Jr. Malignant melanoma of the lacrimal sac. *Arch Ophthalmol* 1984;102:104-107
7. Levine MR, Dinar Y, Davies R. Malignant melanoma of the lacrimal sac. *Ophthalmic Surg Lasers* 1996;27:318-320
8. Montalban A, Liétin B, Louvrier C, Russier M, Kemeny JL, Mom T, et al. Malignant lacrimal sac tumors. *Eur Ann Otorhinolaryngol Head Neck Dis* 2010;127:165-172
9. Kim SS, Han MH, Kim JE, Lee CH, Chung HW, Lee JS, et al. Malignant melanoma of the sinonasal cavity: explanation of magnetic resonance signal intensities with histopathologic characteristics. *Am J Otolaryngol* 2000;21:366-378
10. Haerle SK, Soyka MB, Fischer DR, Murer K, Strobel K, Huber GF, et al. The value of 18F-FDG-PET/CT imaging for sinonasal malignant melanoma. *Eur Arch Otorhinolaryngol* 2012;269:127-133

누액배출기관을 침범한 원발성 점막형 흑색종의 전산화단층촬영, 자기공명영상 및 ^{18}F -Fluorodeoxyglucose Positron Emission Tomography/CT Features 소견: 증례 보고¹

이상권¹ · 최미선²

저자들은 76세 남자 환자에서 발생한 누액배출기관의 원발성 점막형 흑색종의 CT, MRI, 초기 및 추적 ^{18}F -fluorodeoxyglucose positron emission tomography/computed tomography (이하 ^{18}F -FDG PET/CT) 소견을 보고하고자 한다. CT에서 병변은 누낭으로부터 비루관을 통하여 하비도까지 연장되어 있는 조영증강되는 종괴로 관찰되었으며, 대뇌 회질과 비교하여 T1- 및 T2-강조영상에서 각각 고신호 및 저신호 강도를 보였으며, 조영증강 후 T1-강조영상에서 강한 조영증강을 보였다. 초기 ^{18}F -FDG PET/CT에서 종괴는 경도의 fluorodeoxyglucose 섭취를 보였다. 외과적 생검에 의해 점막형 흑색종으로 진단되었다. 주기적인 추적 ^{18}F -FDG PET/CT에서 술 후 18개월에 재발된 병변이 발견되었고, 그 후 재발 병변의 진행이 관찰되었다. CT, MRI, 초기 및 추적 ^{18}F -FDG PET/CT는 각각 누액배출기관의 원발성 점막형 흑색종의 병변 및 동반된 골 변화의 발견, 병변의 특성화, 초기 병기결정 및 재발과 전이의 감시에 있어서 유용하리라 생각된다.

계명대학교 의과대학 ¹영상의학교실, ²병리학교실